

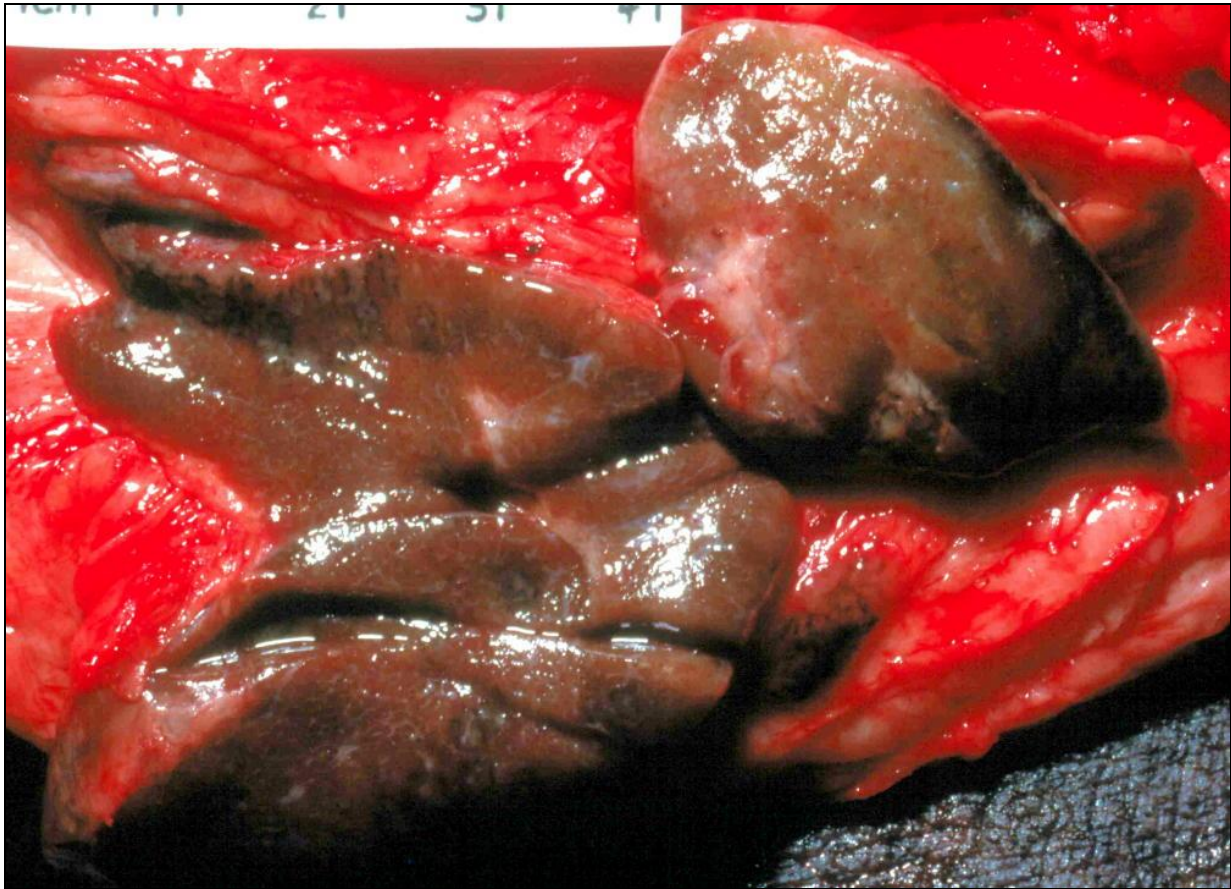
ASVP DIAGNOSTIC EXERCISE NO. 18

Roger Kelly

History:

Close-up view of a popliteal lymph node, exposed and sliced. From an old dog from the local pound (no history was available). The animal was killed for a student necropsy class. .

The skin of the rump and hind legs was diffusely wrinkled, hyper-pigmented and symmetrically alopecic (a typical example is visible at lower right).



(this page can be enlarged to 200% for closer views of this specimen)

1. Describe the abnormalities
2. What basic disease processes might be present?
3. Pathological diagnosis (give other possibilities in order of preference)?
4. What is the most likely cause of this change?

As with previous exercises, I will send out a description and discussion of this case in a couple of weeks, and it will eventually be archived on the members login pages of the ASVP website <http://www.asvp.asn.au/>

Please advise me roger-kelly@aapt.net.au if you have any problem opening this case

If anyone wishes to provide a diagnostic case, please contact me and I will advise you about image requirements.