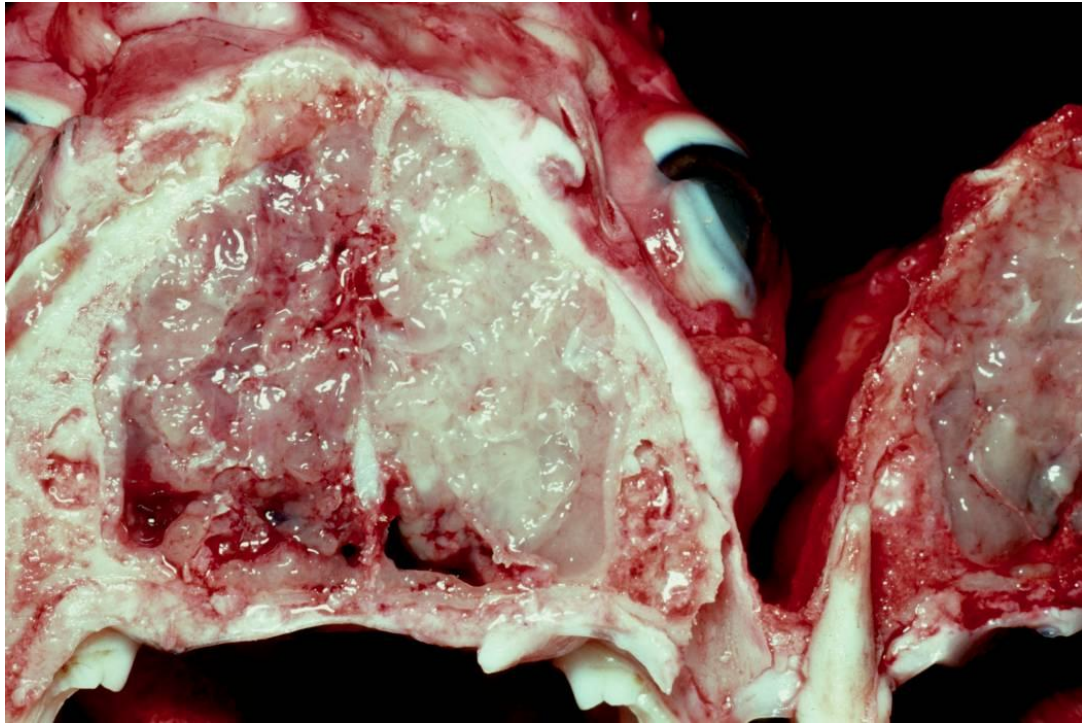


*Sent on Dec.5th. 2005*

**History:**

The image is a view of the necropsy dissection of a nine year-old dog which had shown progressive signs of nasal obstruction. Otherwise the animal was quite well. Turbinate loss was apparent on radiography.



1. Describe the abnormalities
2. What basic disease processes might be present?
3. Preferred pathological diagnosis (give other possibilities in order of preference)?
4. What shrewd and cost-effective procedure would you perform at this stage of the examination, to maximise your chances of a full diagnosis?

---

As with previous exercises, I will send out a description and discussion of this case in a couple of weeks, and it will eventually be archived on the website.

Please advise me [roger-kelly@aapt.net.au](mailto:roger-kelly@aapt.net.au) if you have any problem opening this case on your browser.

If anyone wishes to provide a diagnostic case, please contact me and I will give you some information about image requirements.

Good luck,

Roger Kelly