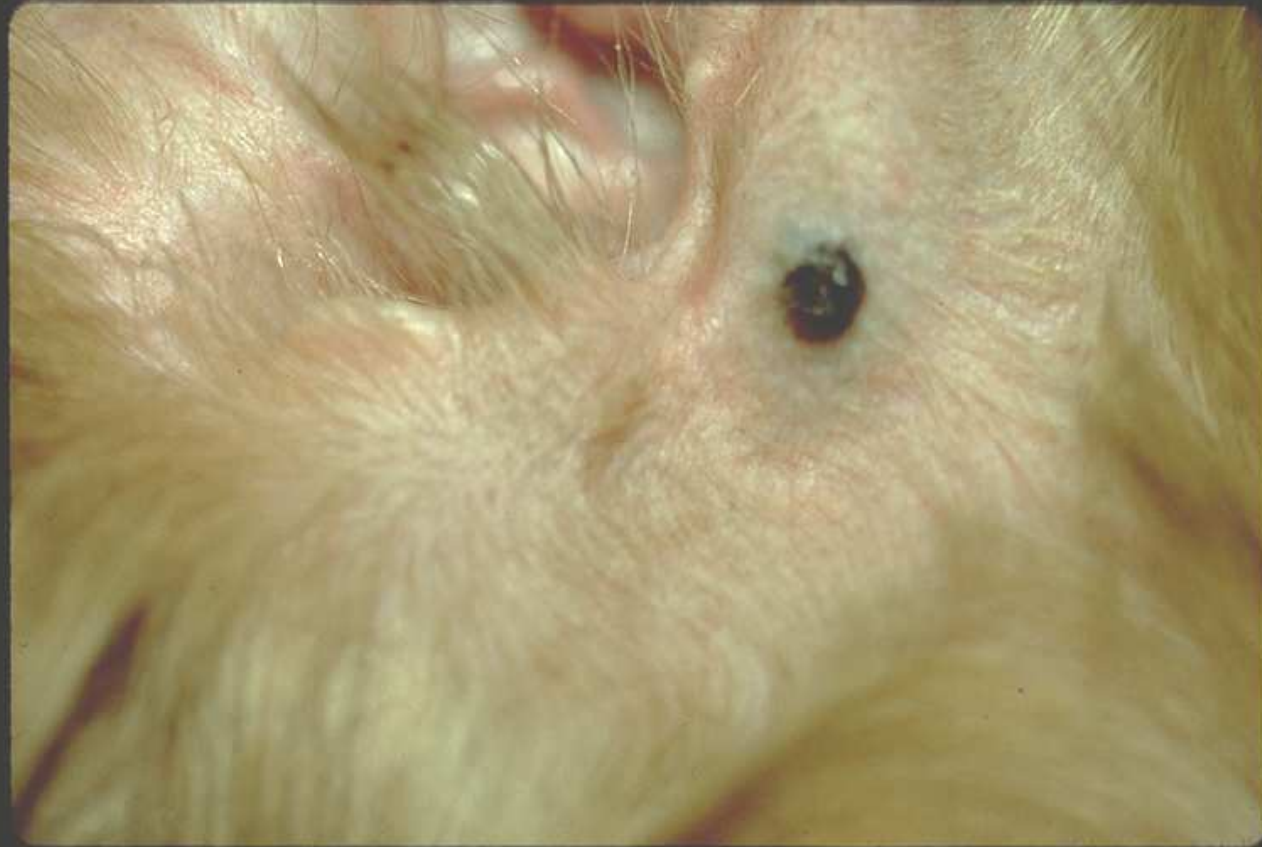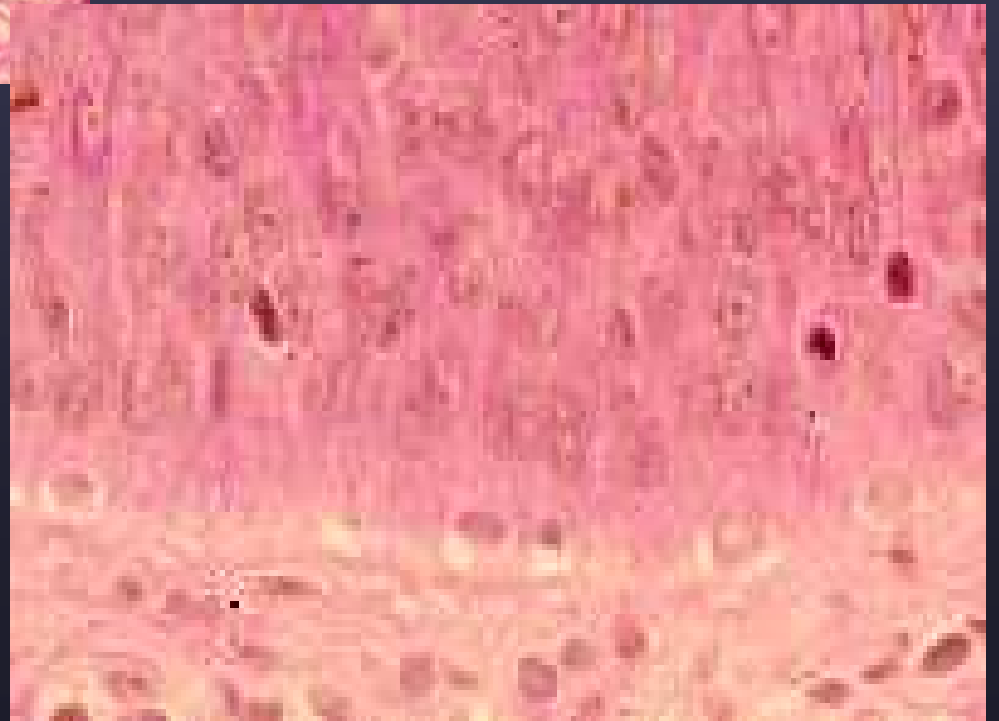
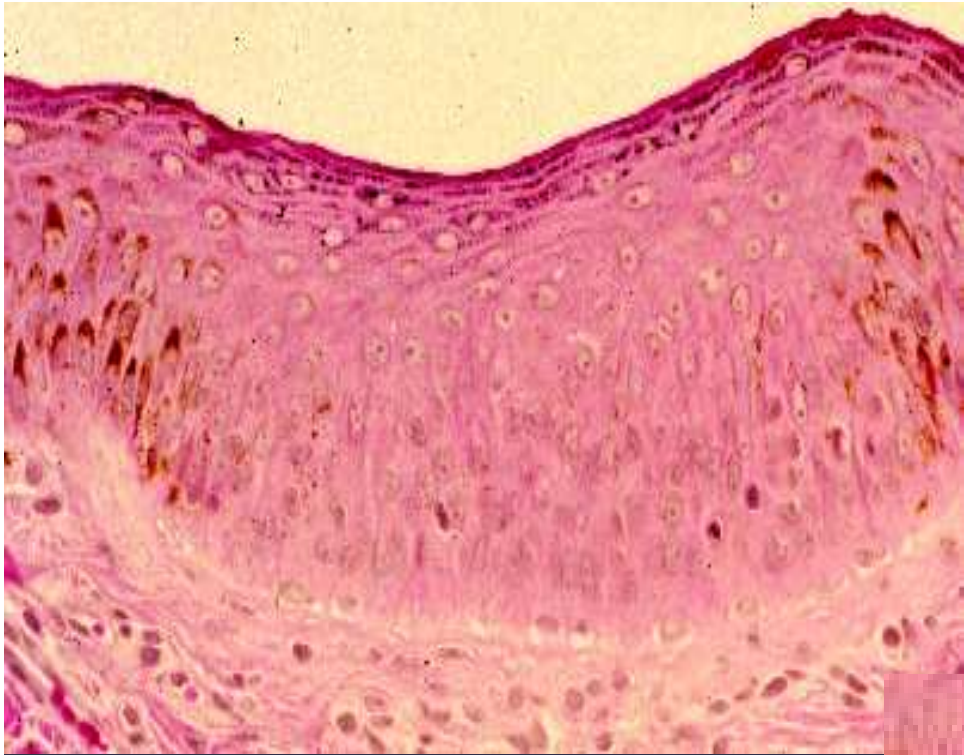




▶ Melanocytoma

Merkel Cells

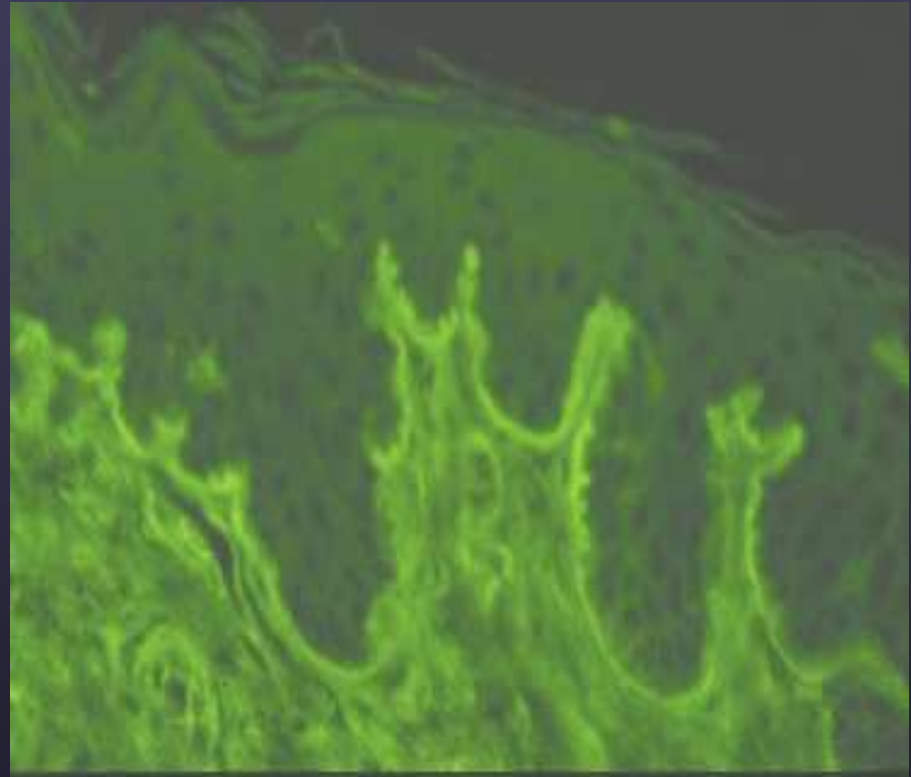
- Features of epithelial and neuroendocrine cells
- Mechanoreceptors in tylotrich pads and hair follicles



Merkel cells in tyotrich pad

Basement Membrane Zone

- anchors epidermis to dermis
- protective barrier
- wound healing
- site of many pathologic processes
- Example:
Epidermolysis bullosa

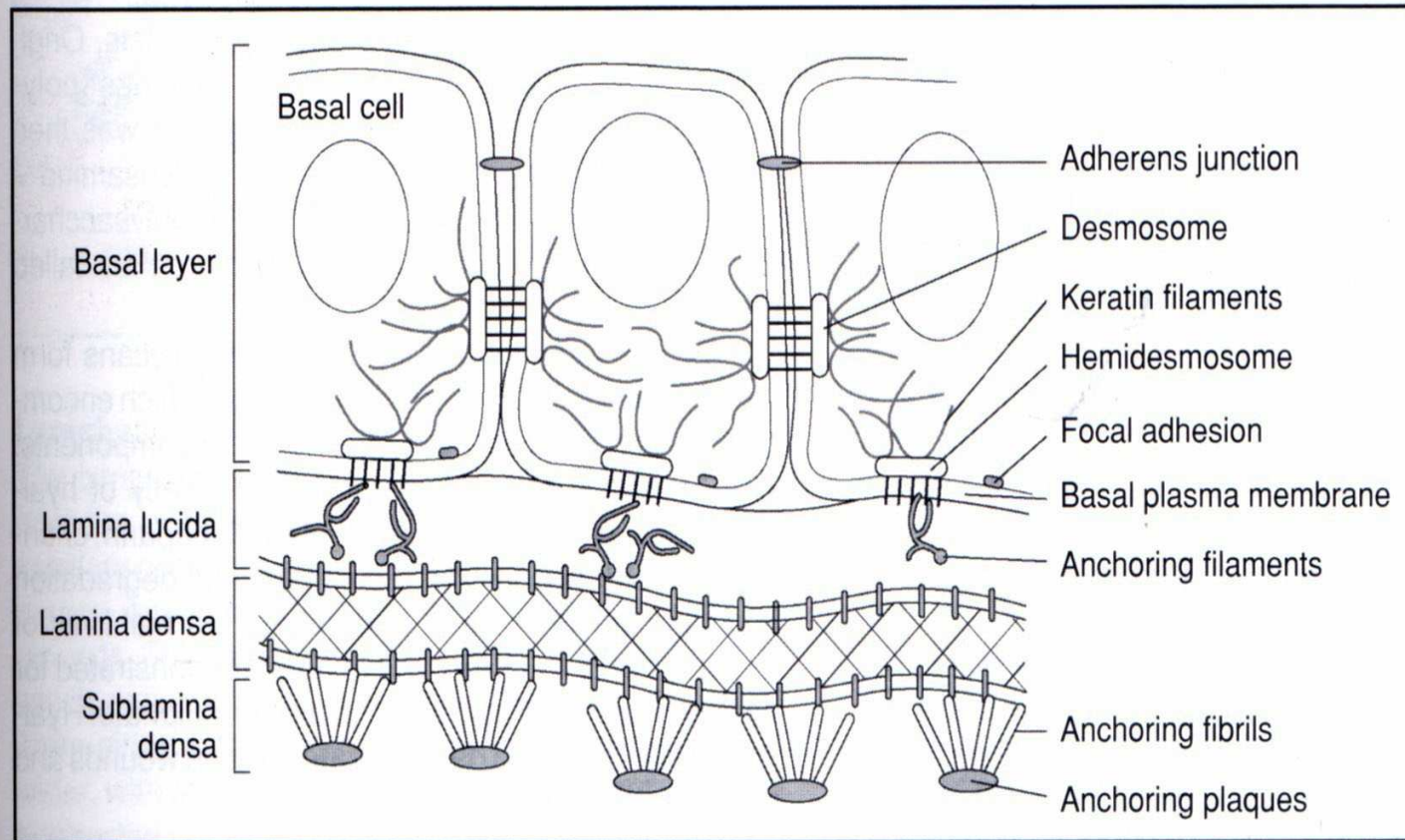


Nonspecific Ig staining of BMZ

Basement Membrane

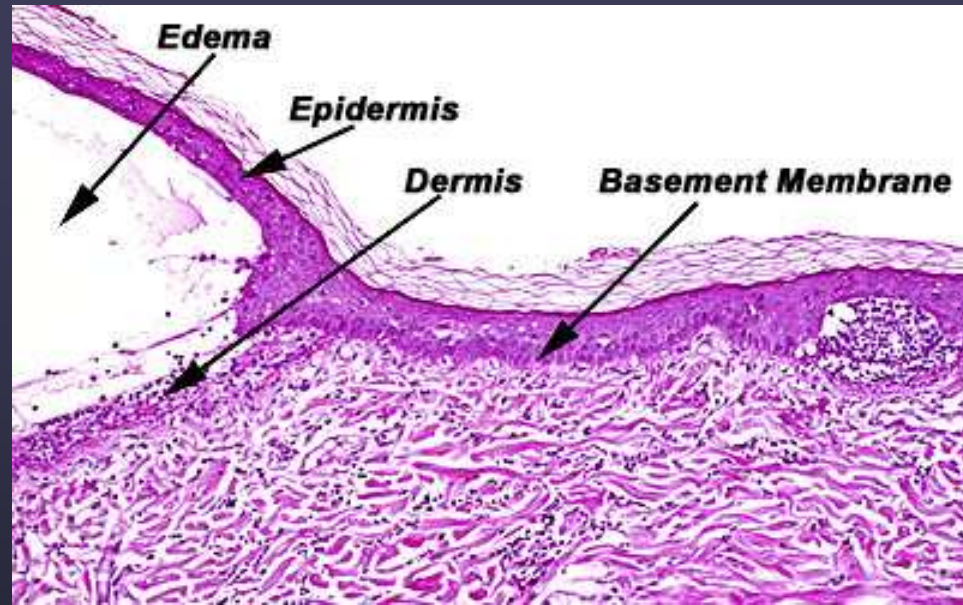
- **Hemidesmosomes** of basal cells
 - Inner and outer plaques
- **Lamina lucida**- clear zone seen on electron microscopy
- **Lamina densa**- contains primarily Type IV collagen
- **Sublamina densa**- anchoring fibrils- Type VII collagen

Basement Membrane Zone



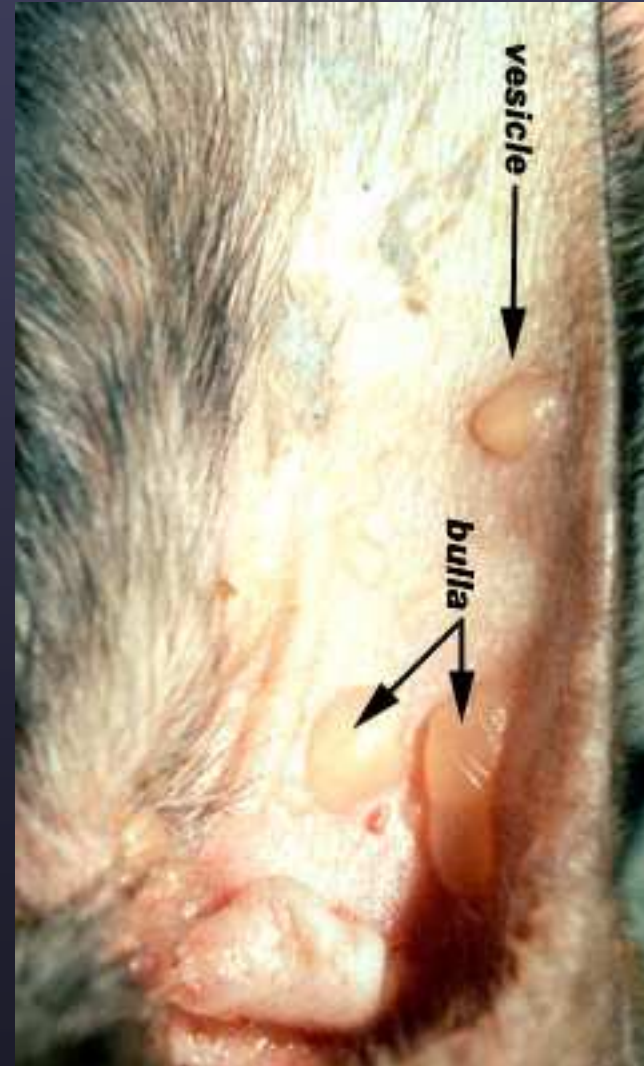
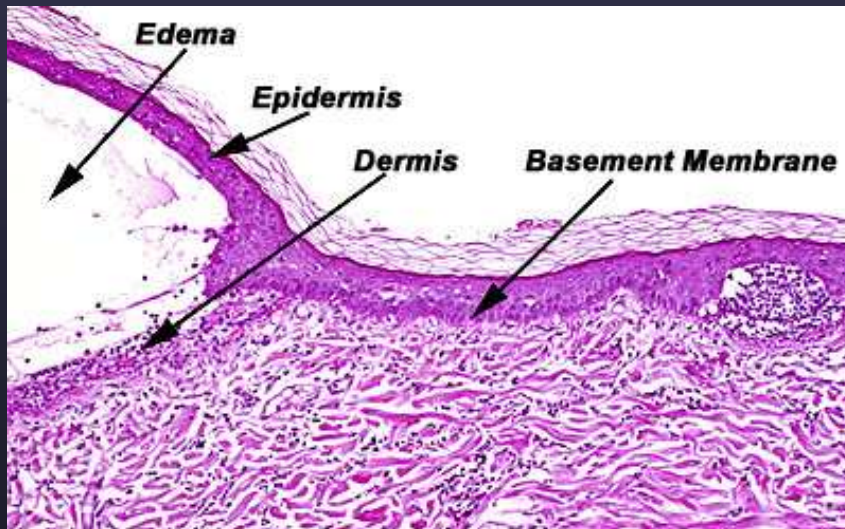
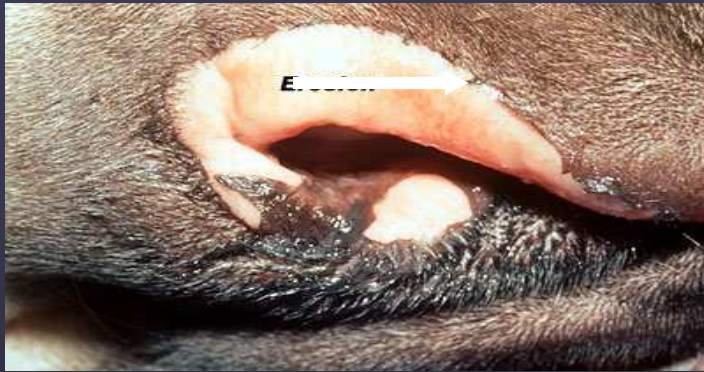1.13

Diagrammatic representation of structural components of the dermoepidermal junction.
© Anita Patel.

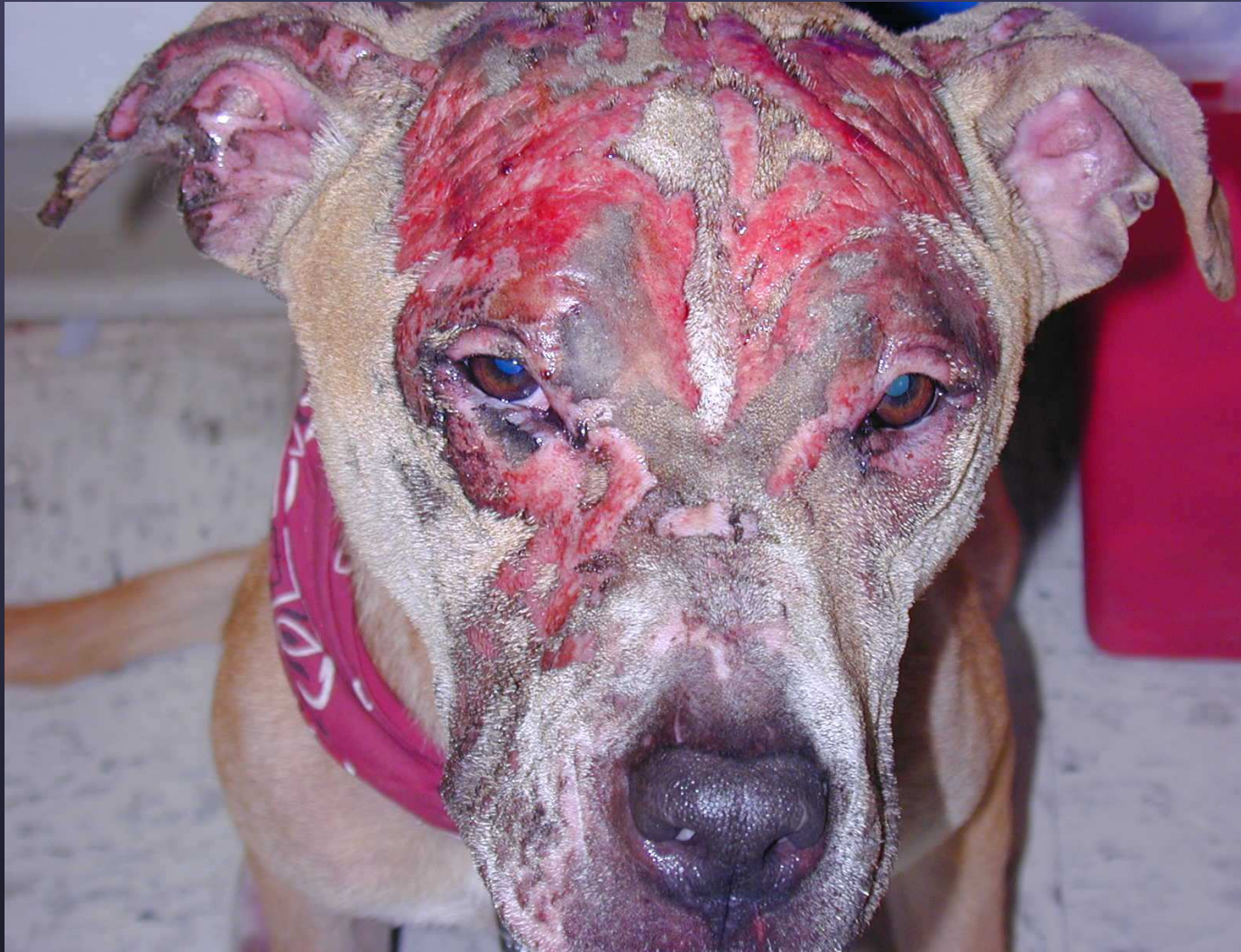

Ab to Collagen VII

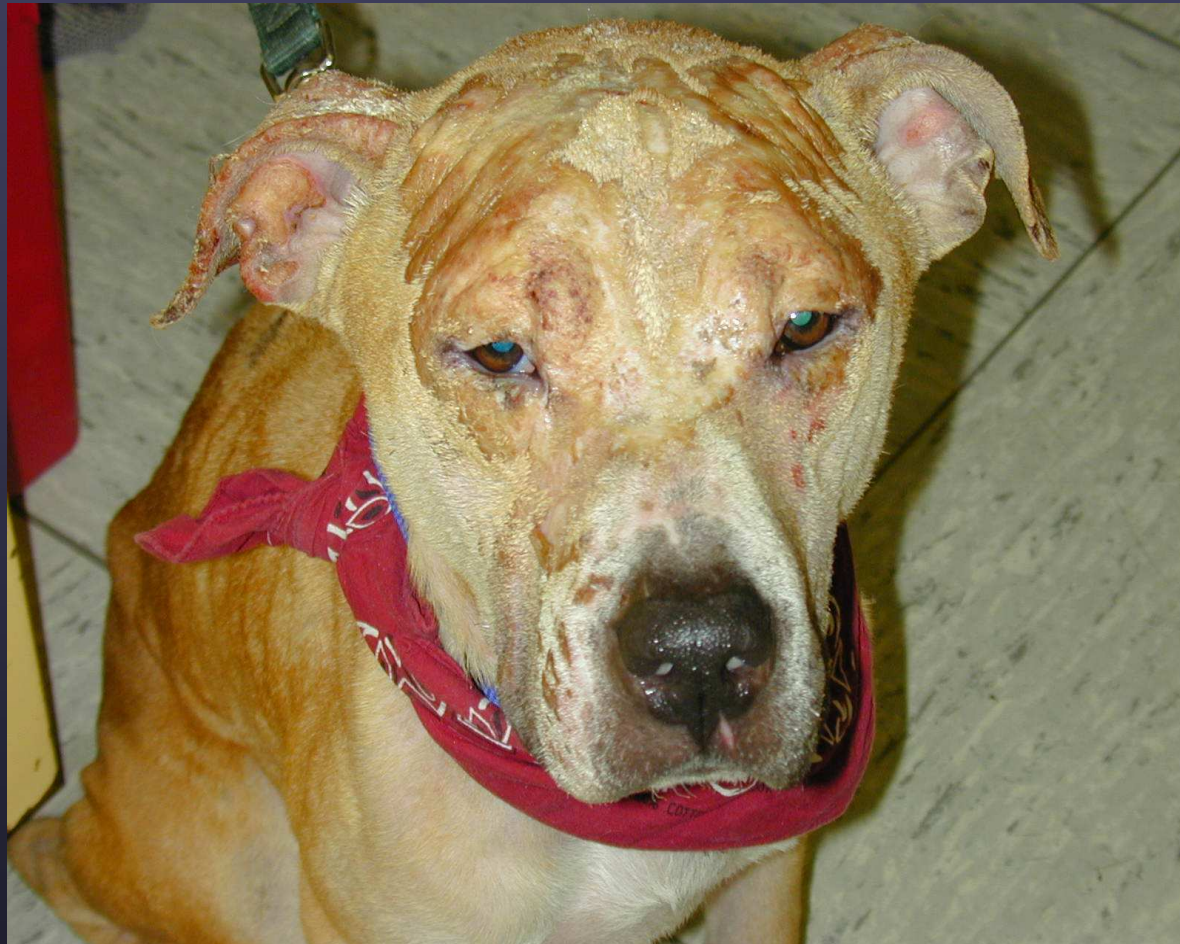Epidermolysis Bullosa Acquista



6 mo. old Great Dane



▶ Thermal burn



▶ Scarring alopecia