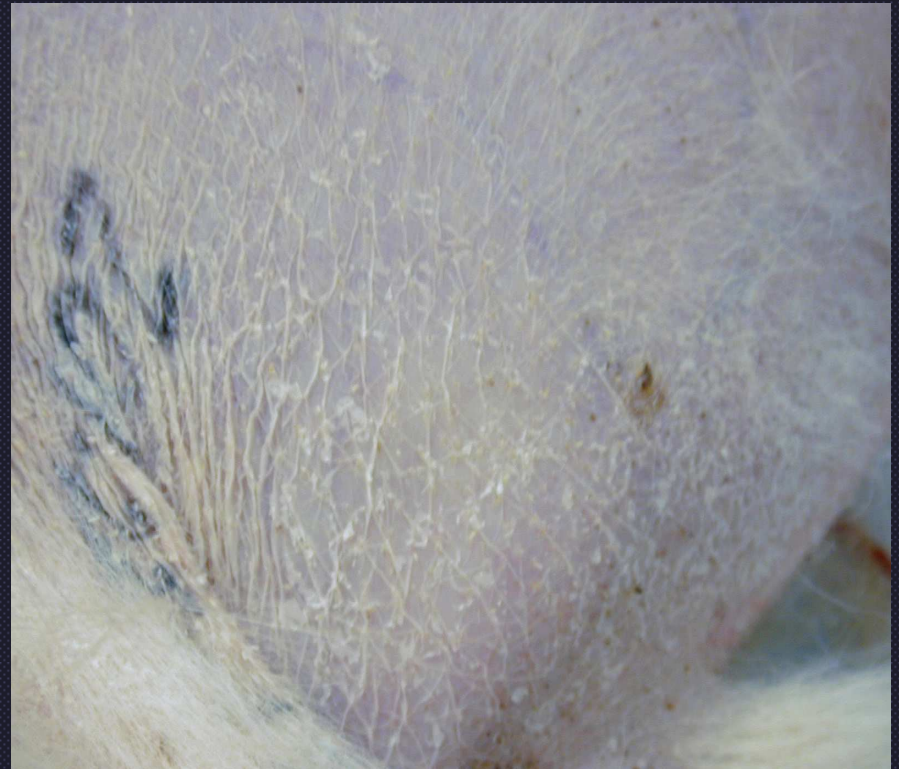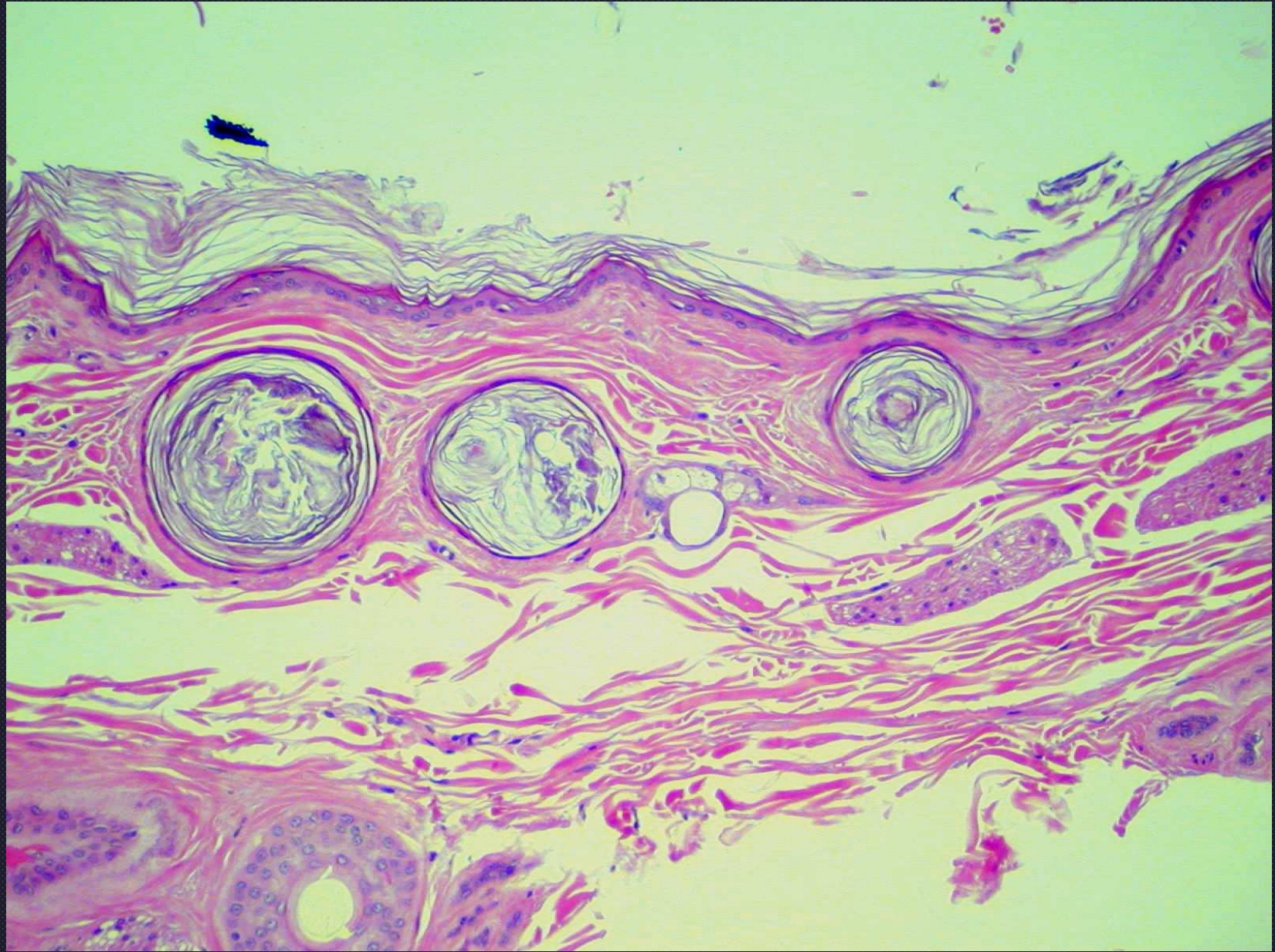


Endocrine Disease

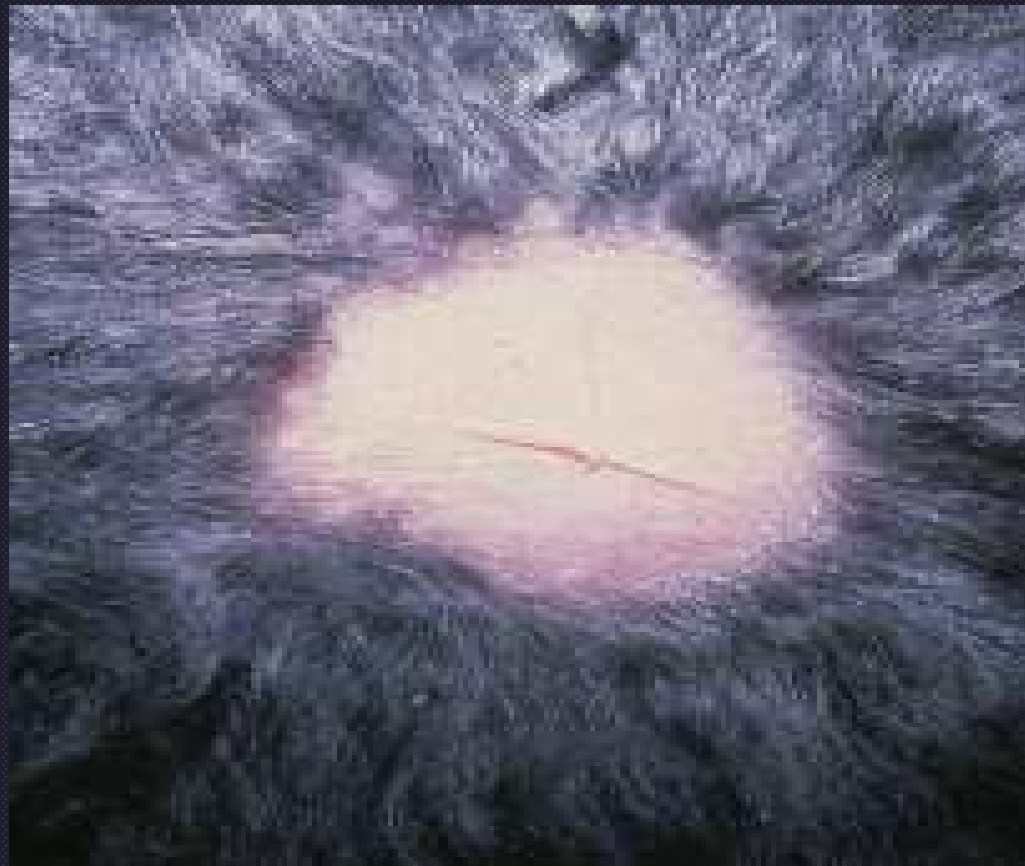- Hyperadrenocorticism
- Epidermal, dermal atrophy



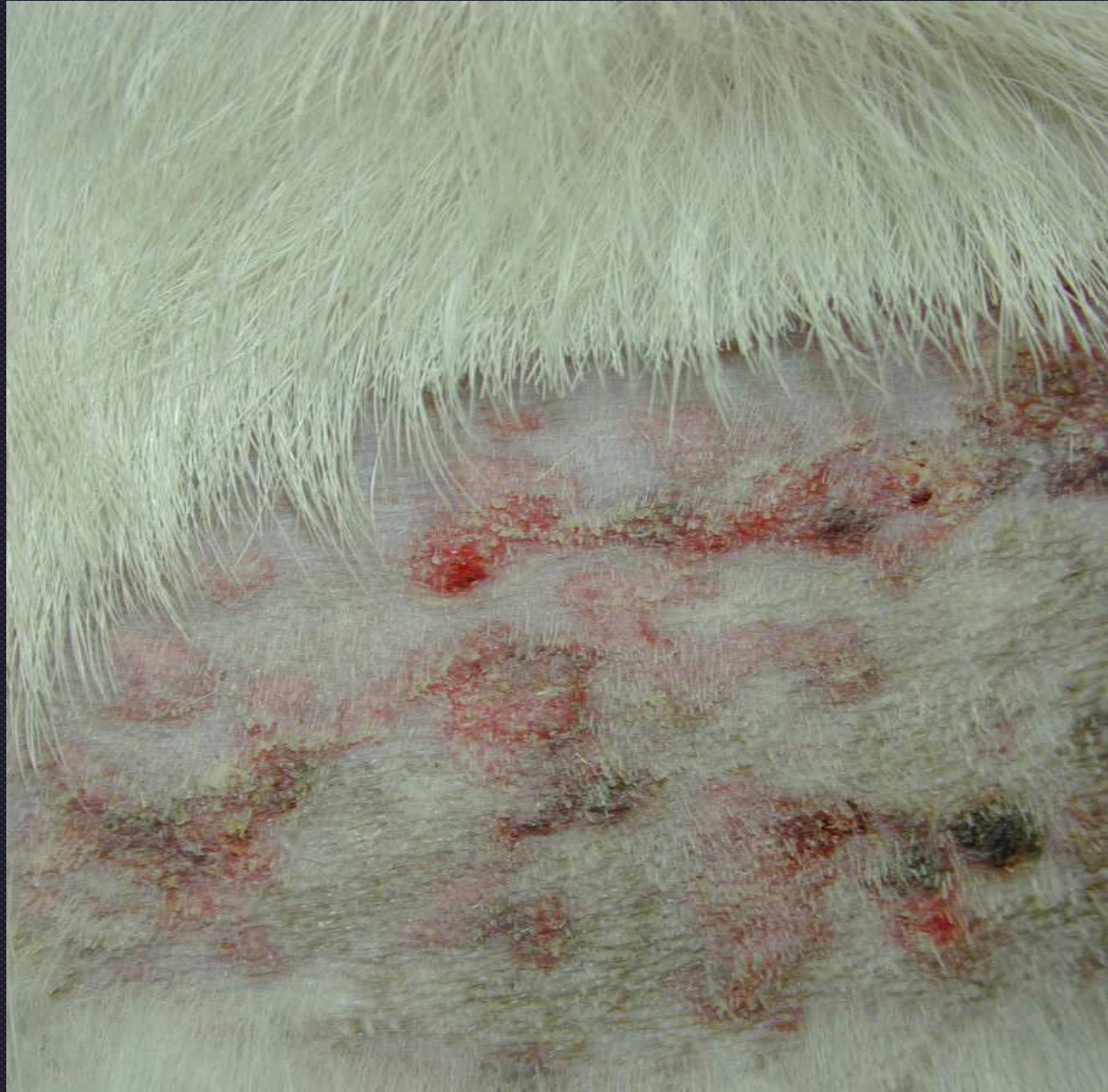

Cutaneous atrophy due to hyperadrenocorticism

Topical Corticosteroids

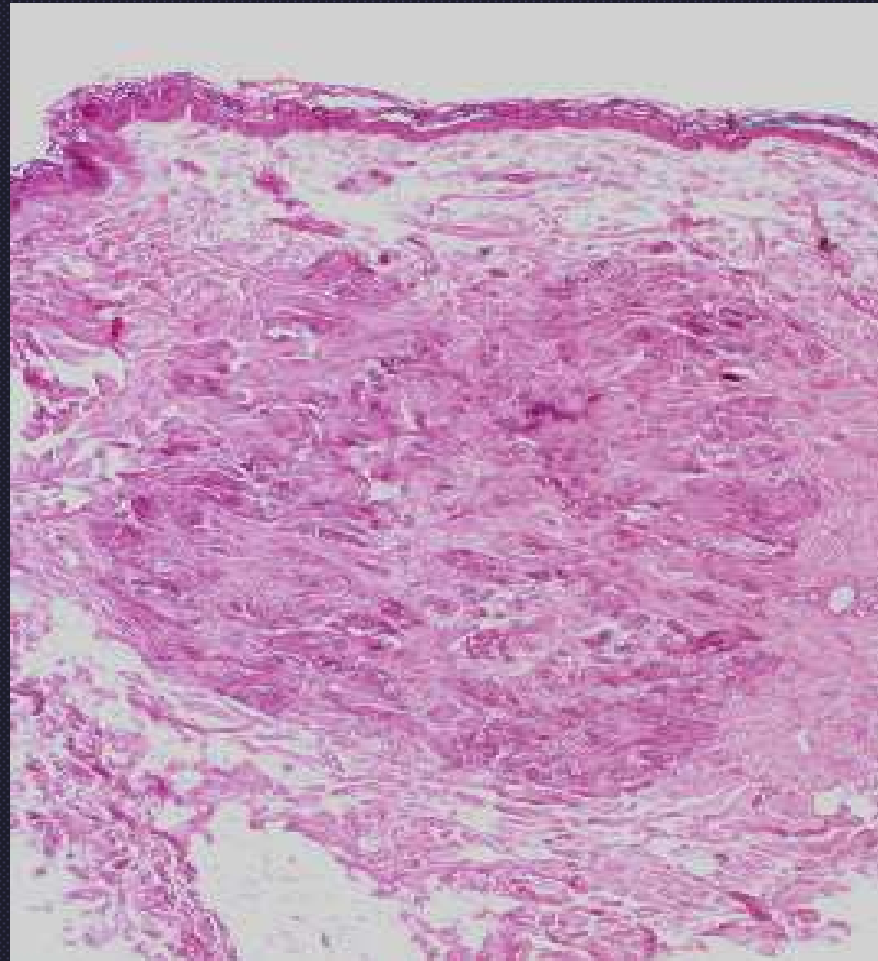


Cutaneous atrophy

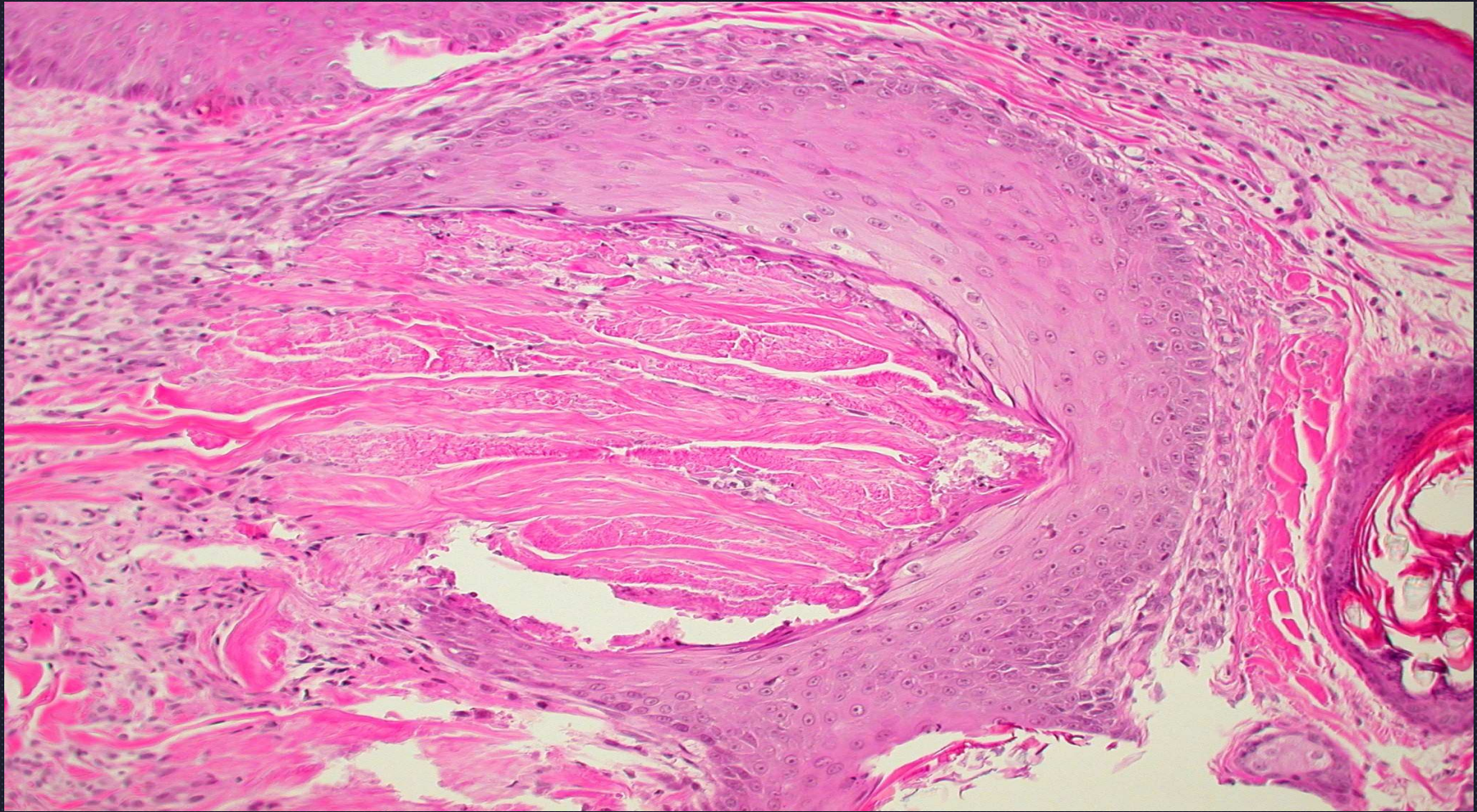


Calcinosis cutis

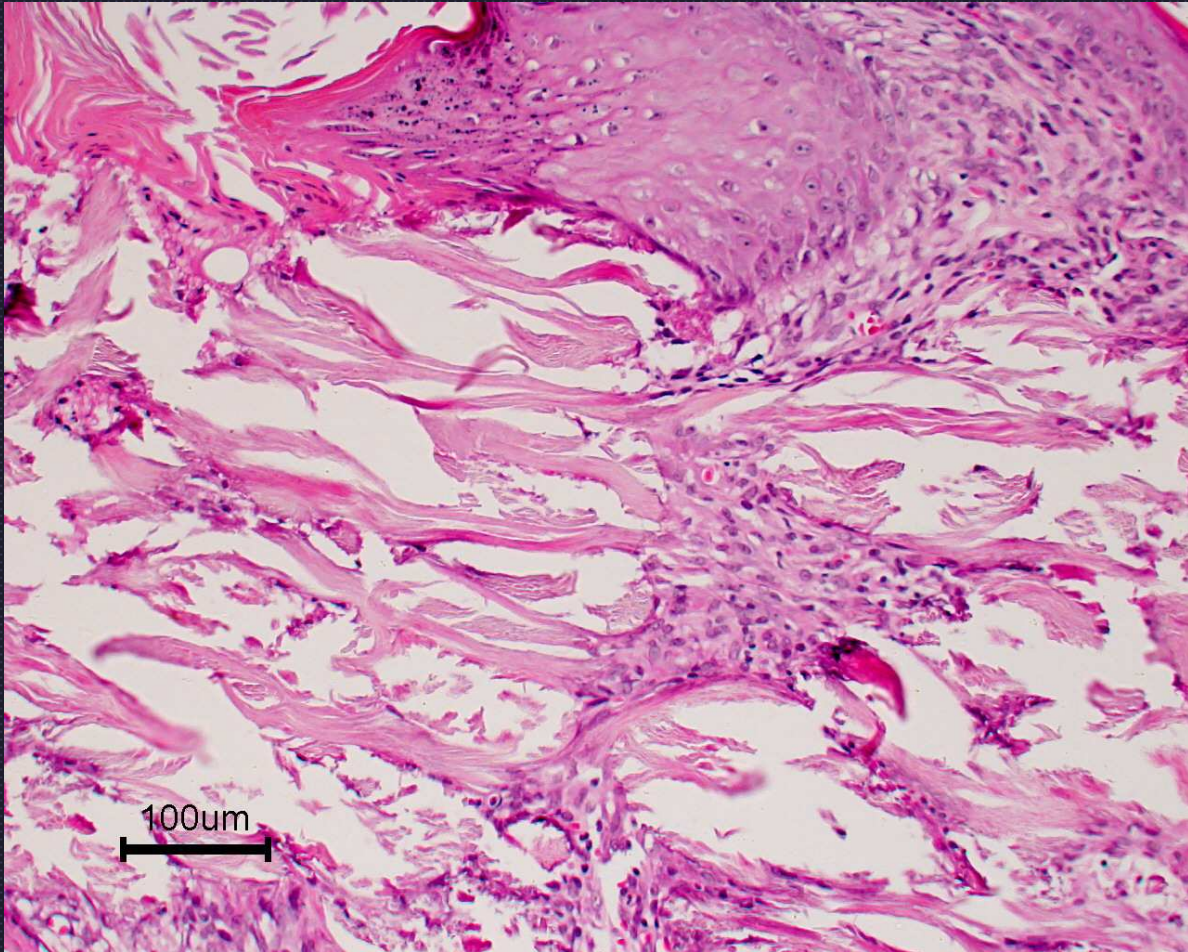
Calcinosis Cutis



Calcinosis Cutis



“follicular vomiting”



Calcinosis cutis