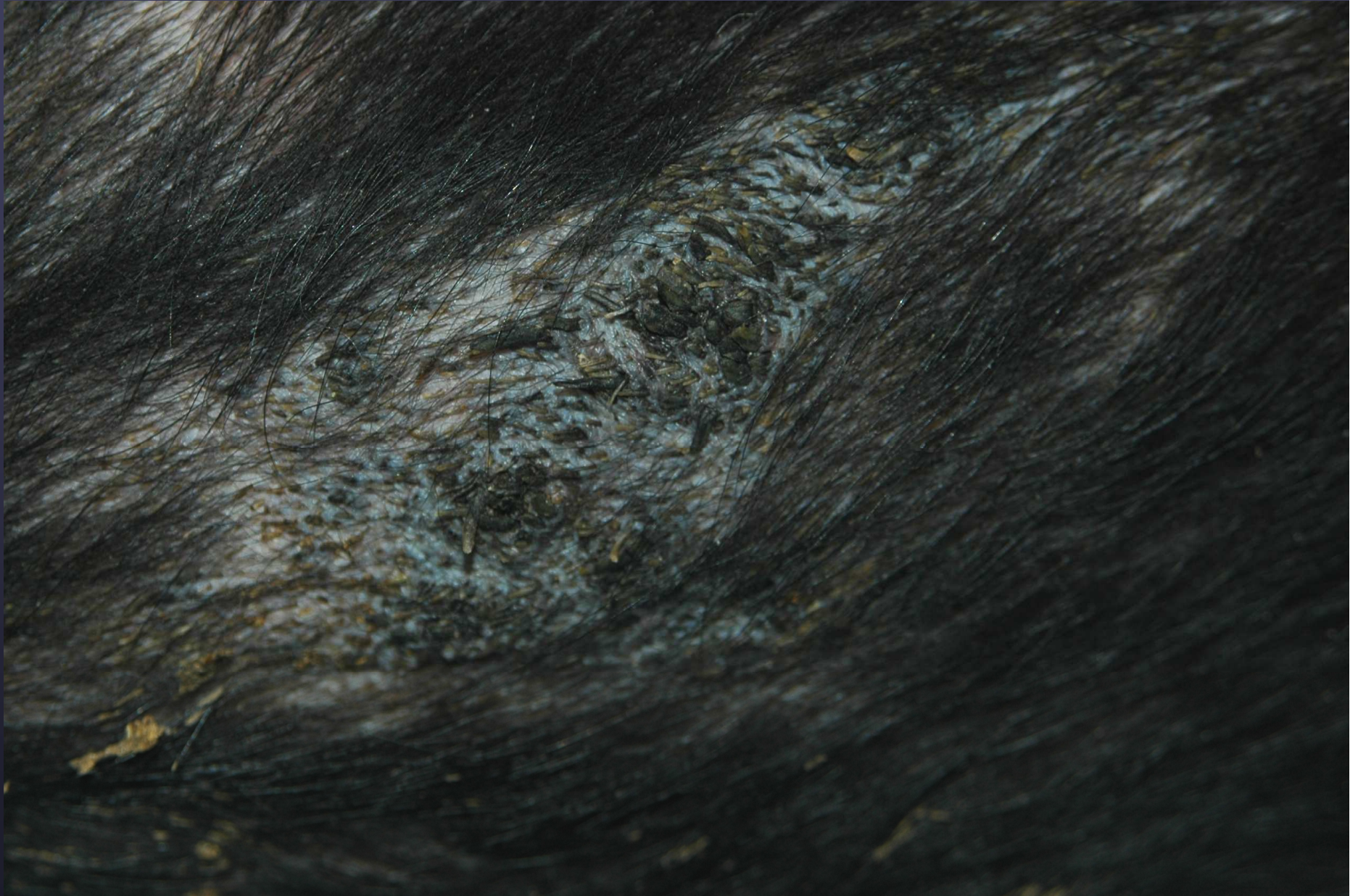



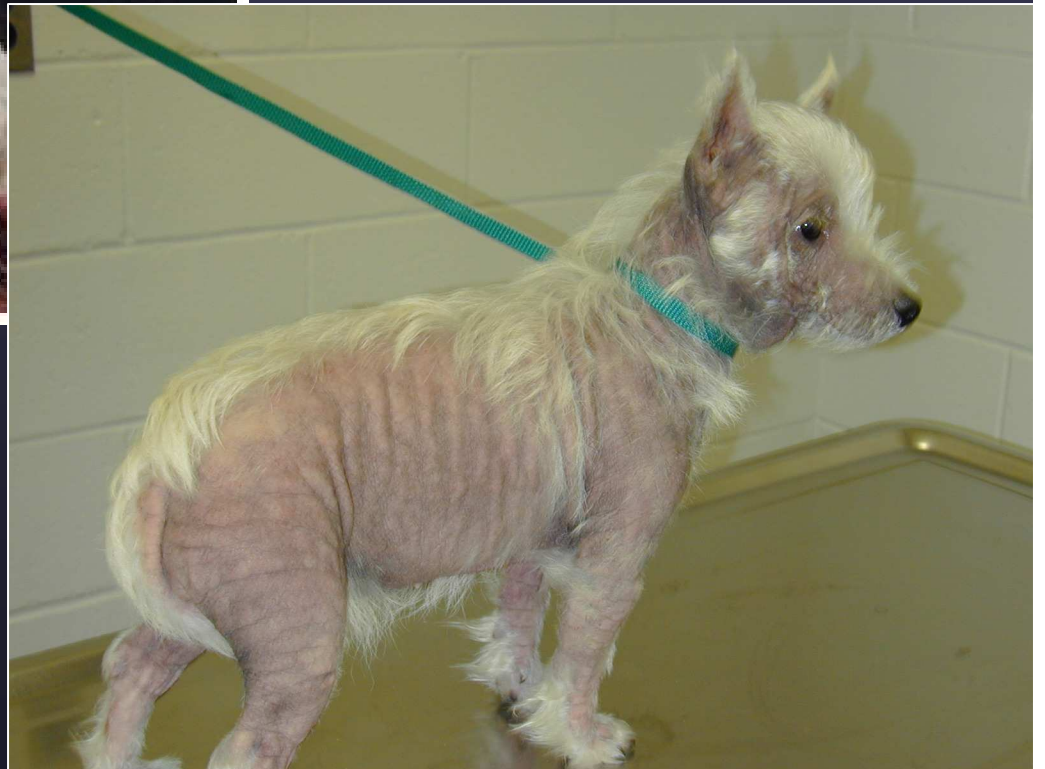► Congenital follicular parakeratosis

Outline- Day 1

- Basics of skin biology and cornification
- Teaching your clients to submit proper samples
- Practical dermatopathology
How to use pattern diagnosis correctly
- Interface disorders: Concepts and Controversies

Day 2

- Journey into the hair follicle and follicular diseases
- What's new in Equine Dermatopathology?
- Miscellaneous disorders
- Master class- “nuts and bolts” of daily dermpath in 1 ½ palates




Reasons for Vet Visit

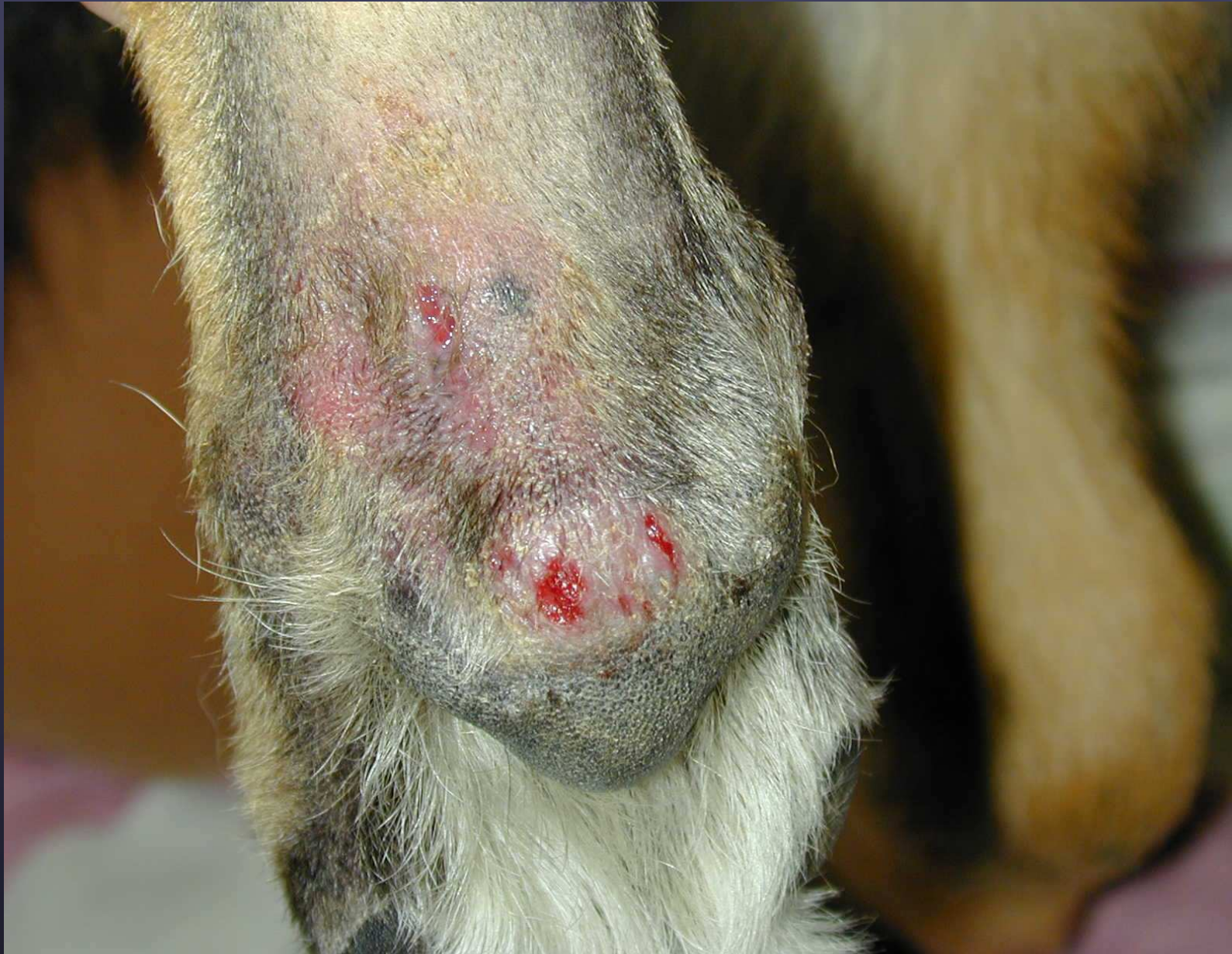1. **Ear Infection**
2. **Skin Allergy**
3. Stomach upset
4. **Benign tumors**
5. Bladder infection
6. **Skin infection**

▶ 2005, Veterinary Pet Insurance Co.

Difficulties in Dermopath

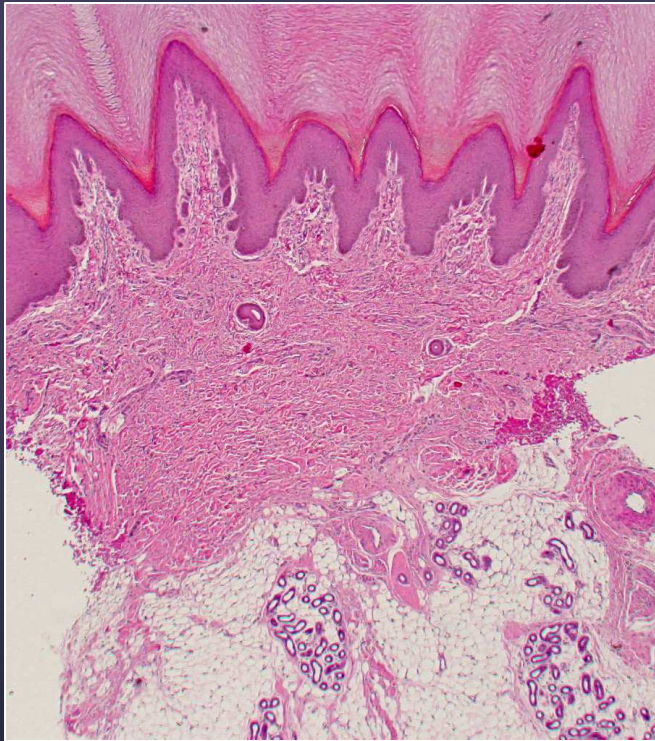
- *Many* veterinary dermatologic diseases/syndromes to know
- Few have been thoroughly investigated
- Skin biopsies are tedious
- Histopath + clinical presentation often *key* to correct diagnosis
- Pathologist must have good clinical background
- Pathologist relies on clinician to select appropriate sample



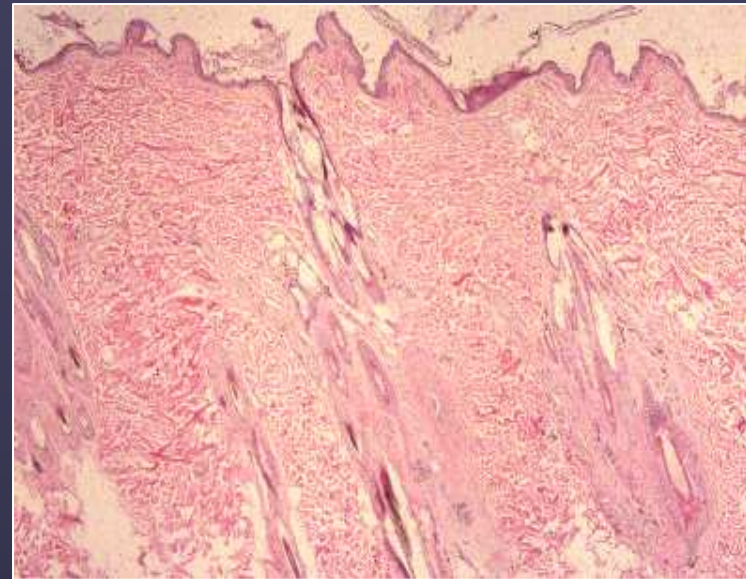


► Metatarsal fistulas of German shepherd dog

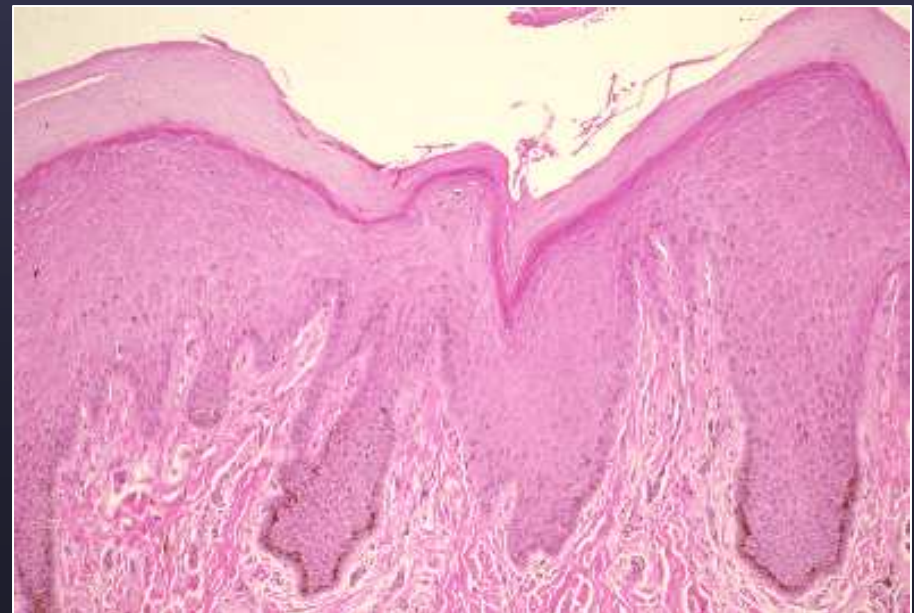
- Use the dermatology vocabulary
- Know the gross lesions associated with skin disorders
- Teaching dermatopathology to students
 - Stress Function
 - Consequences of Function Loss (Dysfunction)



► footpad

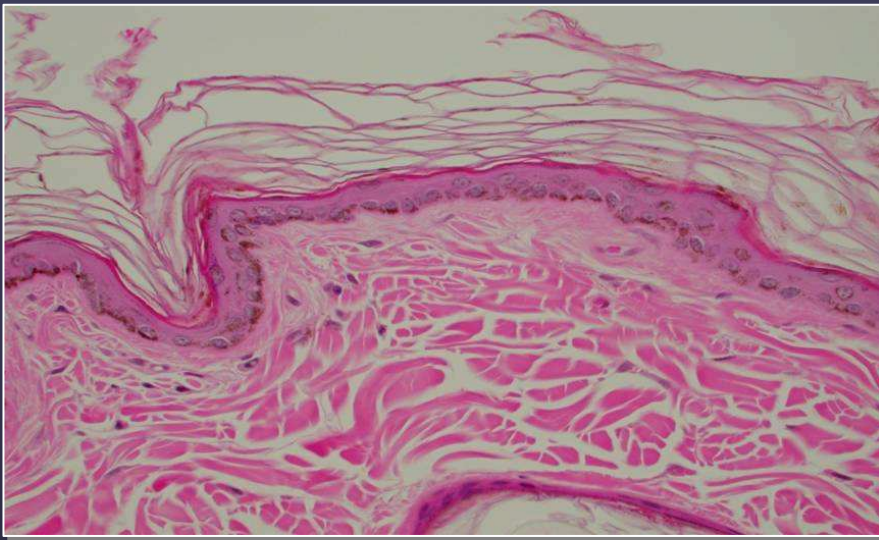


► flank

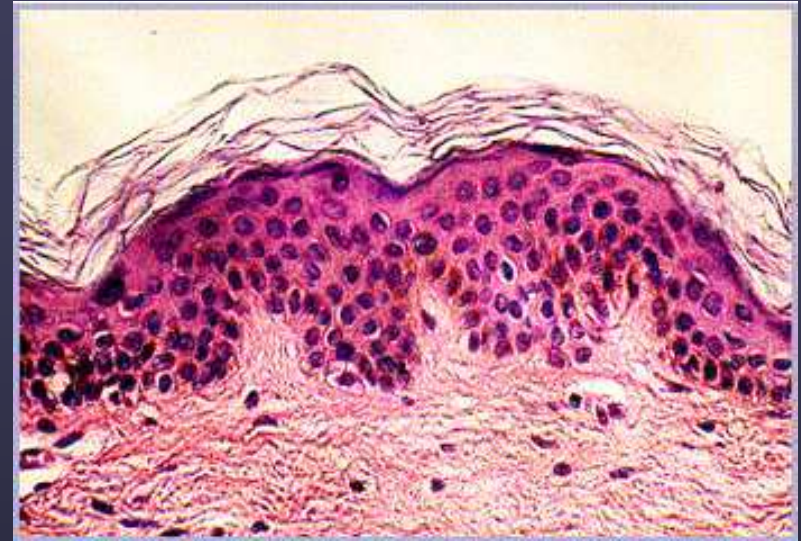

► nasal planum

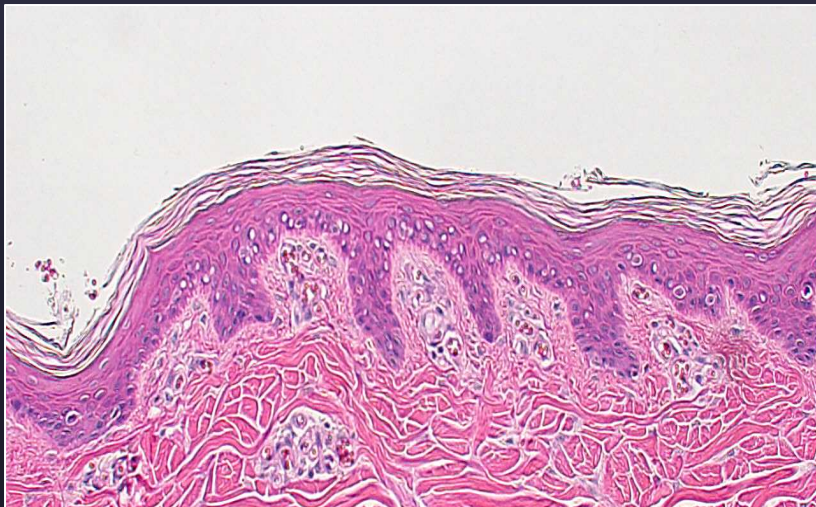
Species Differences



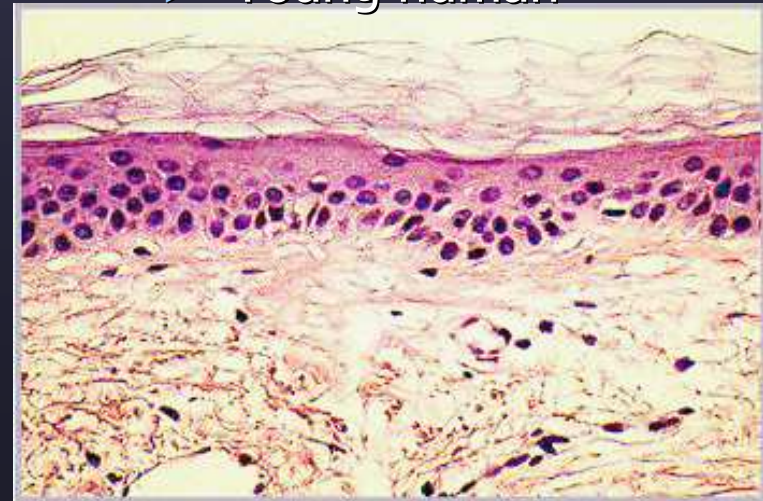
▶ Canine



▶ Young human



▶ Swine



▶ Aged human