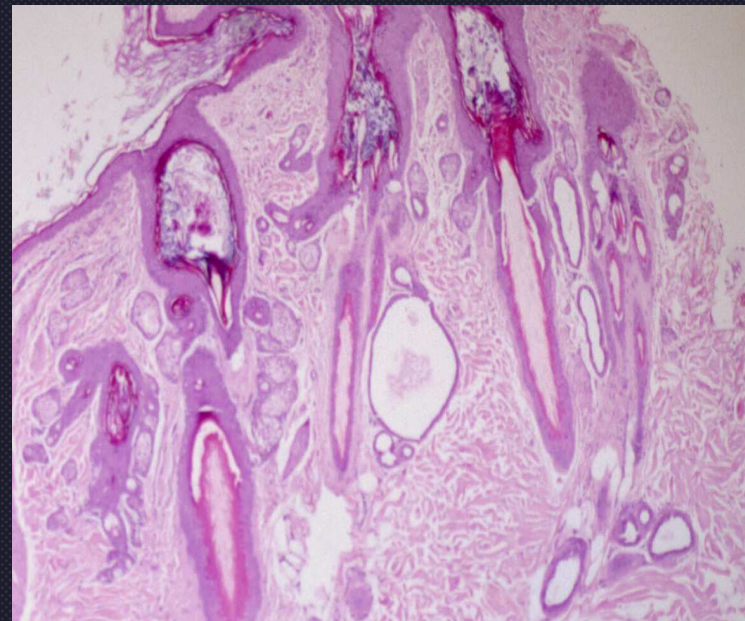
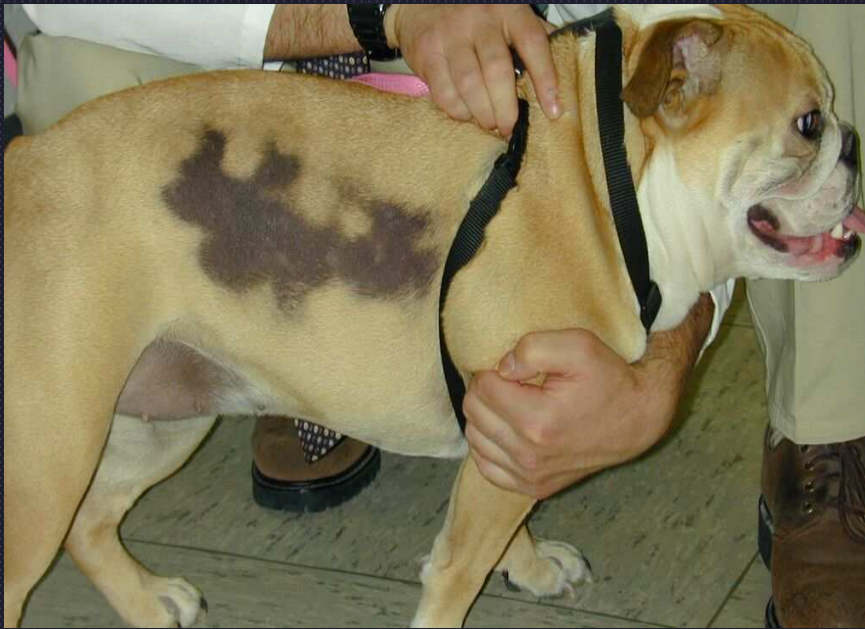

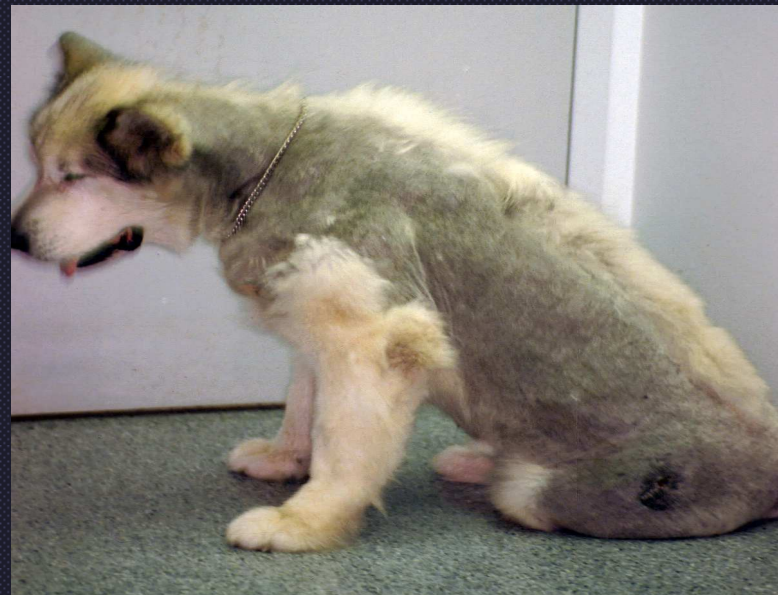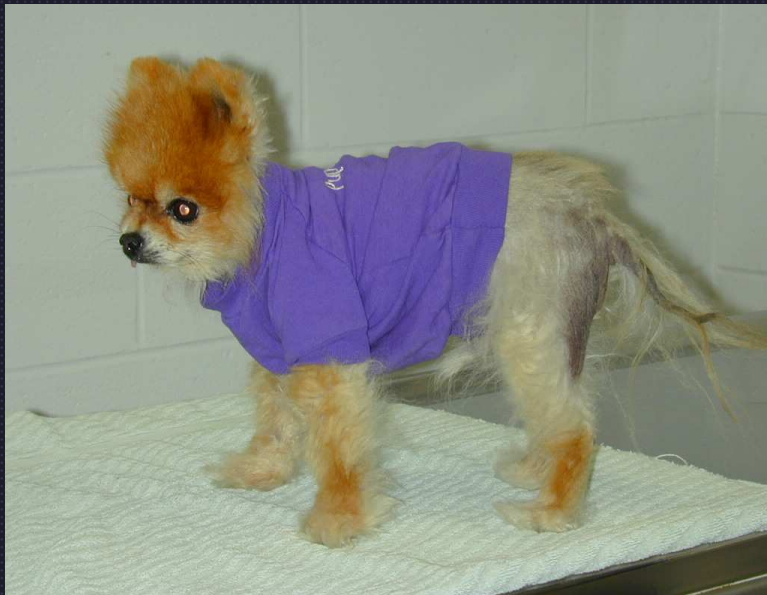Follicular Changes

- **Outer root sheath can undergo same changes as epidermis**
- **Folliculitis**
- **Follicular keratosis**
- **Follicular atrophy- different forms**
 - “faded follicles”
 - excessive trichilemmal keratinization
 - miniaturization
- **Follicular dysplasia- Color dilution alopecia**
- **Follicular neoplasia**

Cyclic Flank Alopecia




Follicular Atrophy

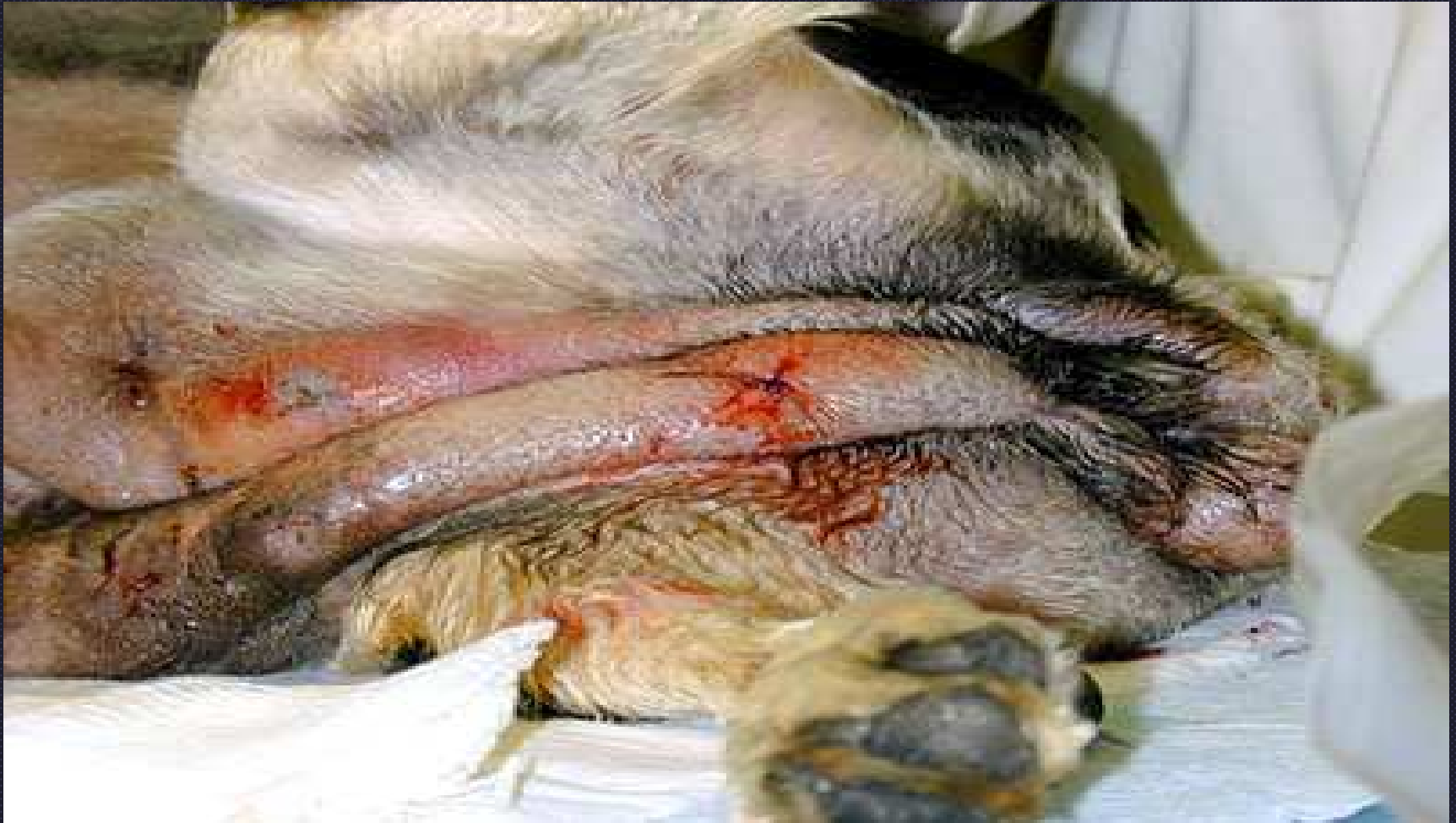

Alopecia X

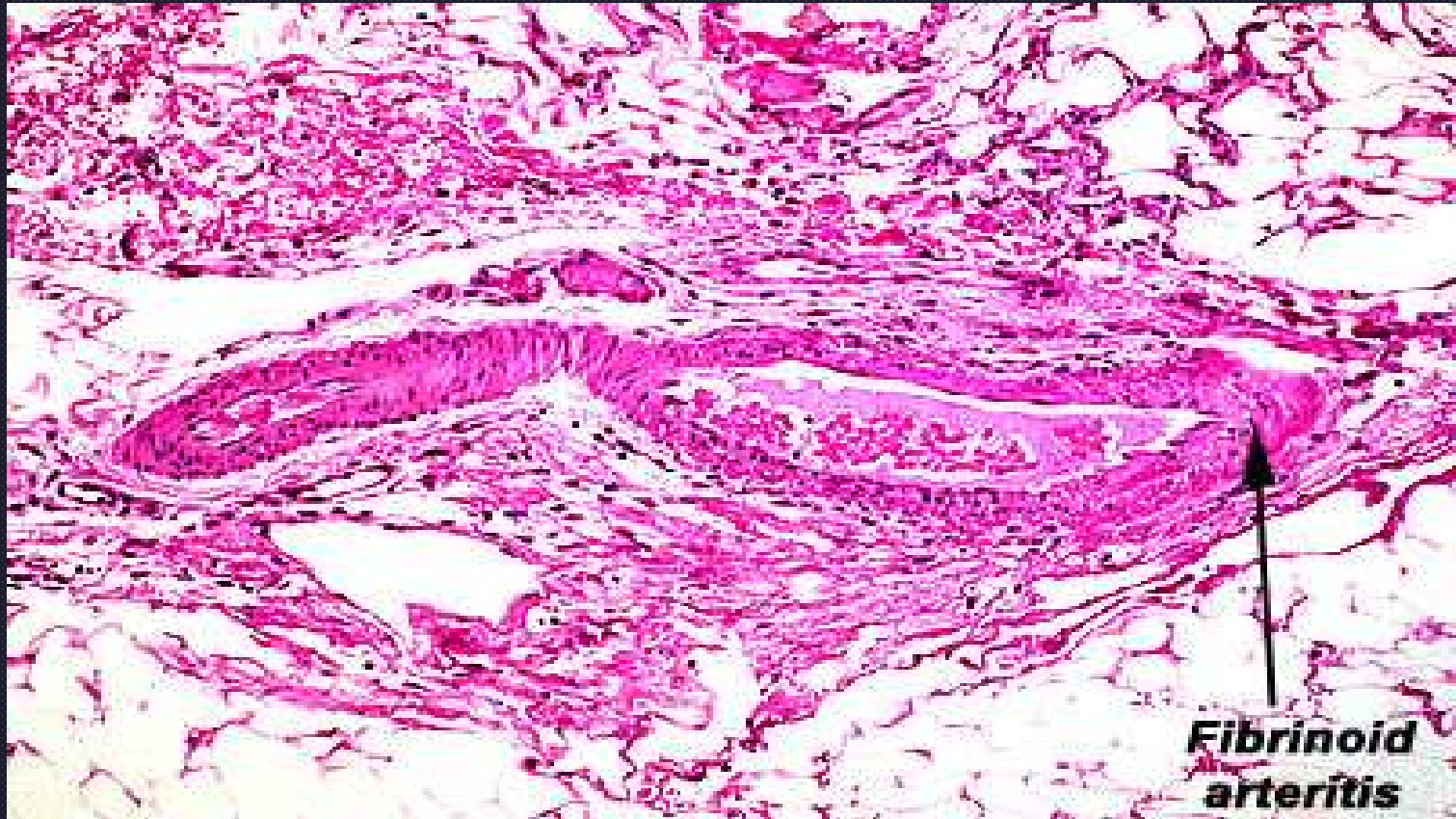
Vasculitis

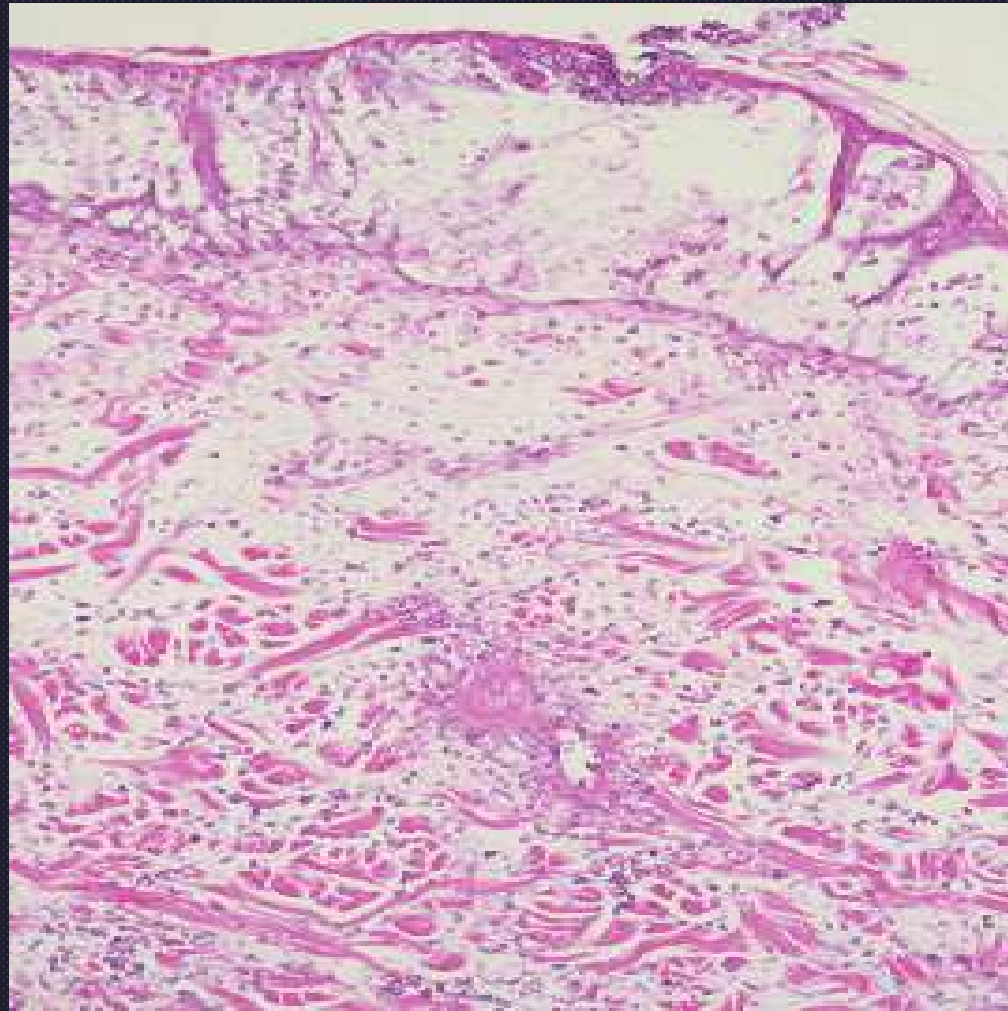


- An inflammatory cell infiltrate within or around the vessel wall (leukocytoclasia)
- Vascular injury (e.g. endothelial swelling or necrosis, fibrinoid change, intravascular fibrin thrombi)

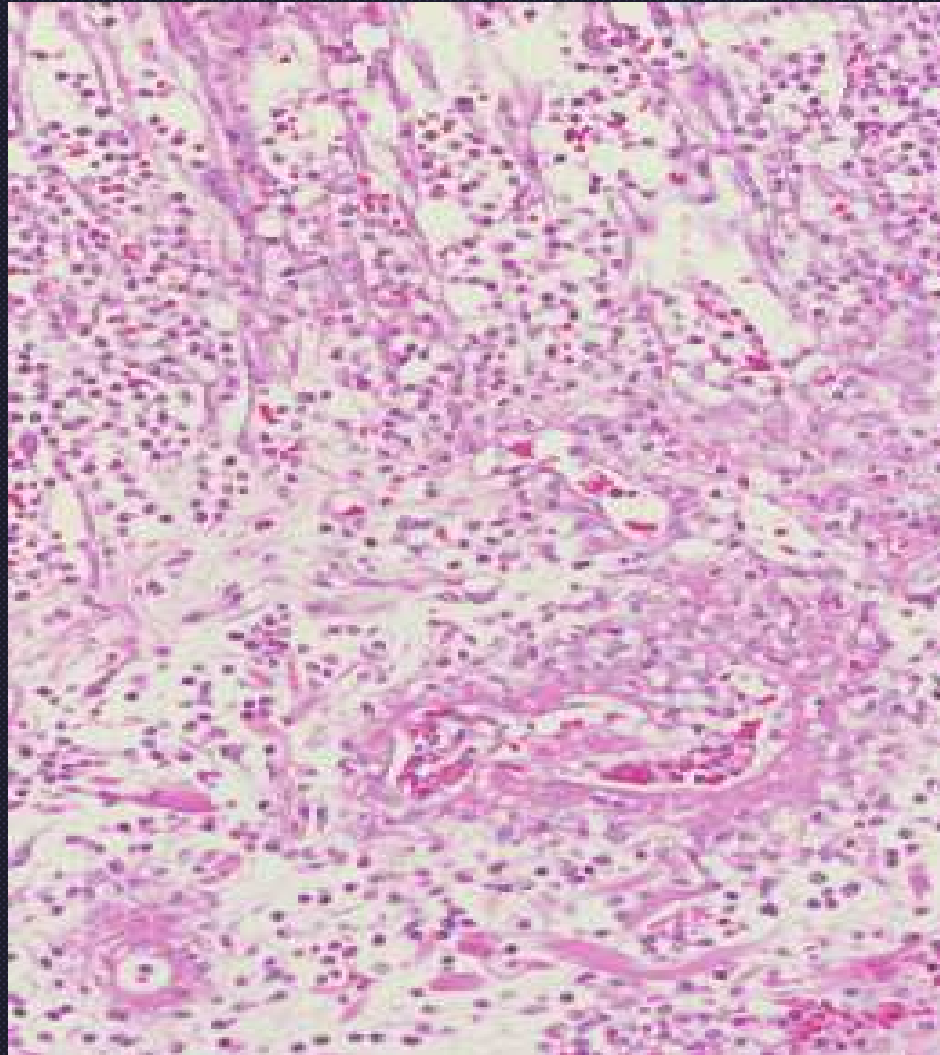


Vasculitis

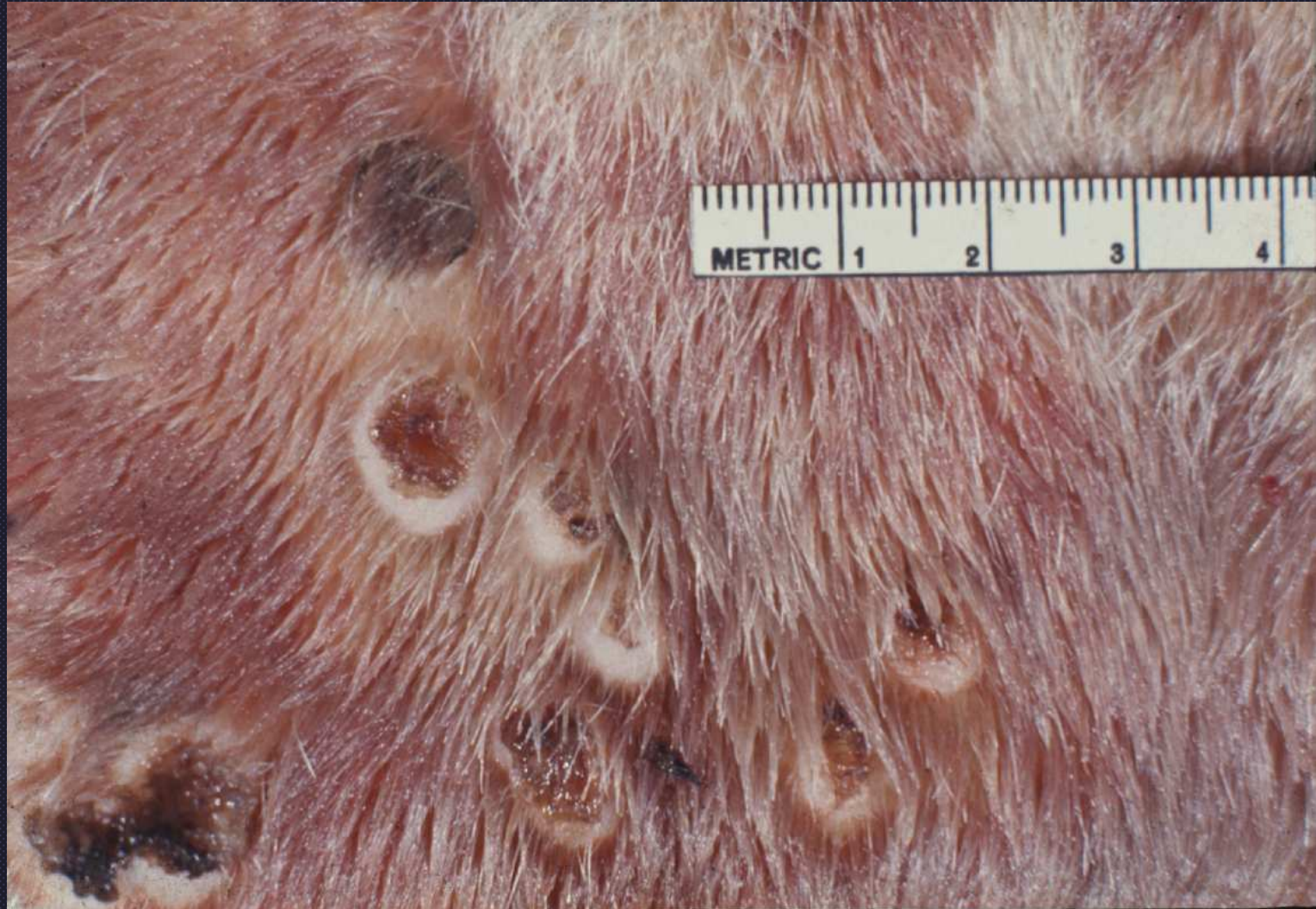



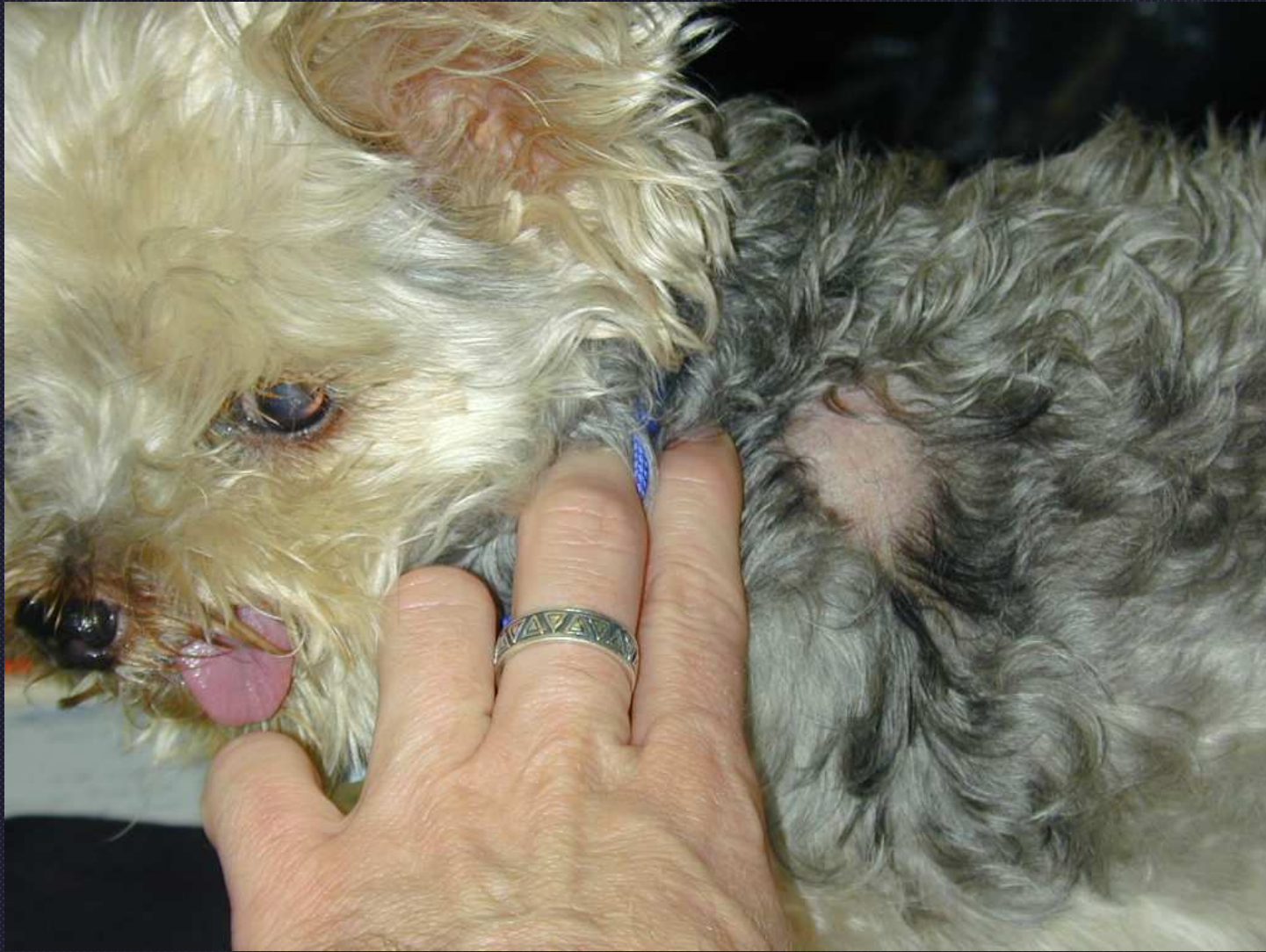Fibrinoid vasculitis



Fibrinoid vasculitis



Cutaneous vasculitis in a horse



Rabies vaccine associated alopecia