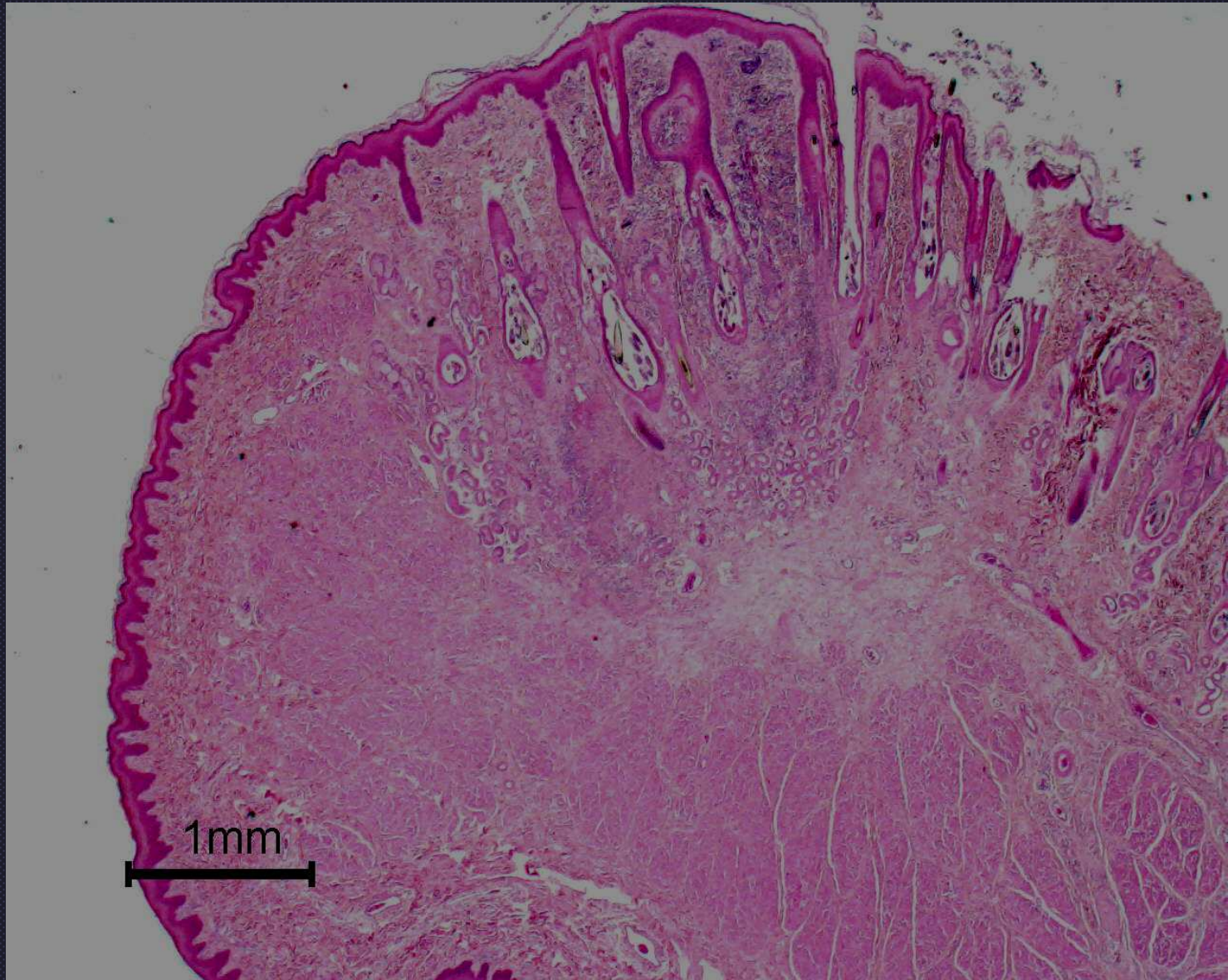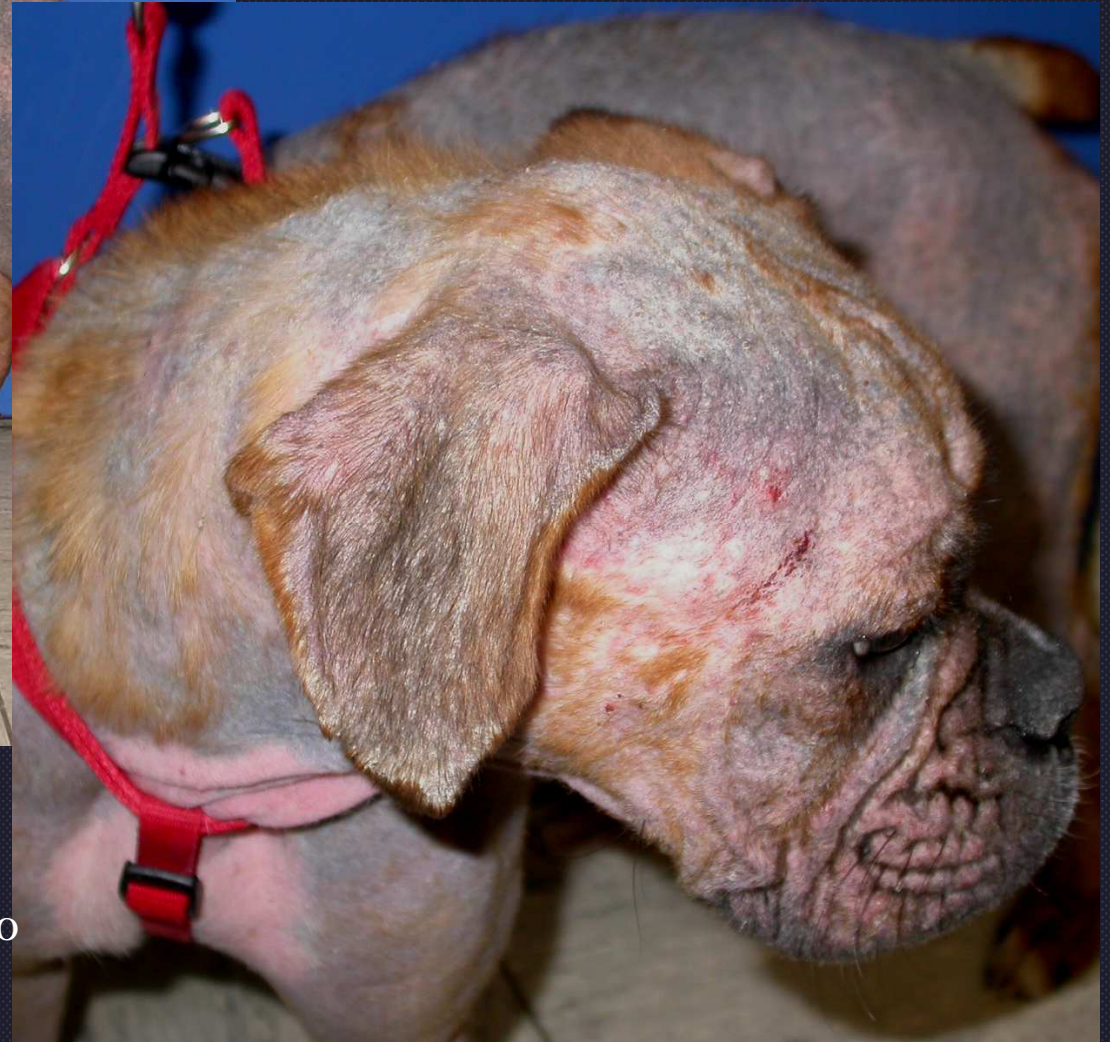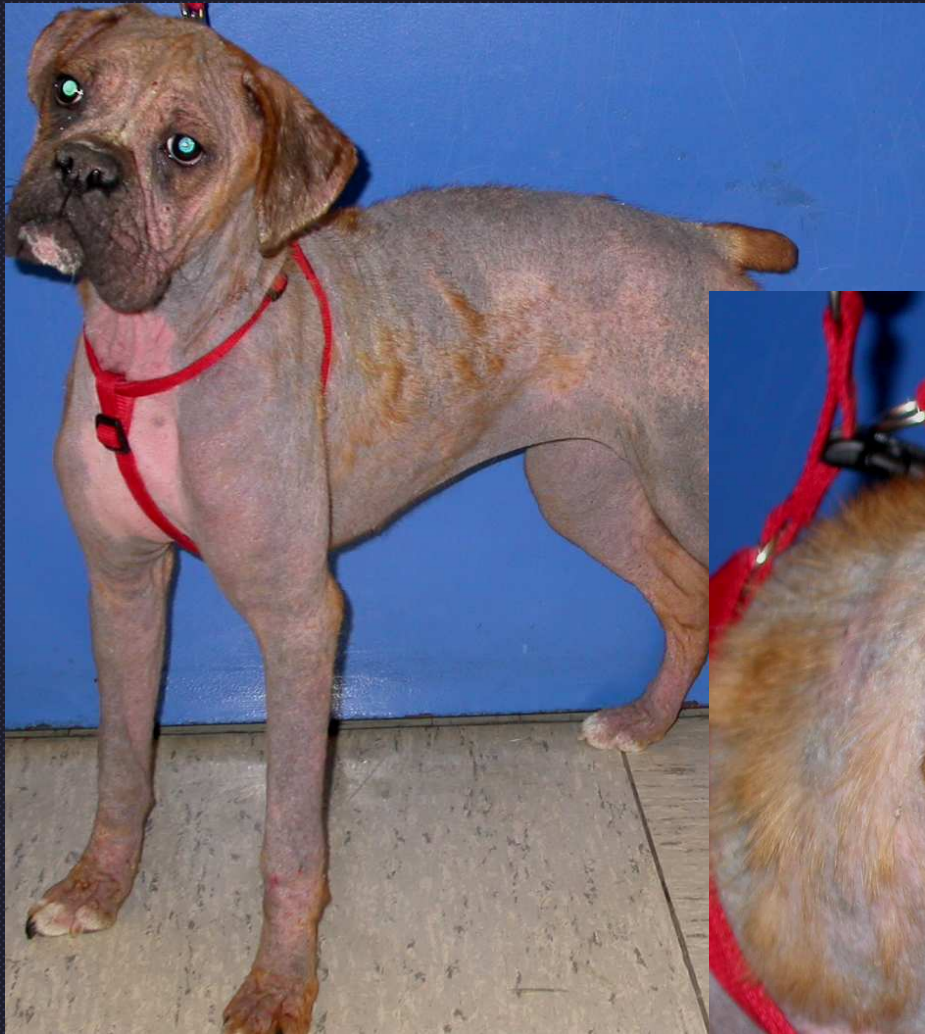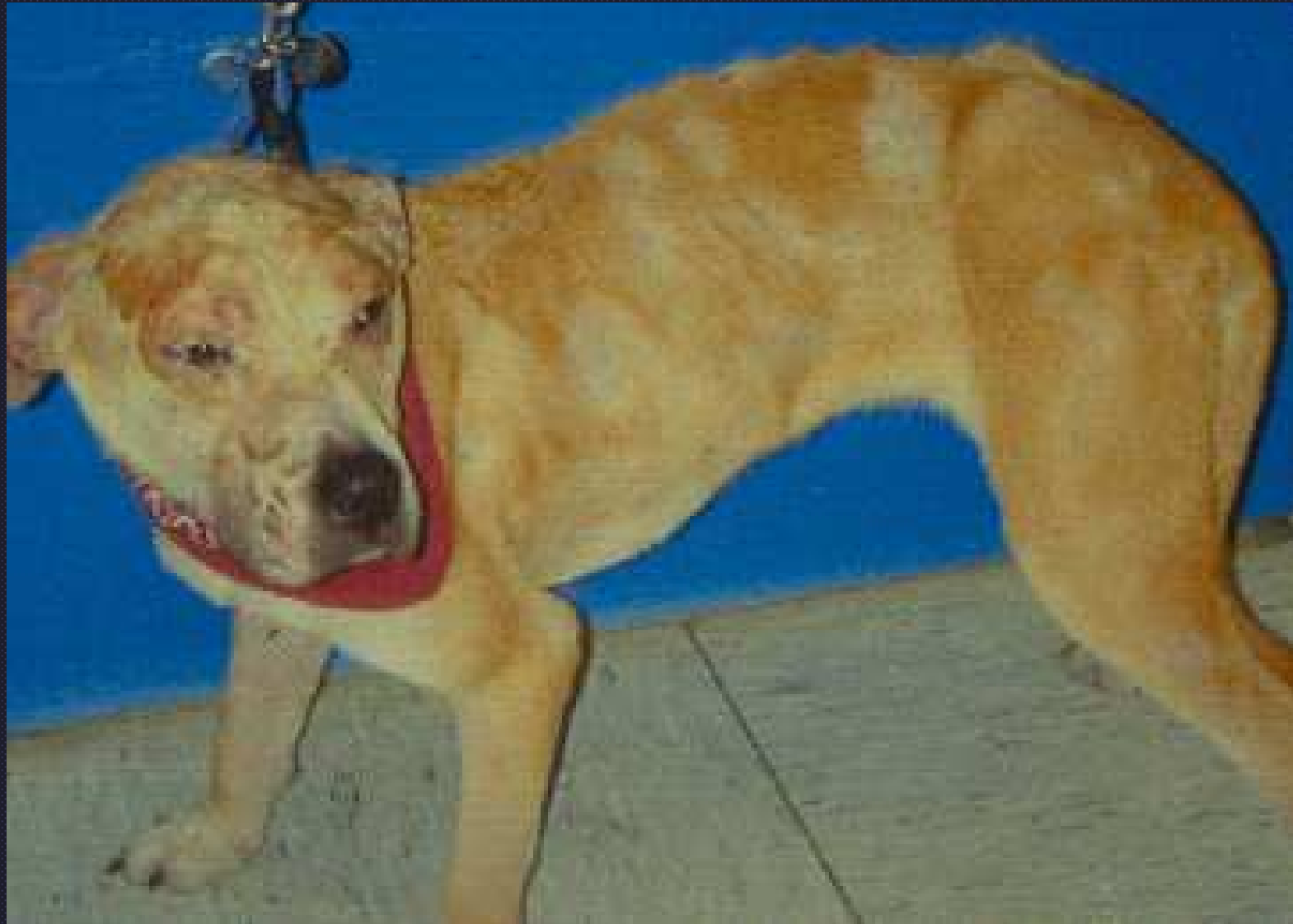


Lip- dog with demodicosis

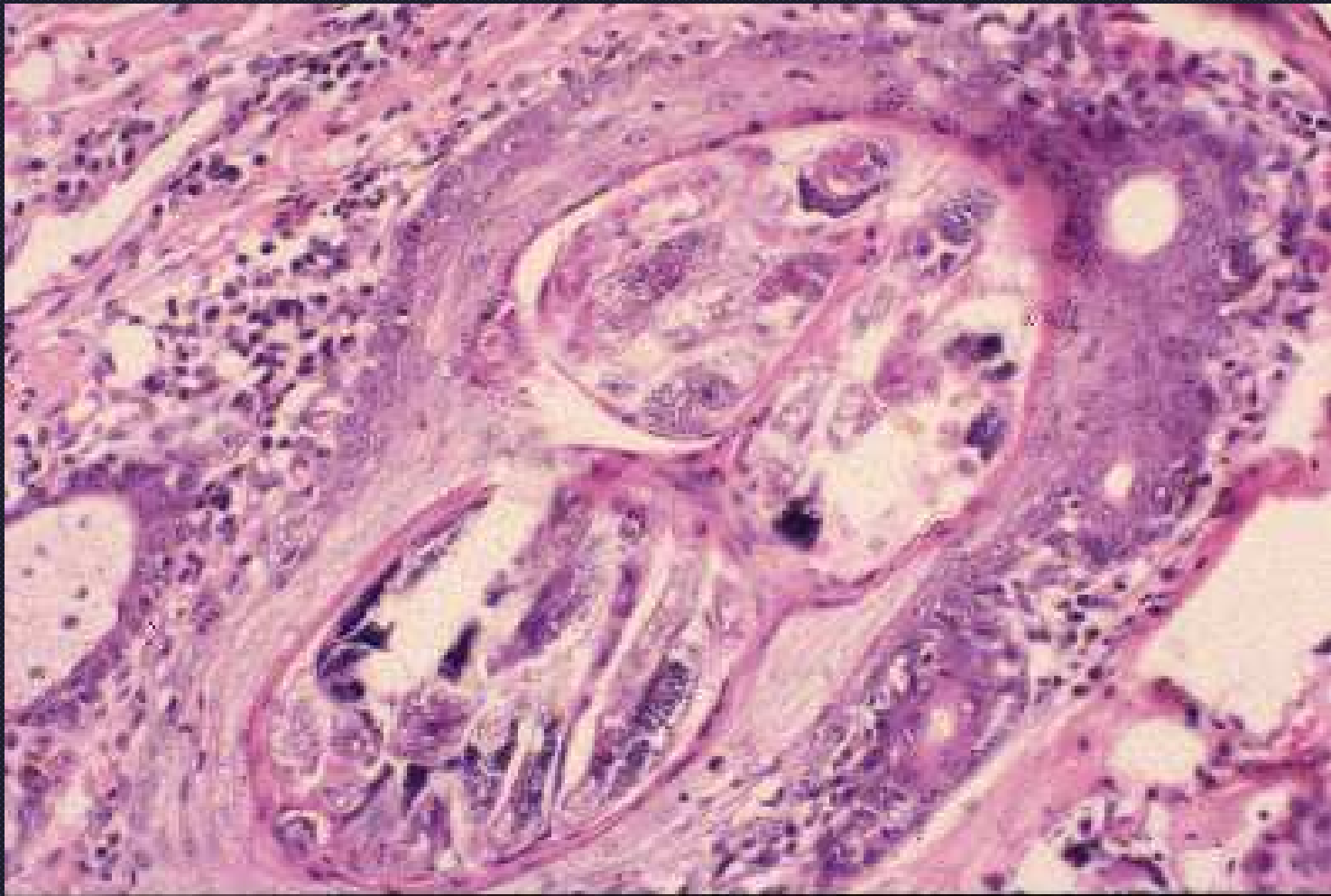


Demodicosis

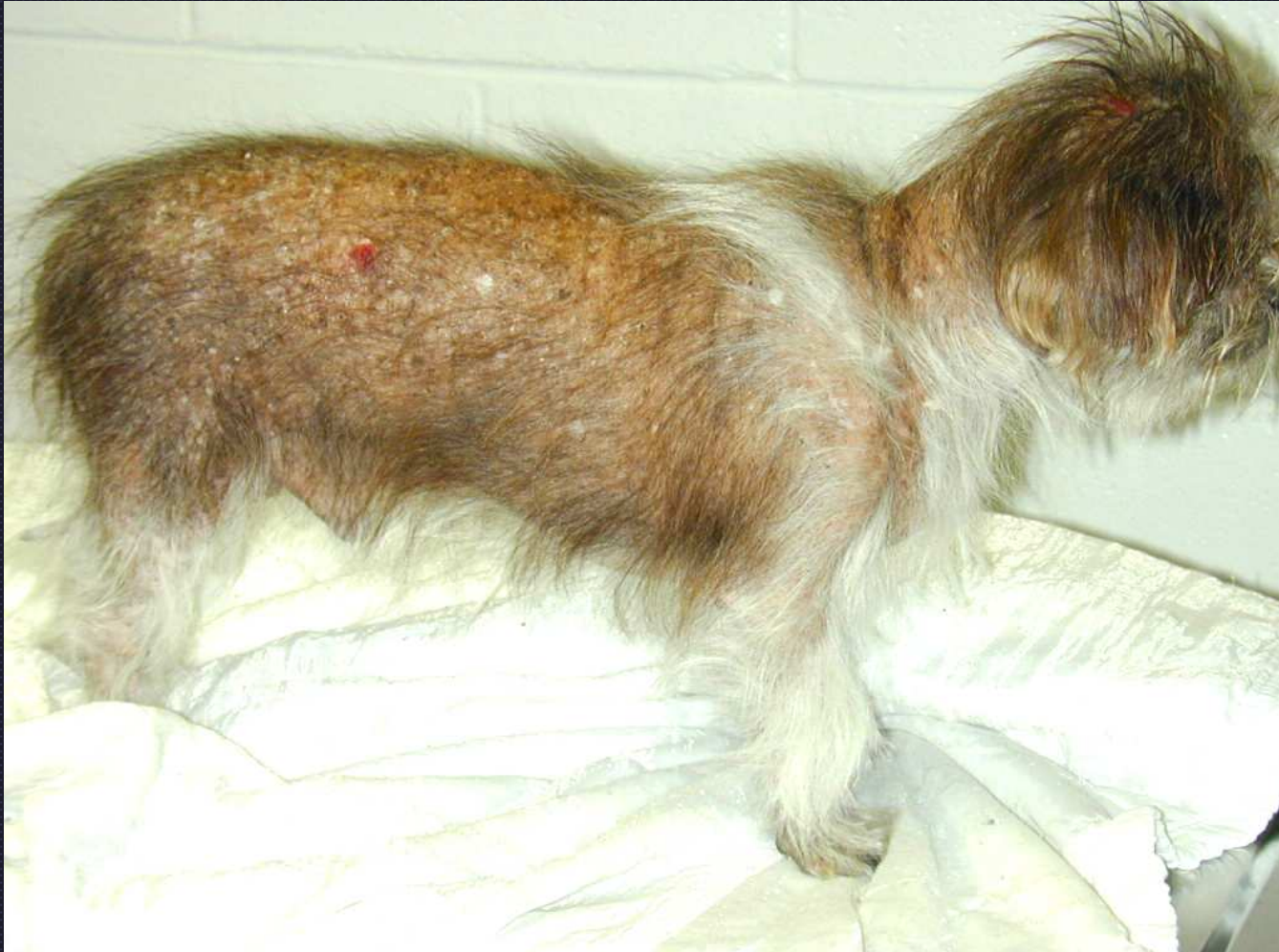Note the blue-black pigment due to hair follicle hyperpigmentation



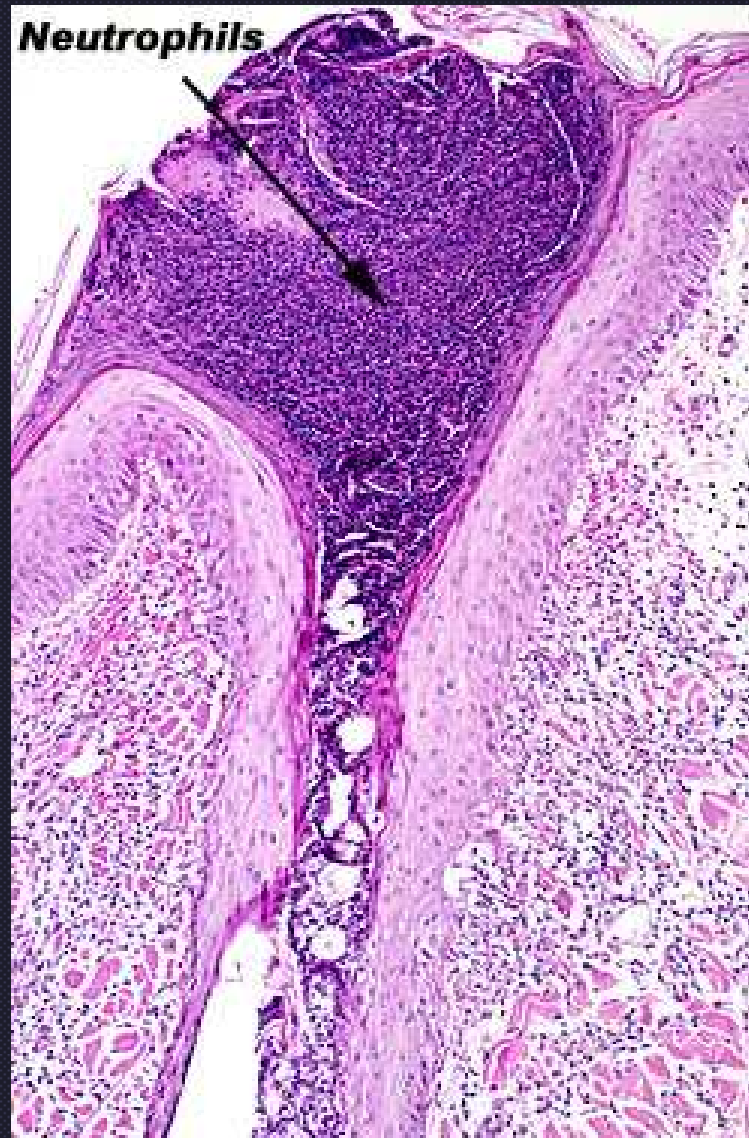
Demodicosis in a dog with thermal burn on head



Demodicosis



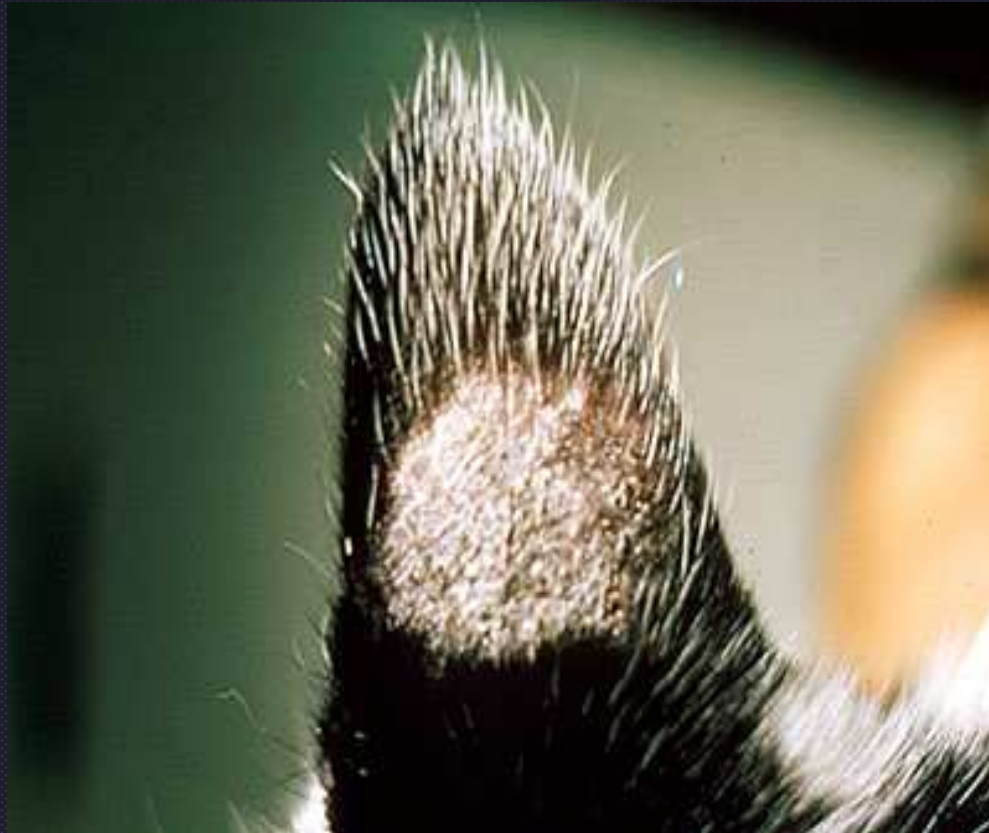Demodicosis



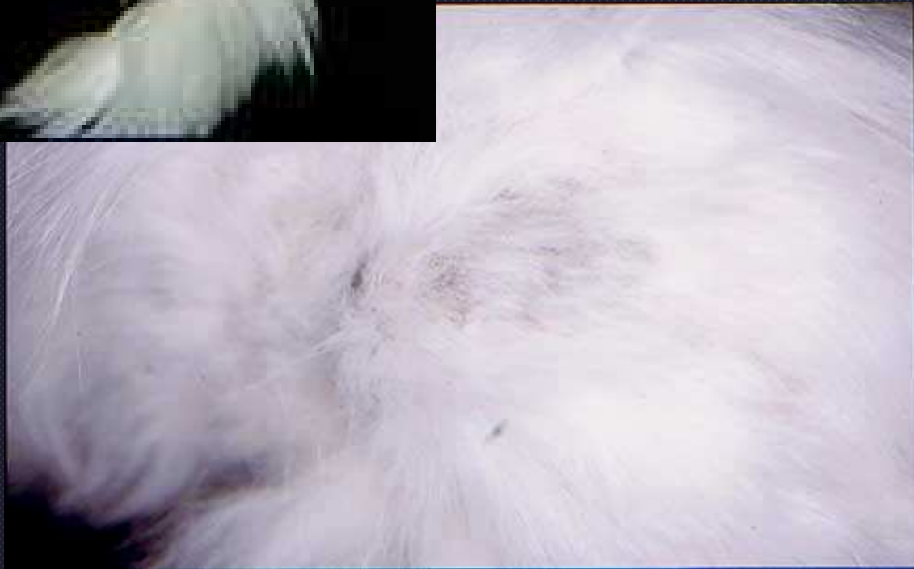Luminal folliculitis



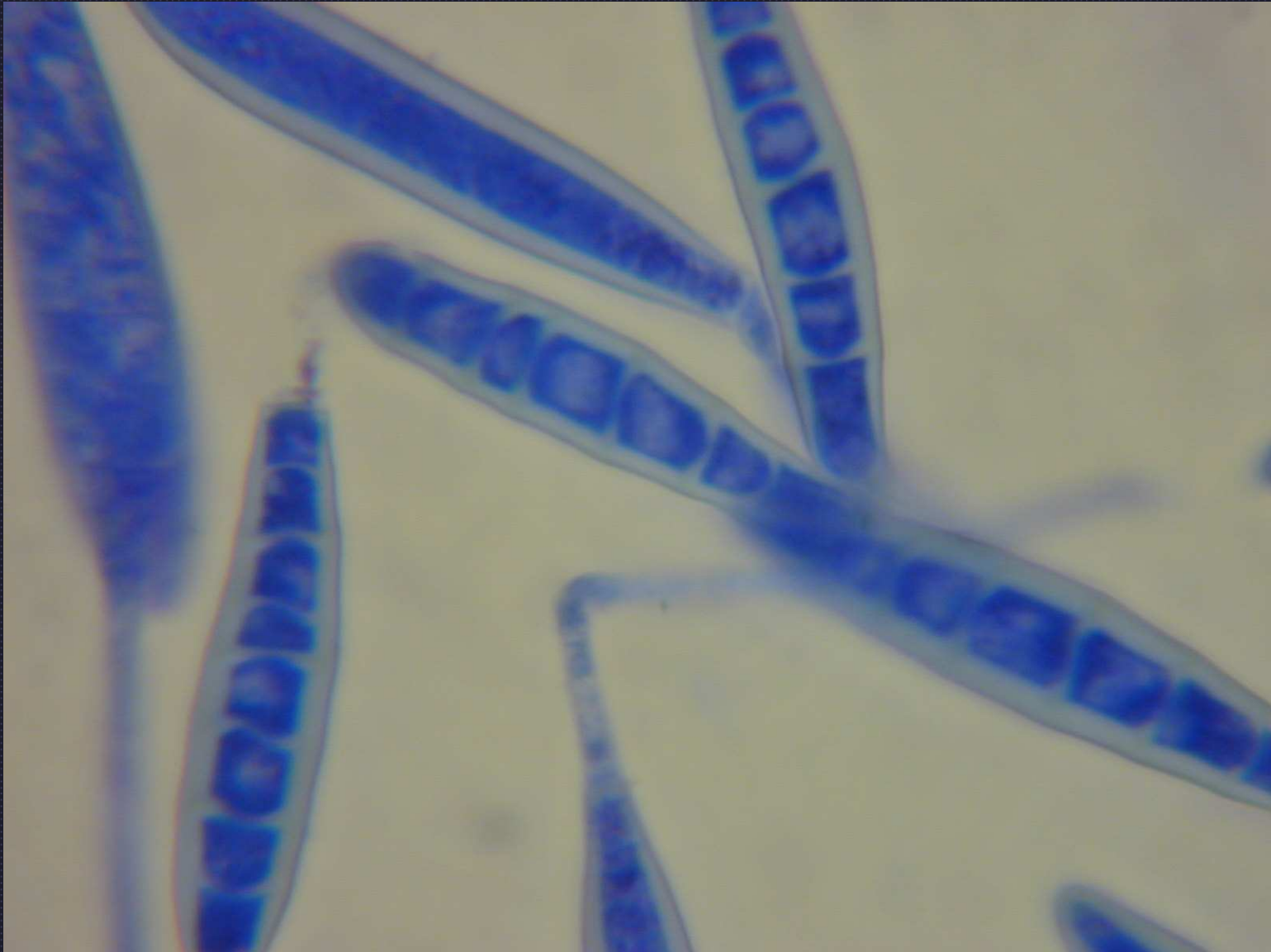
Short-coated breed folliculitis



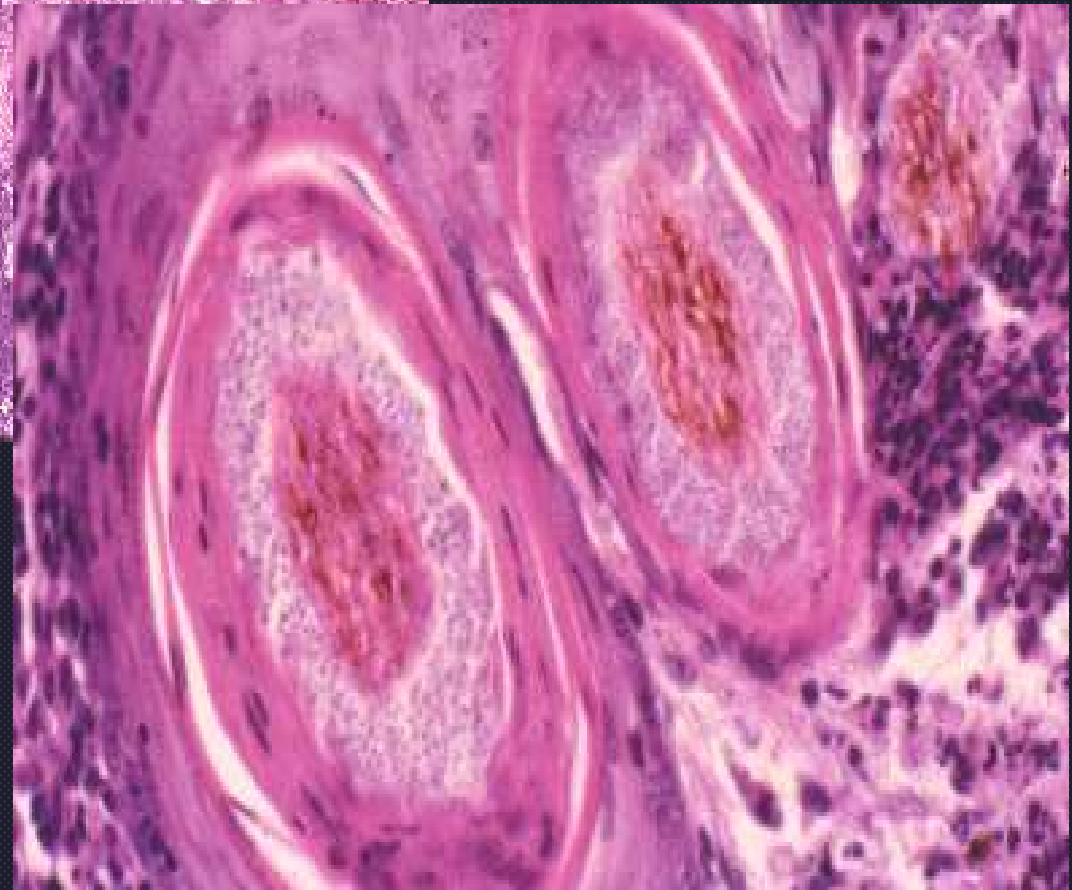
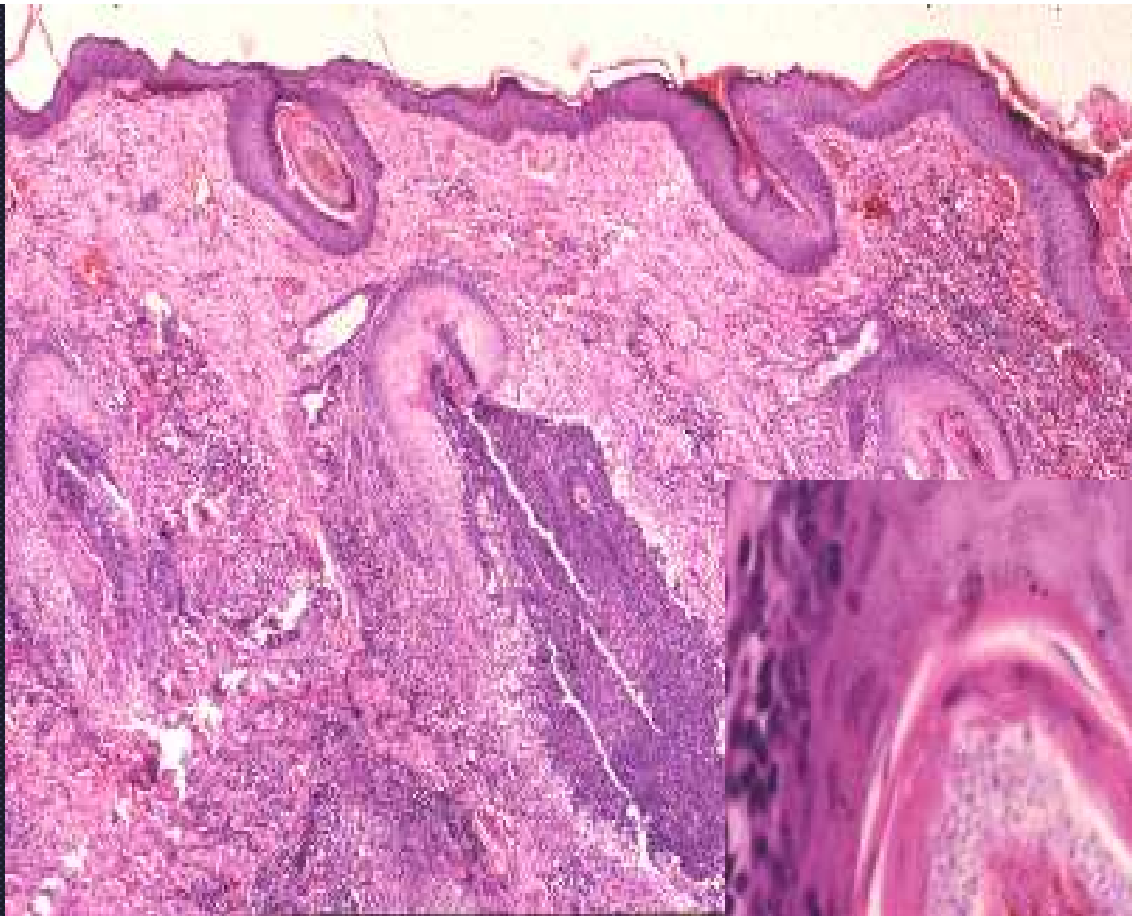
“Classic” dermatophytosis in a cat



Dermatophytosis



M. canis macroconidia

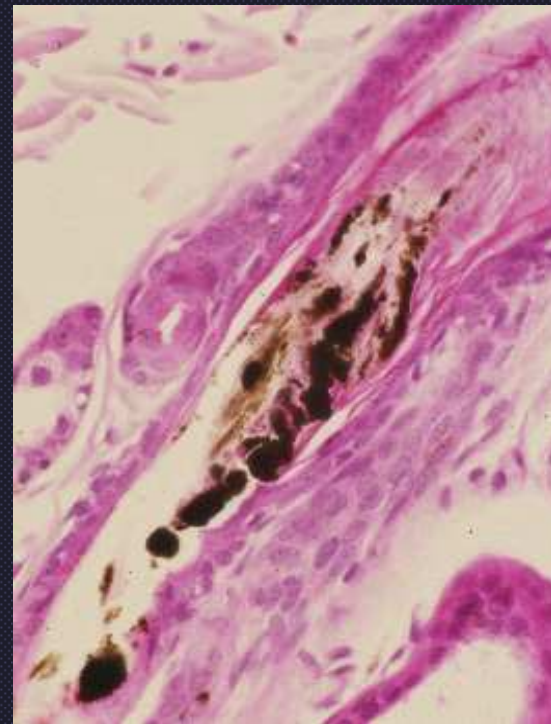
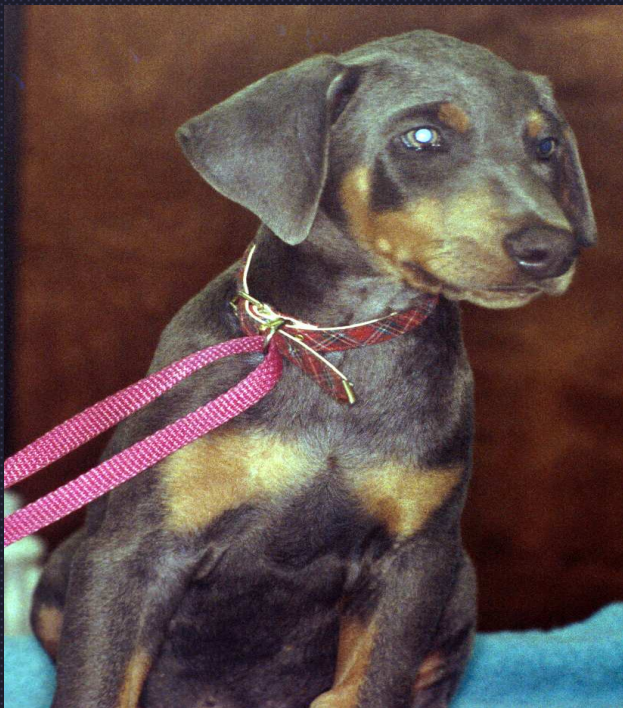

Dermatophytosis

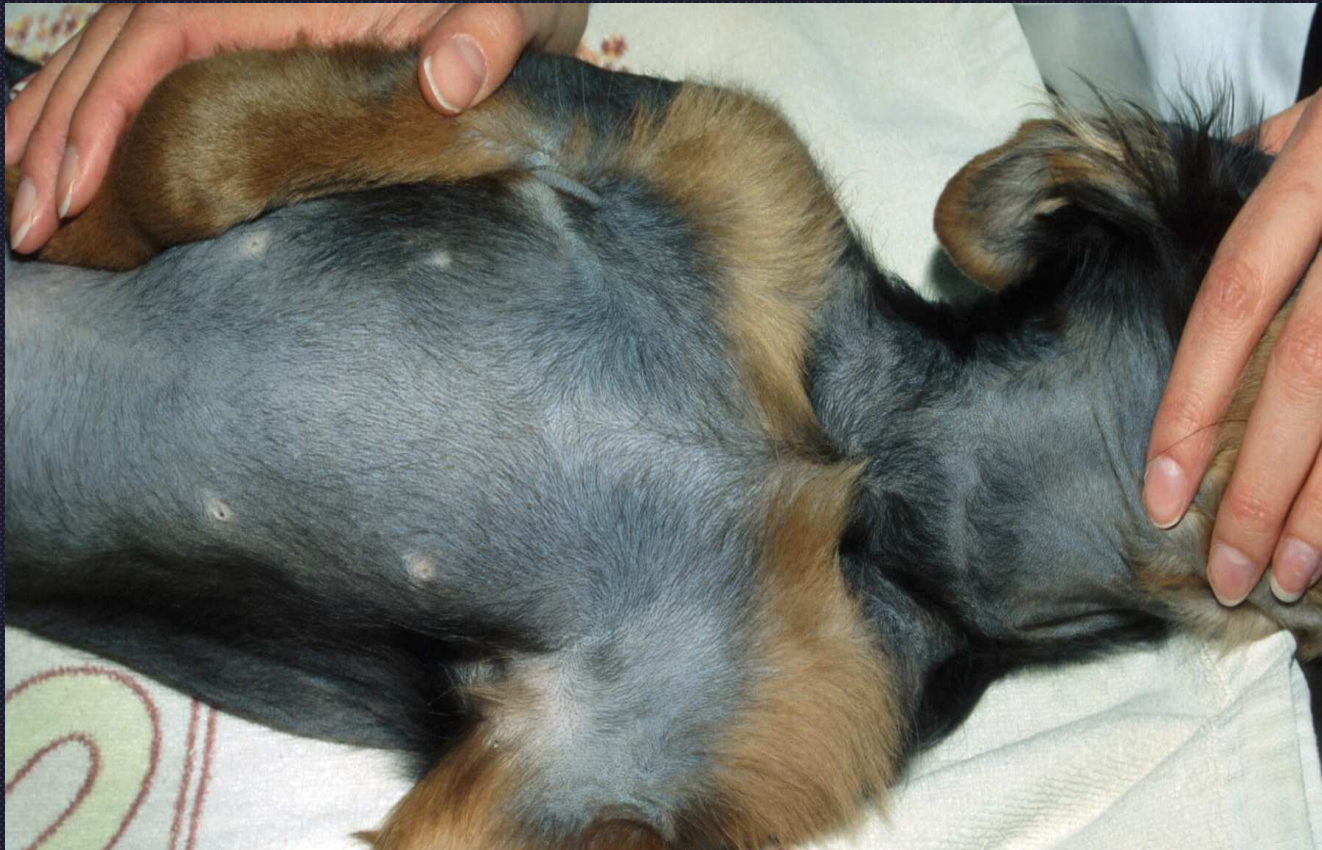Dermatophytosis

- Specific group of fungal organisms that utilize keratin in hair
- Microsporum, trichophyton, epidermophyton
- Mural folliculitis in cats and horses
- Luminal folliculitis, furunculosis, arthrospores, hyphae in shafts

Hair follicle Dysplasia Color Dilution Alopecia

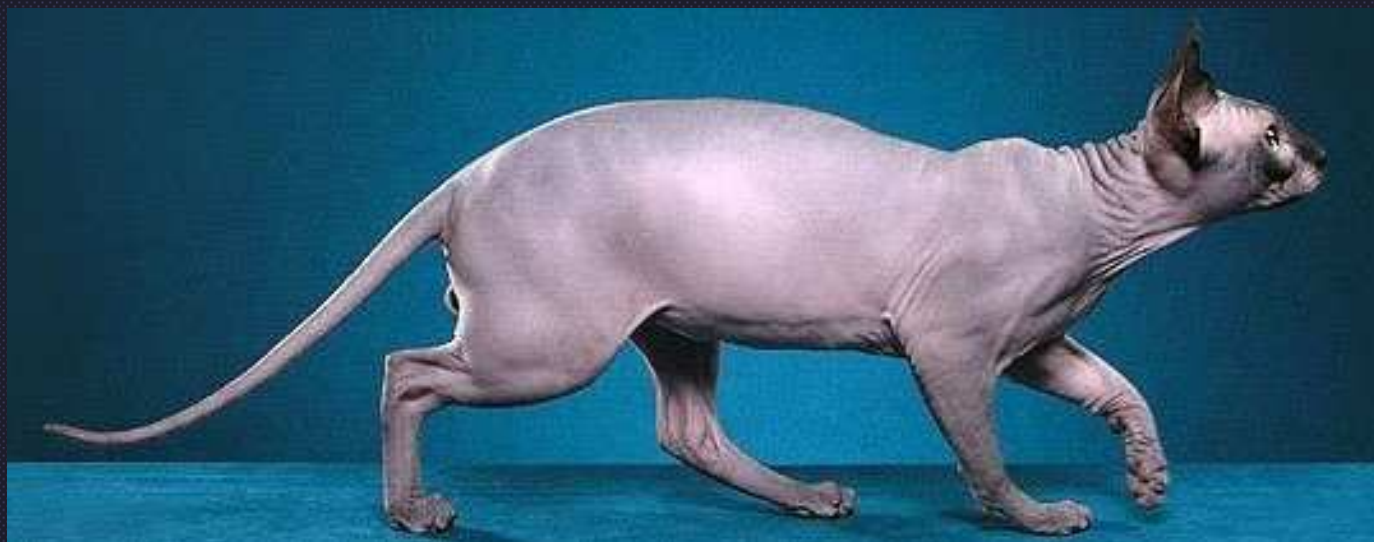


Color Dilution Alopecia





Black hair follicular dysplasia



Follicular dysplasia