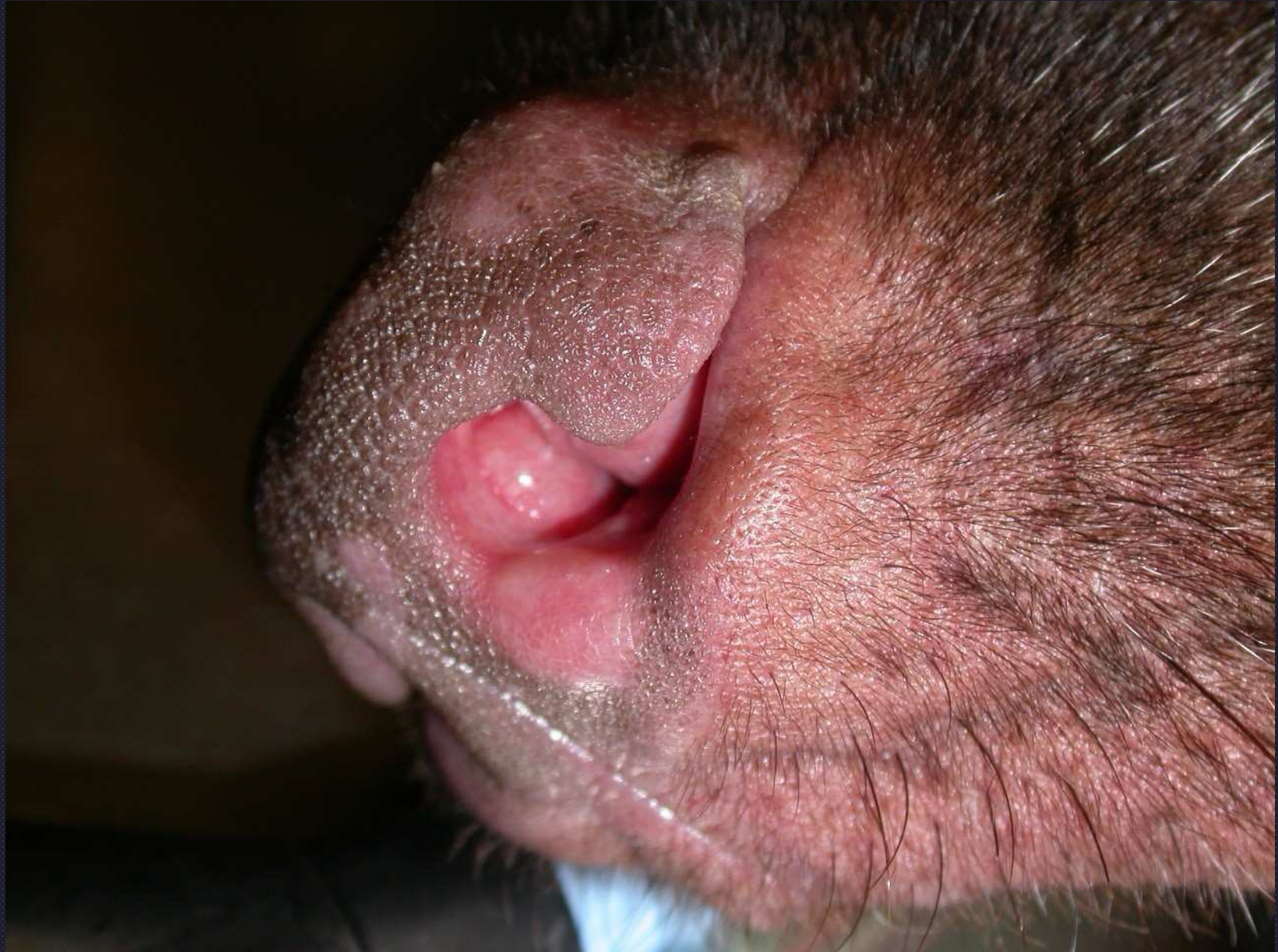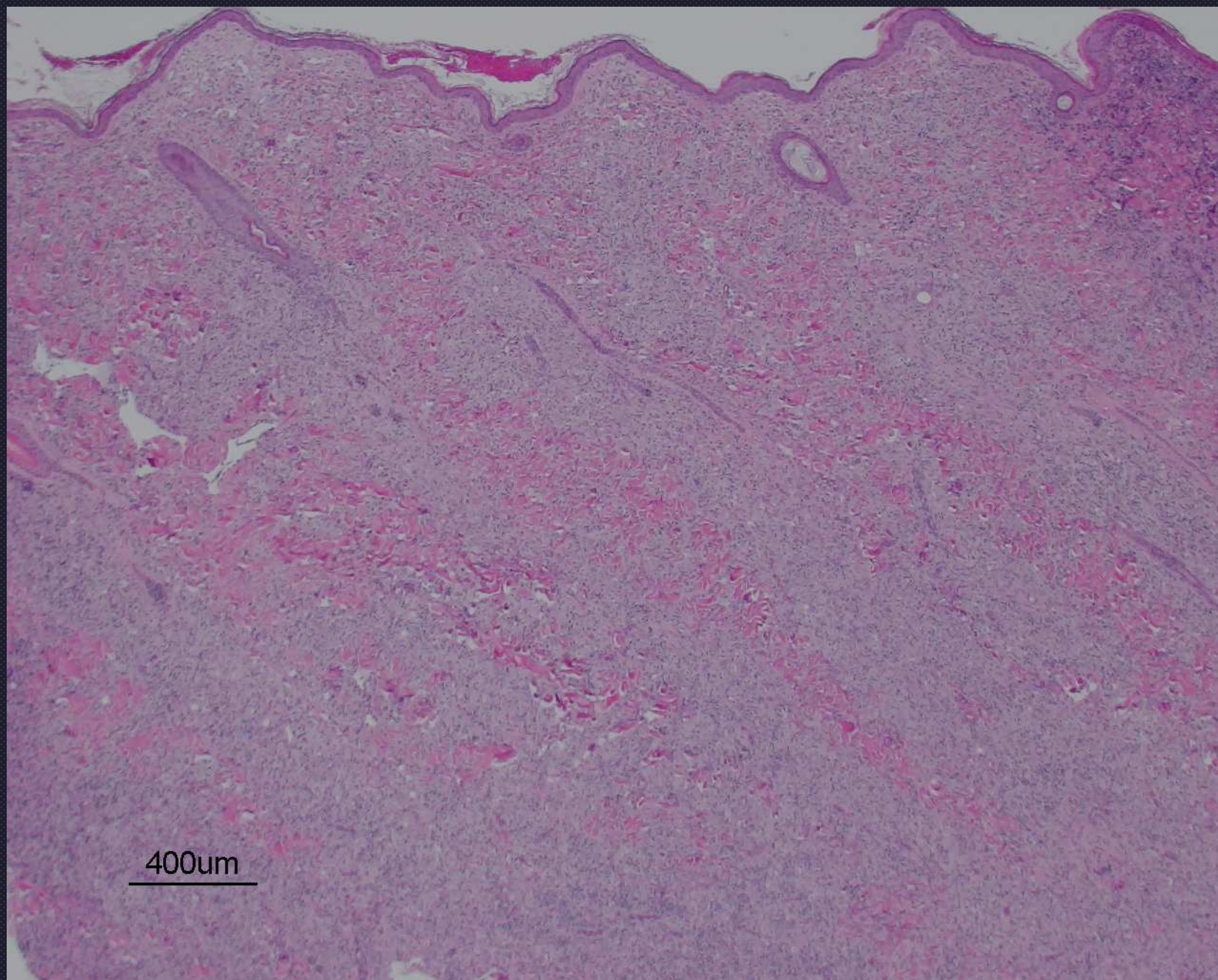




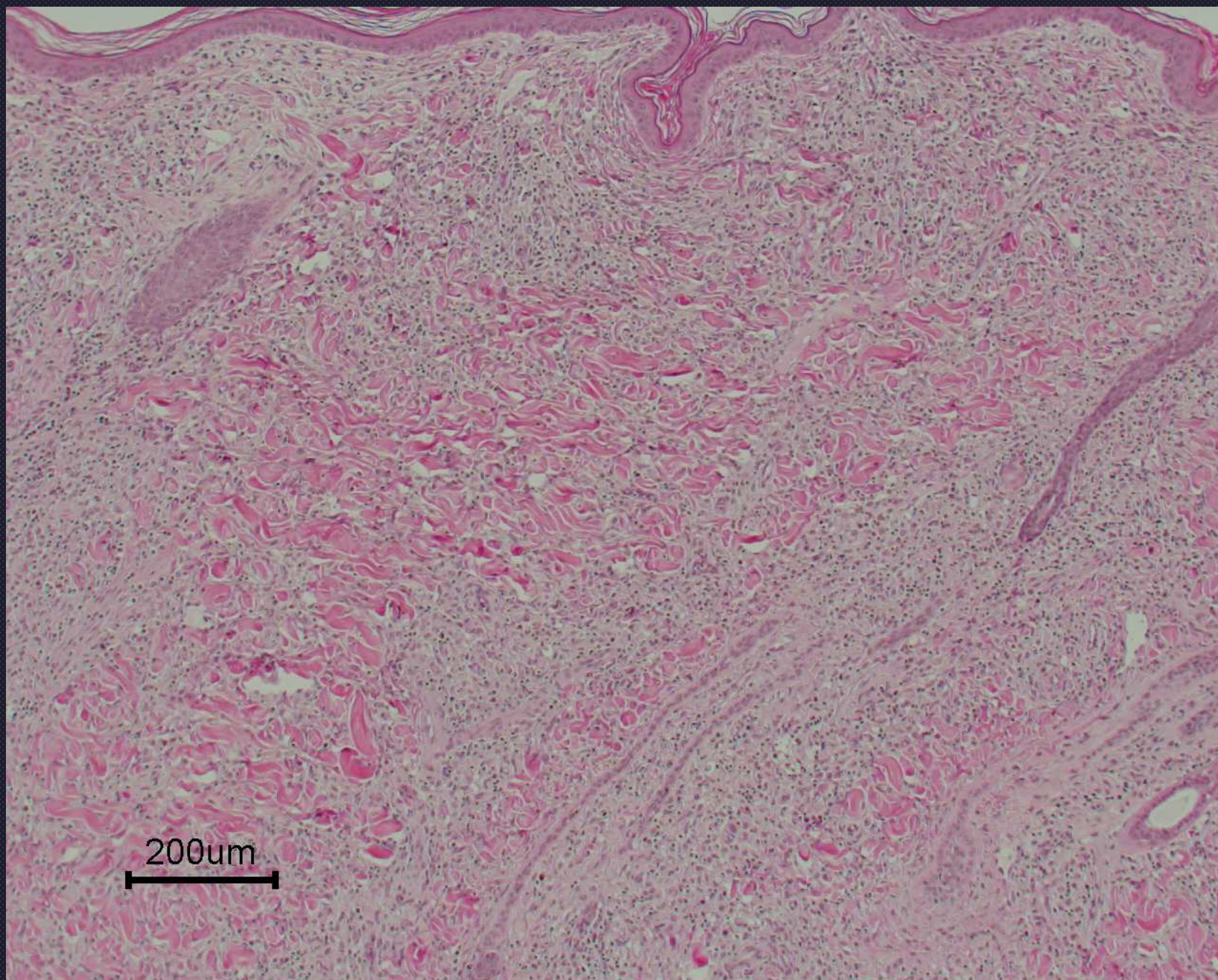
Cutaneous reactive histiocytosis  
“clown nose”





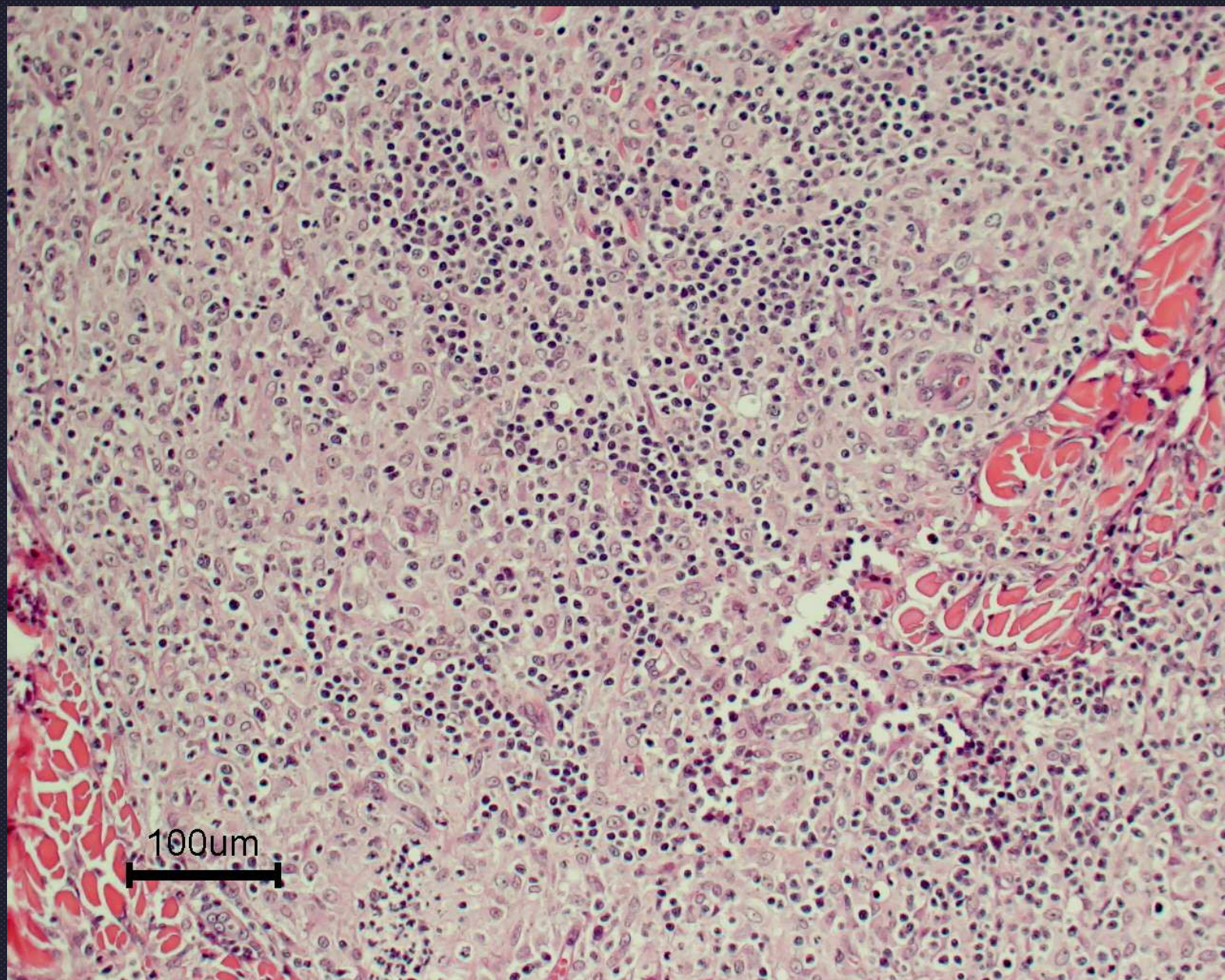
Cutaneous reactive histiocytosis





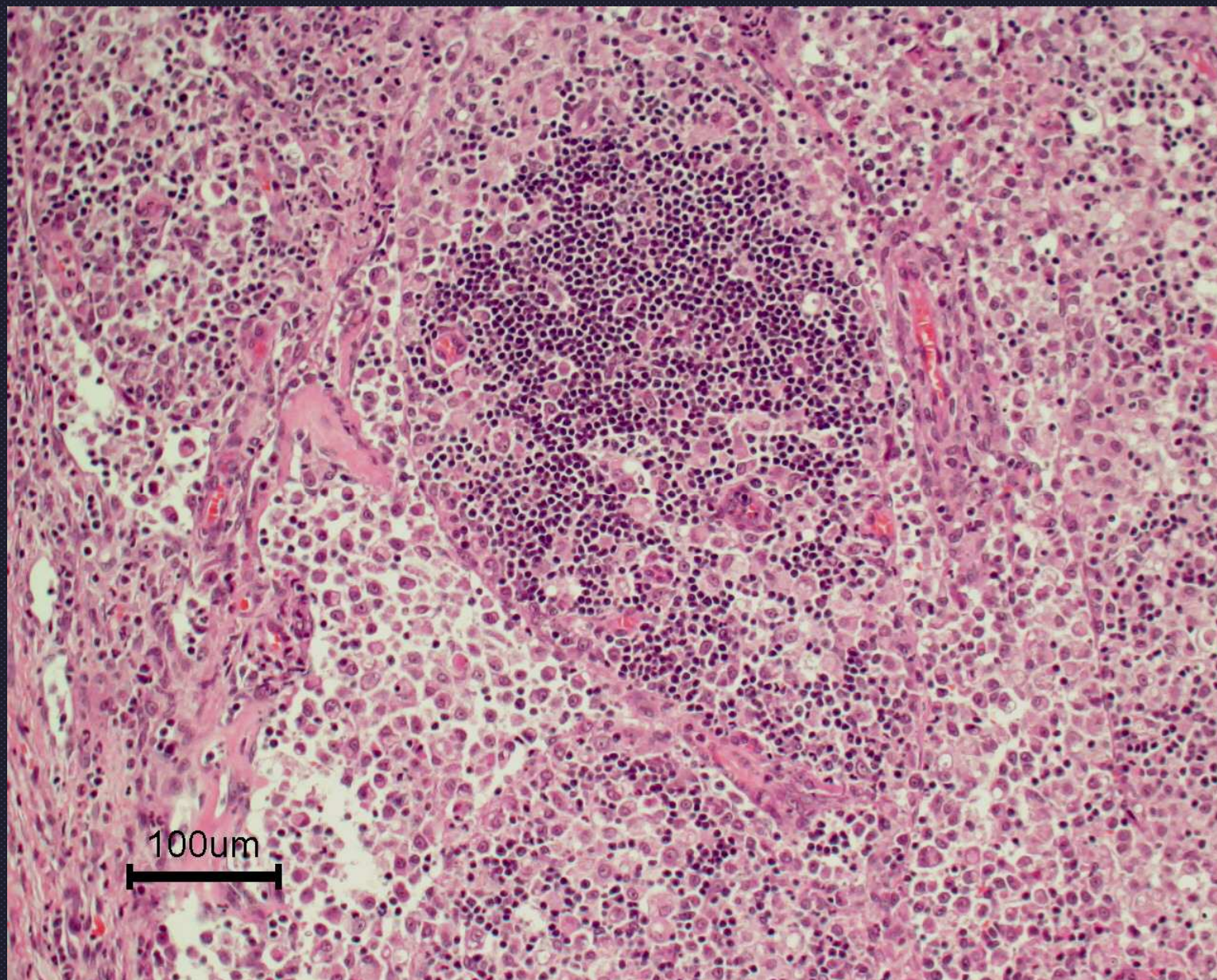
Cutaneous reactive histiocytosis





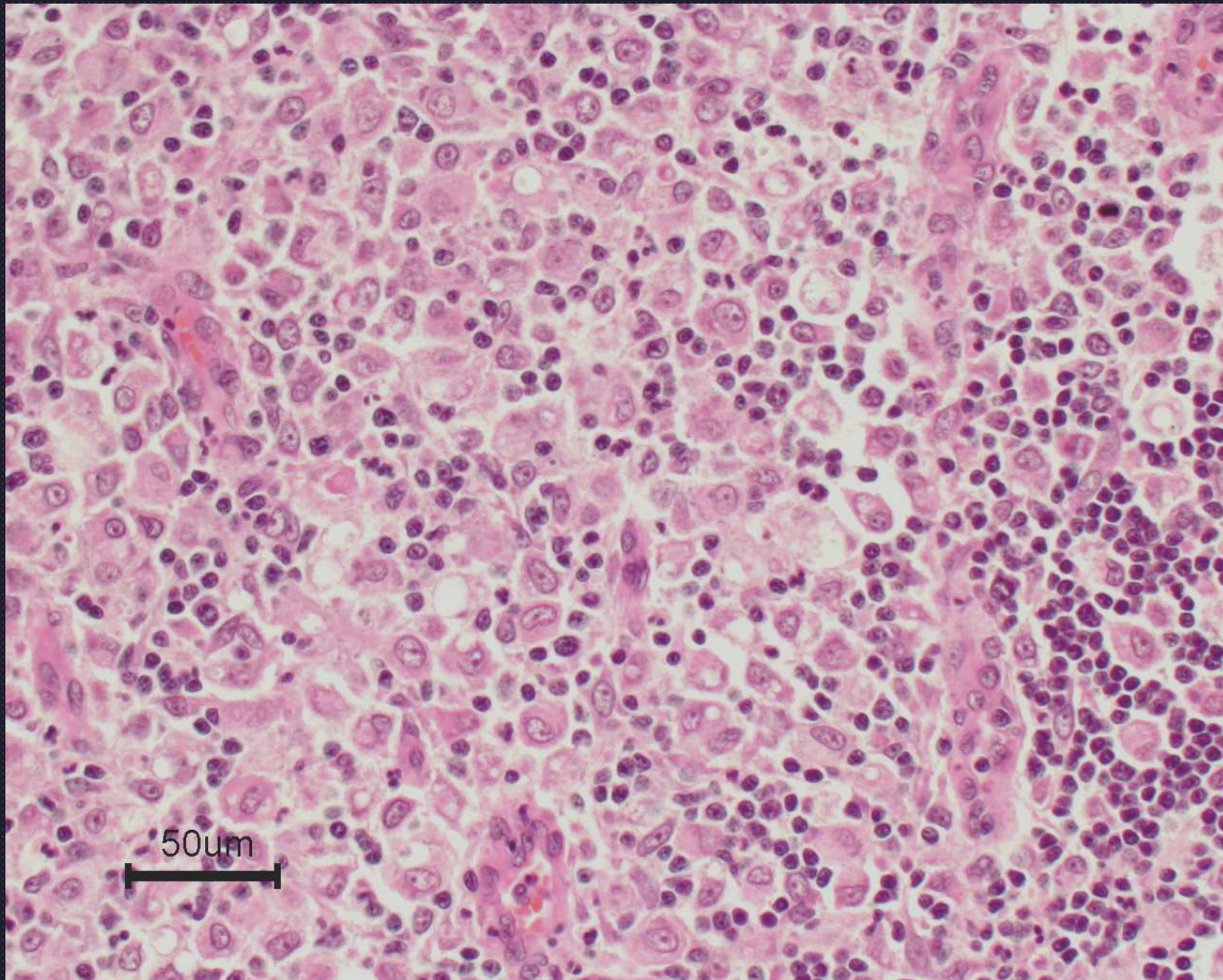
Cutaneous reactive histiocytosis






Peripheral LN  
Systemic reactive histiocytosis





Peripheral LN  
Systemic reactive histiocytosis

# Perifolliculitis/Folliculitis/Furunculosis



# Disorders of Hair follicles

- Inflammation → Folliculitis
- Hair follicle dysplasia
- Hair cycling Disorders
- Atrophy/Miniaturization
- Neoplasia



# Definitions

- **Perifolliculitis**- inflammation around hair follicle
- **Luminal Folliculitis**- inflammation of the lumen of the hair follicle
- **Mural folliculitis**- inflammation within the wall of the outer root sheath



- **Furunculosis-** follicle rupture with inflammation; foreign body reaction to keratin in dermis; lesions often progress from folliculitis and furunculosis