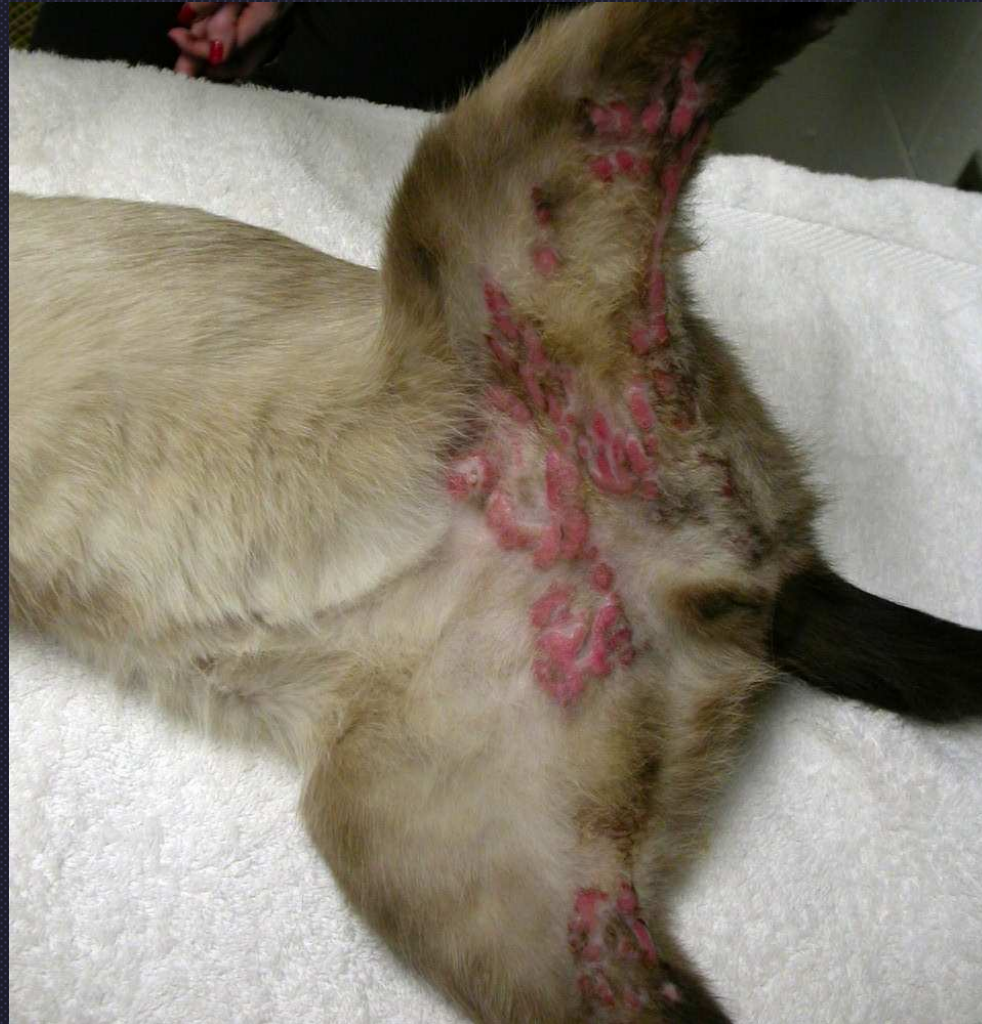
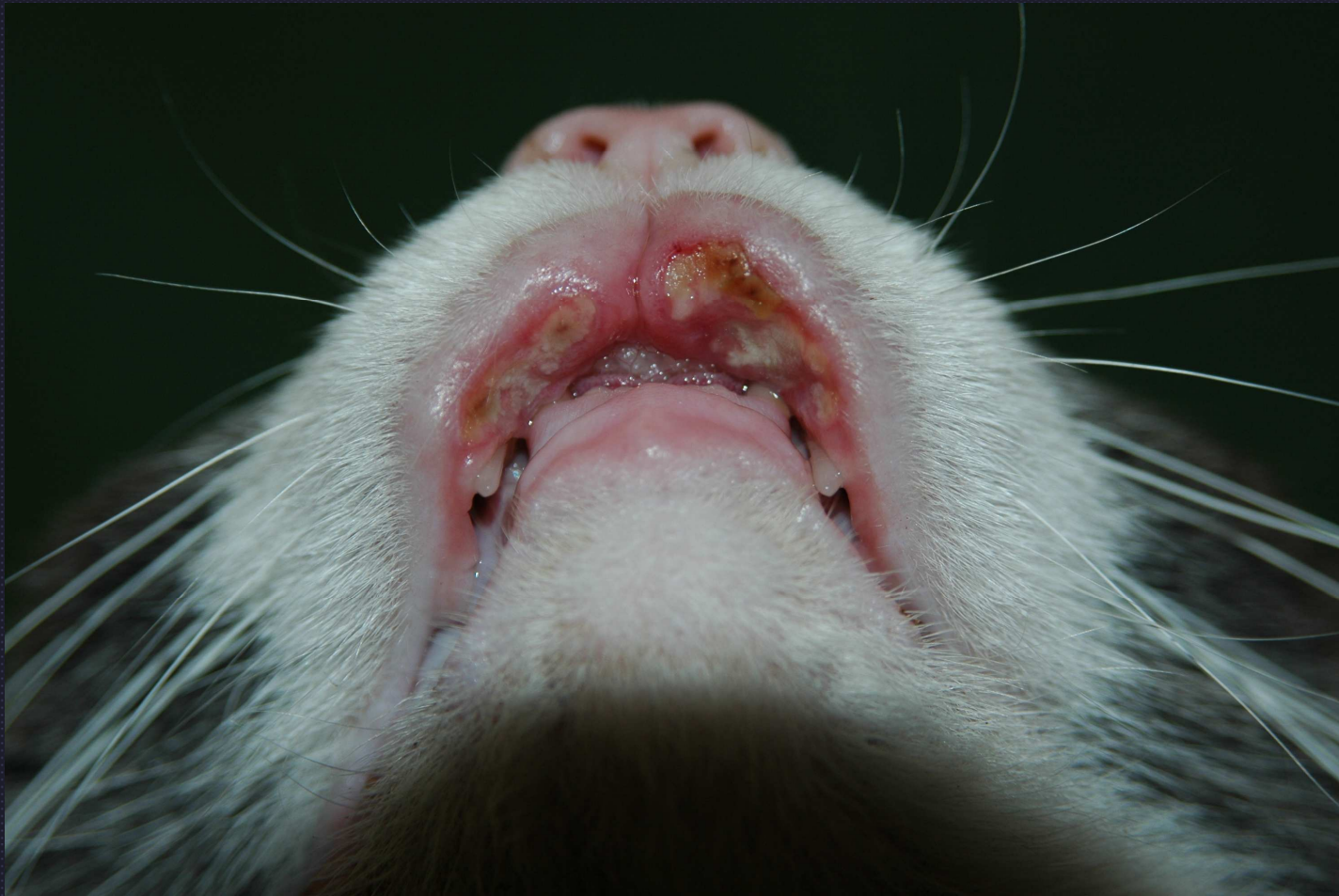
Eosinophilic granulomas

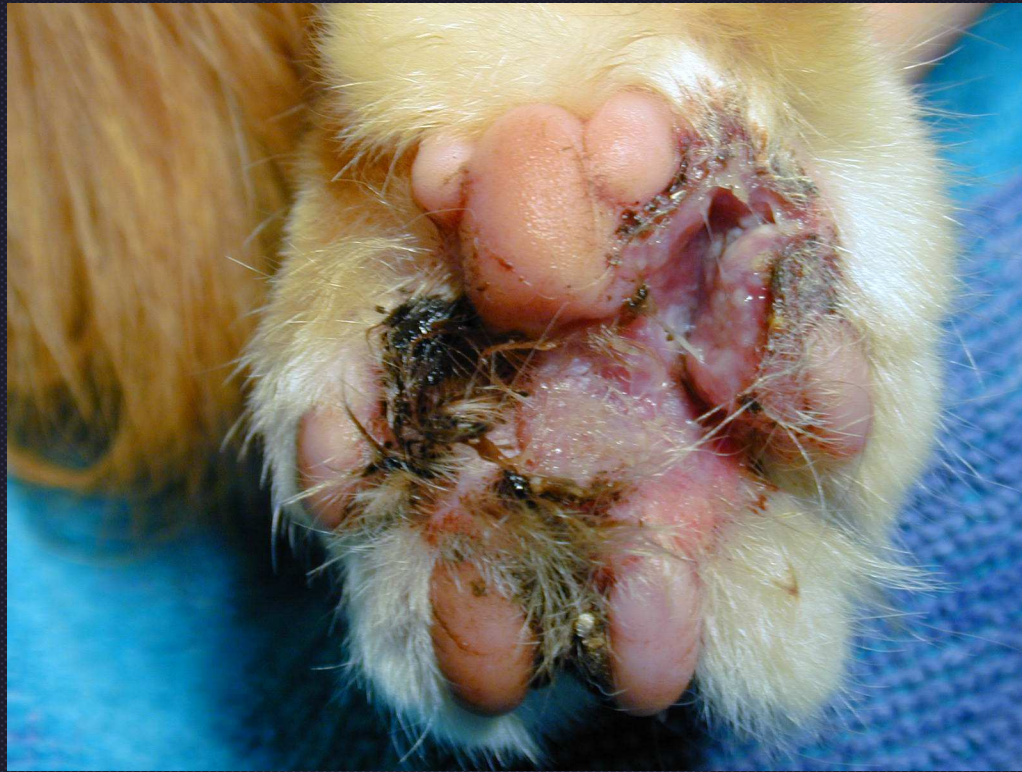- Correct term “flame figures”
- Do not use “collagen degeneration” or “collagenolysis”



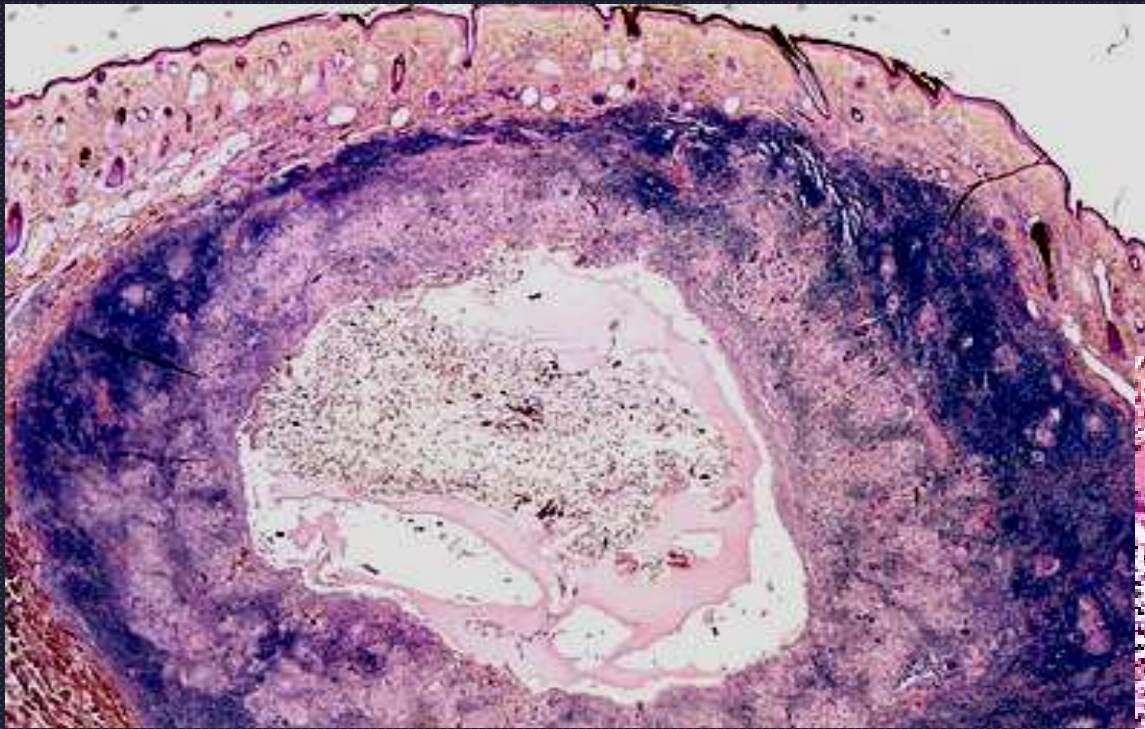
Coalescing eosinophilic granulomas



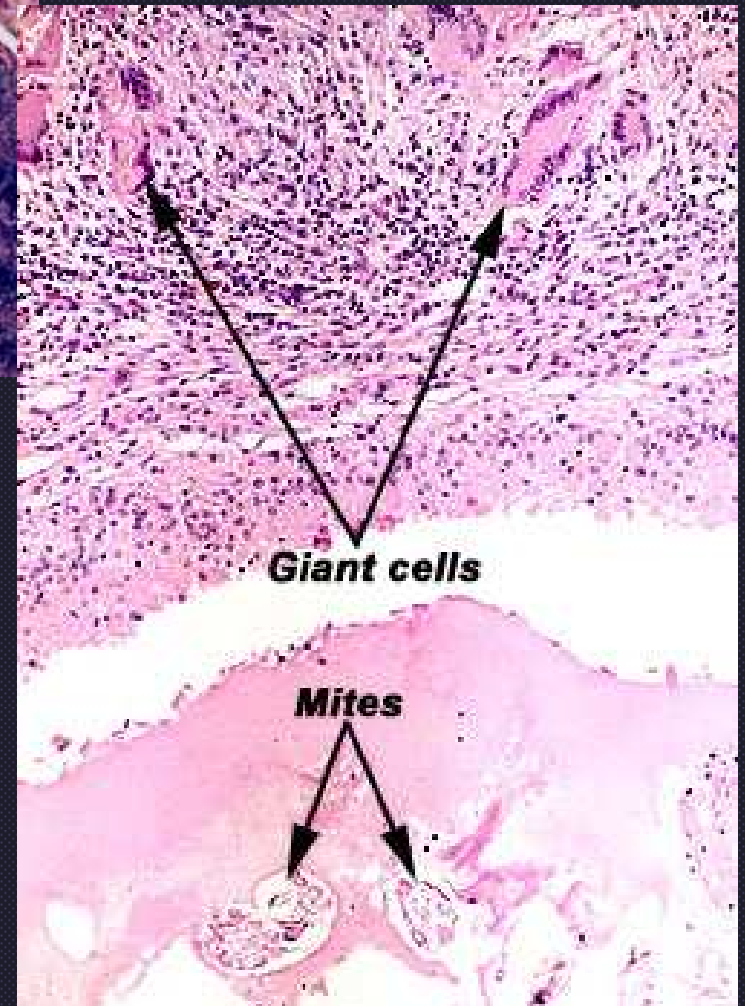
Eosinophilic granuloma

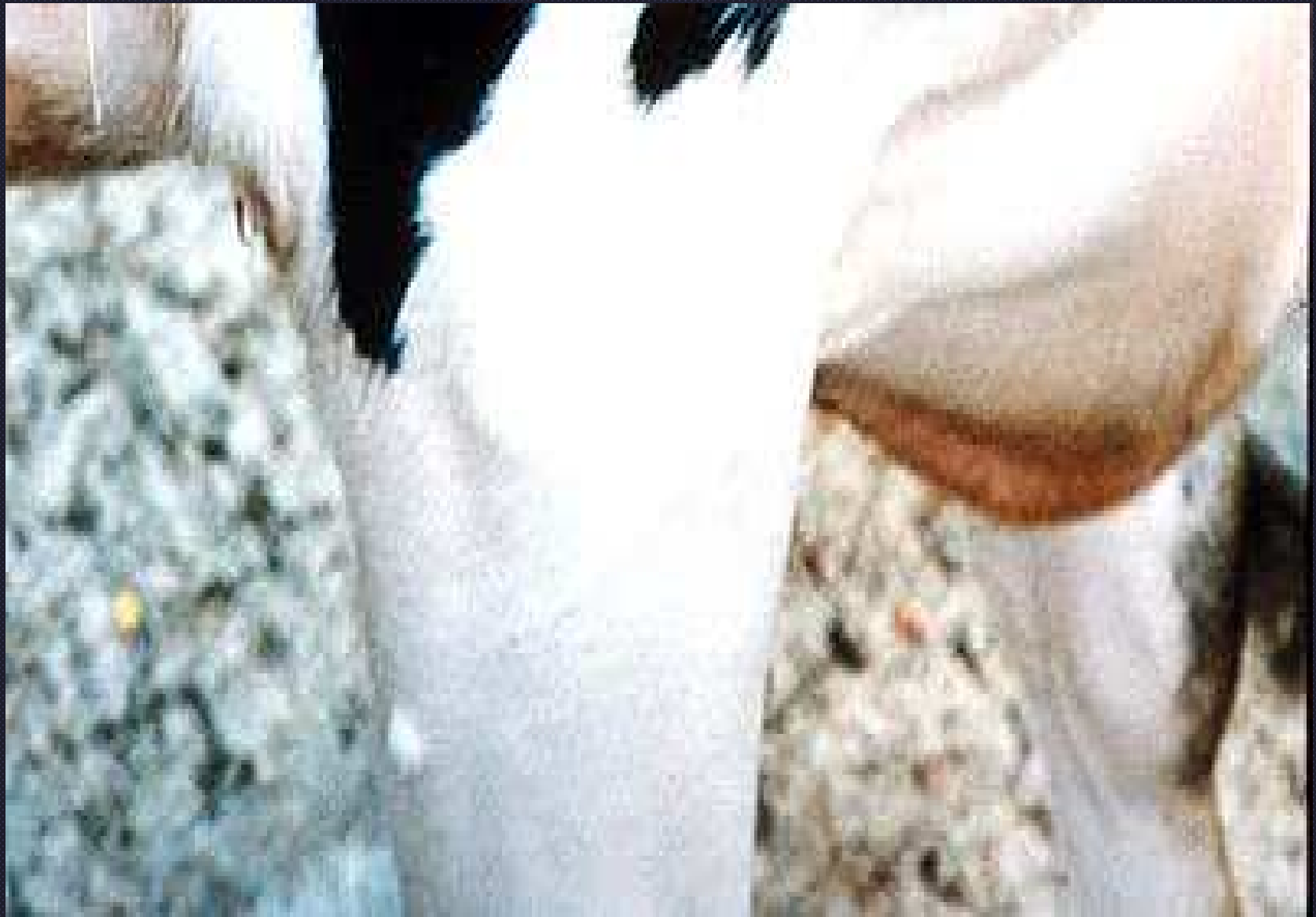

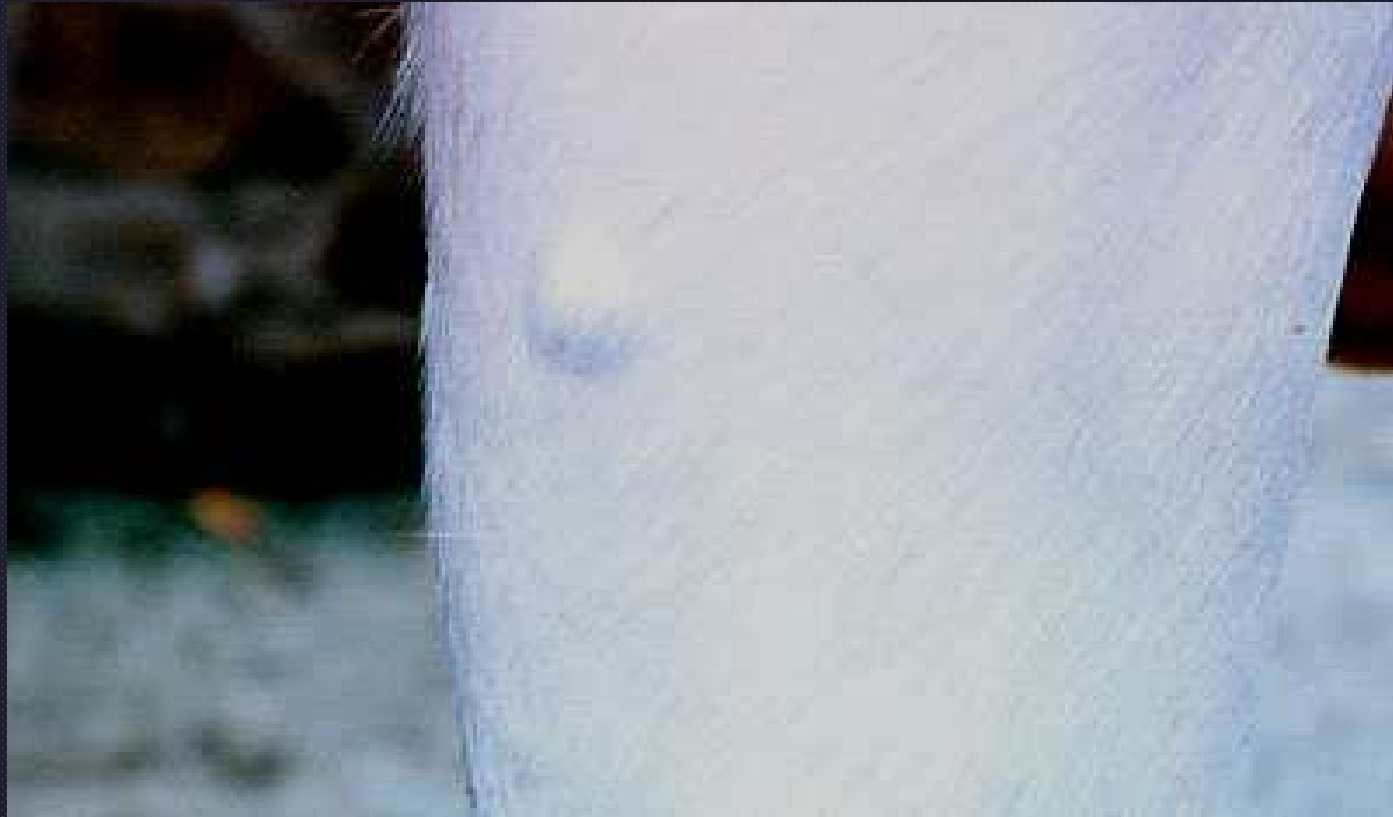Eosinophilic granulomas do occur in the interdigital skin and footpads but less common



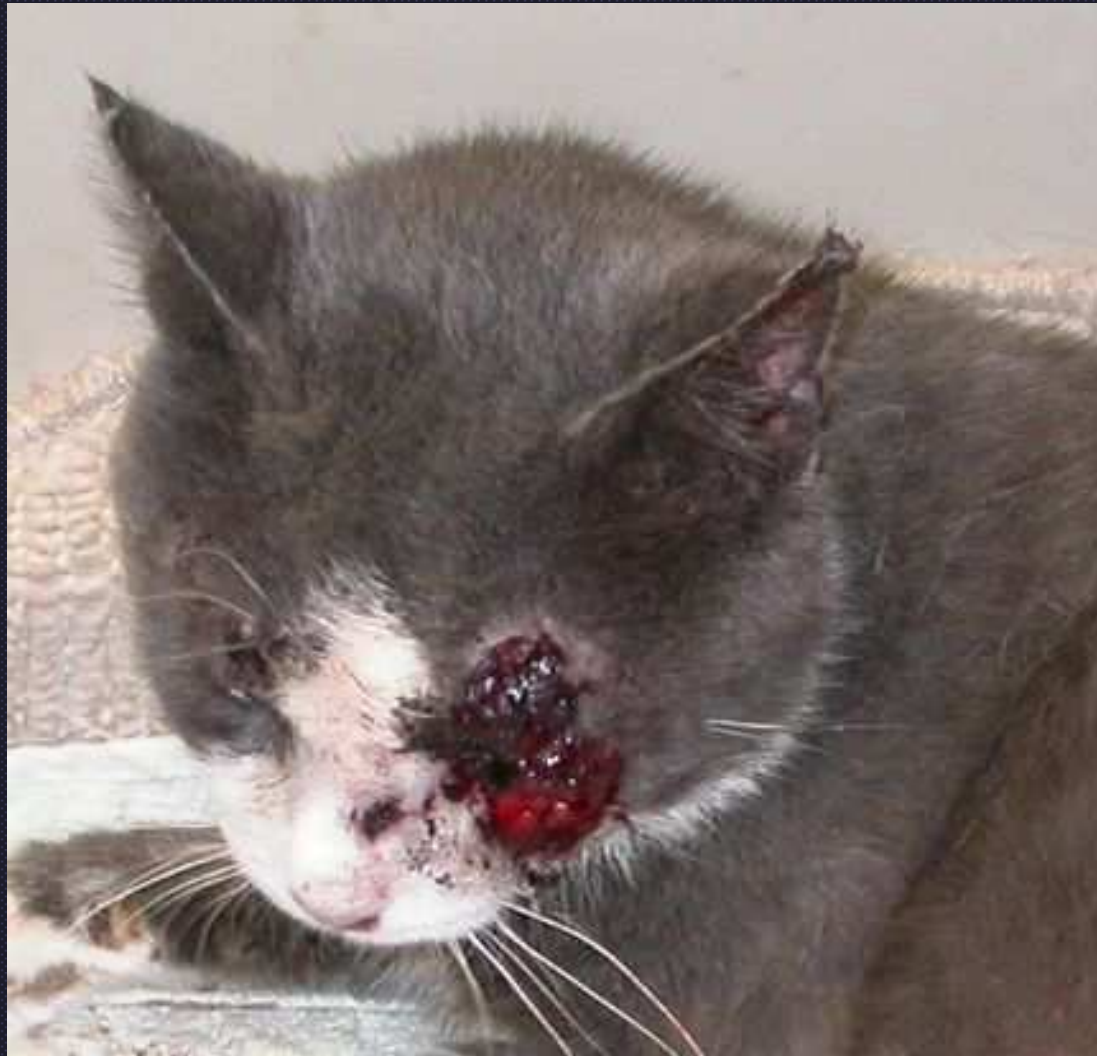Bovine demodicosis

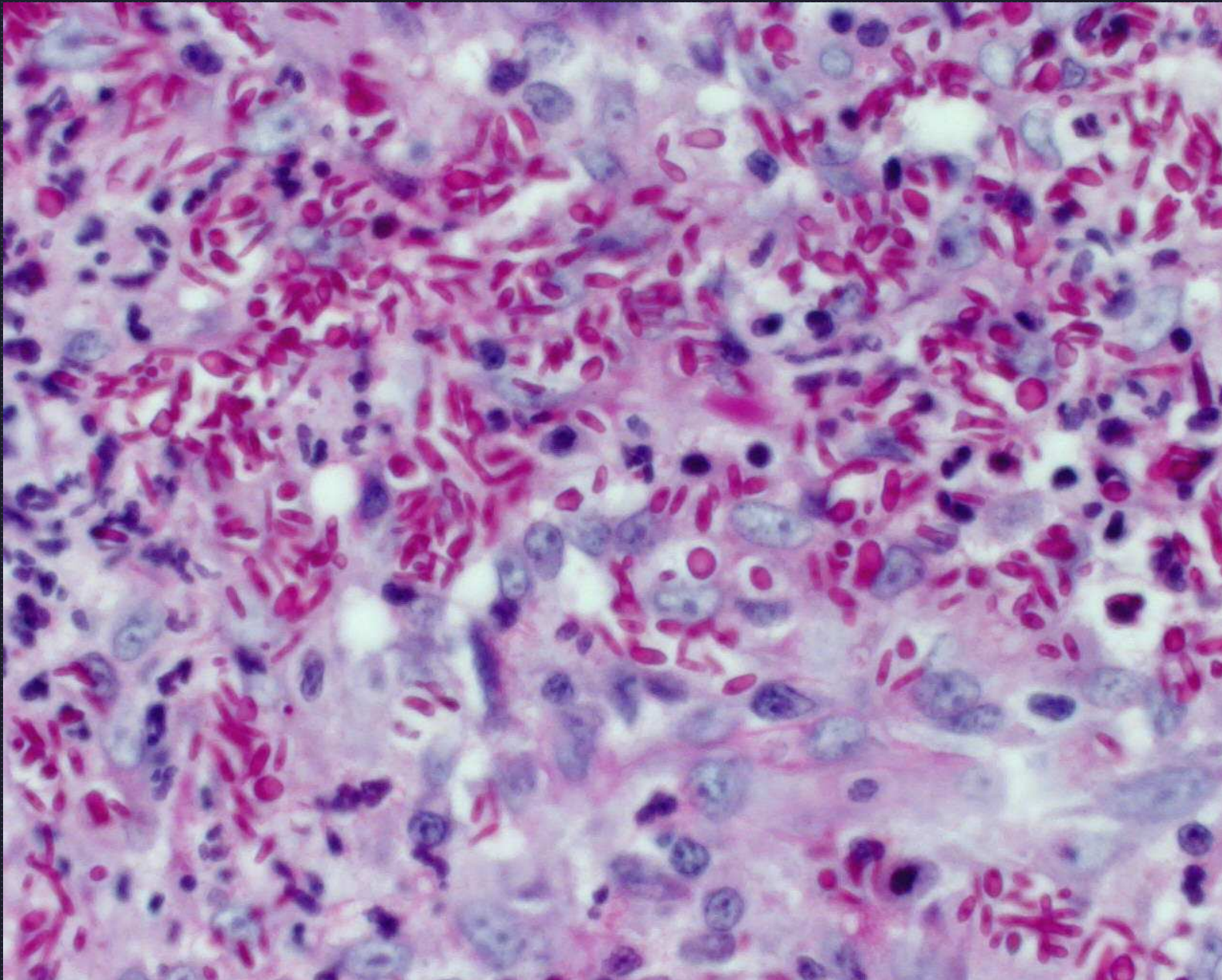




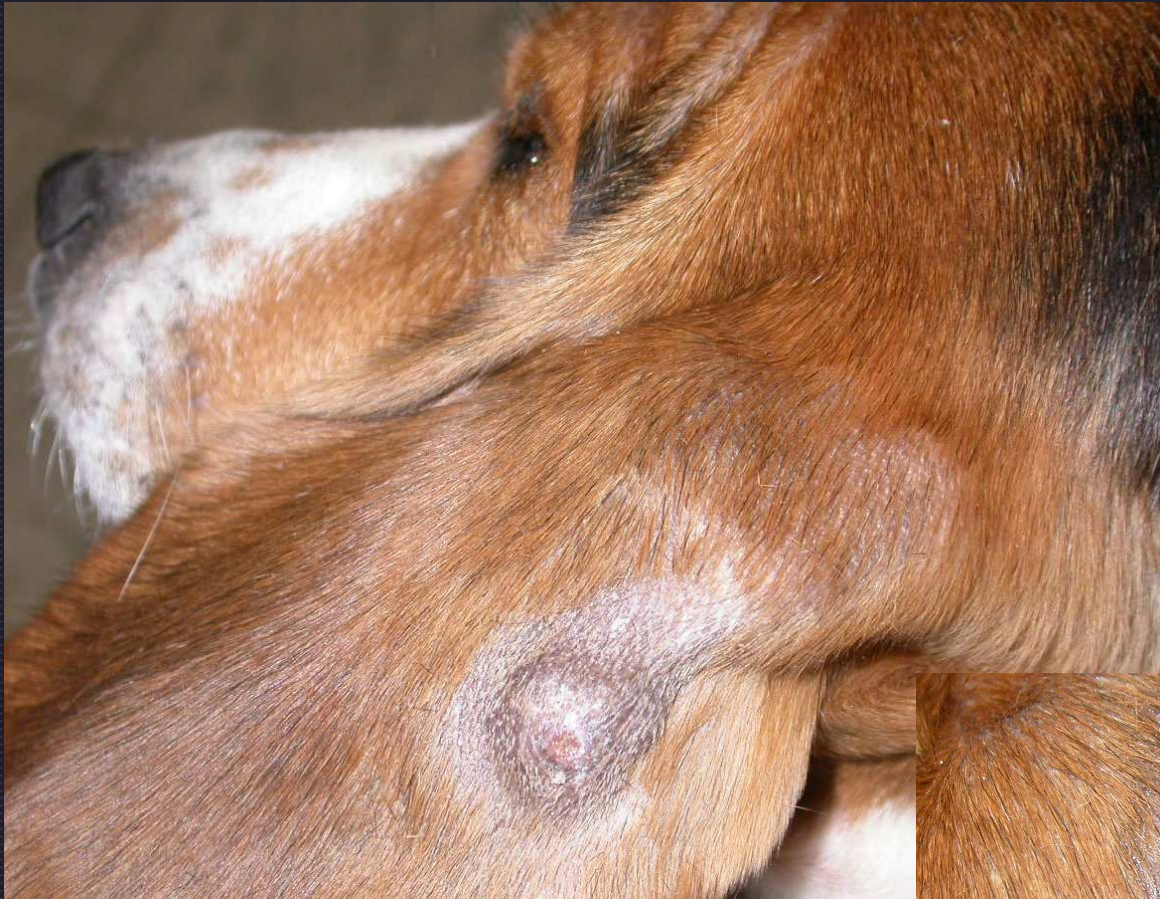

Sporotrichosis

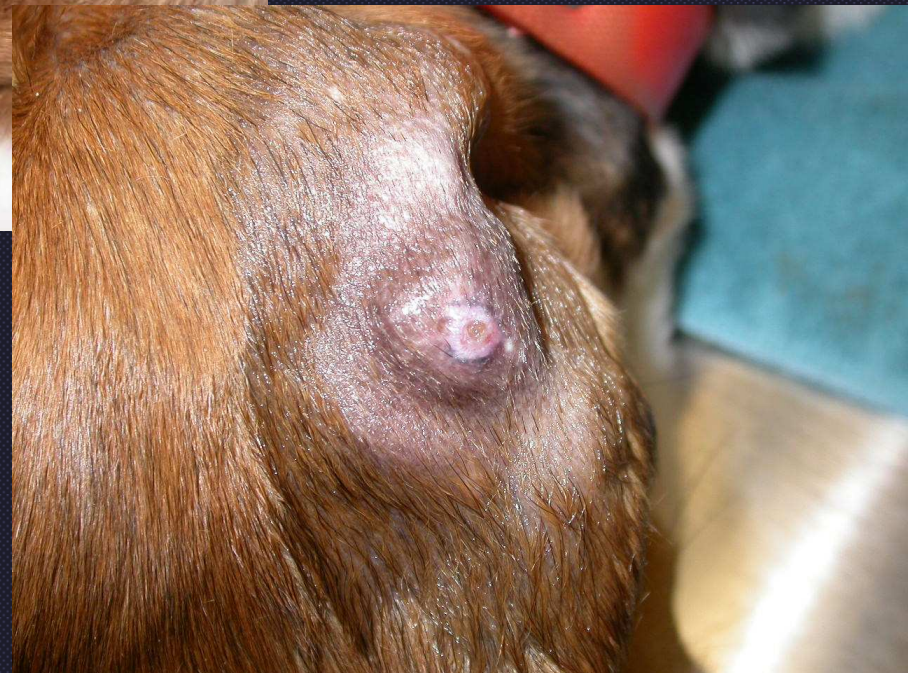


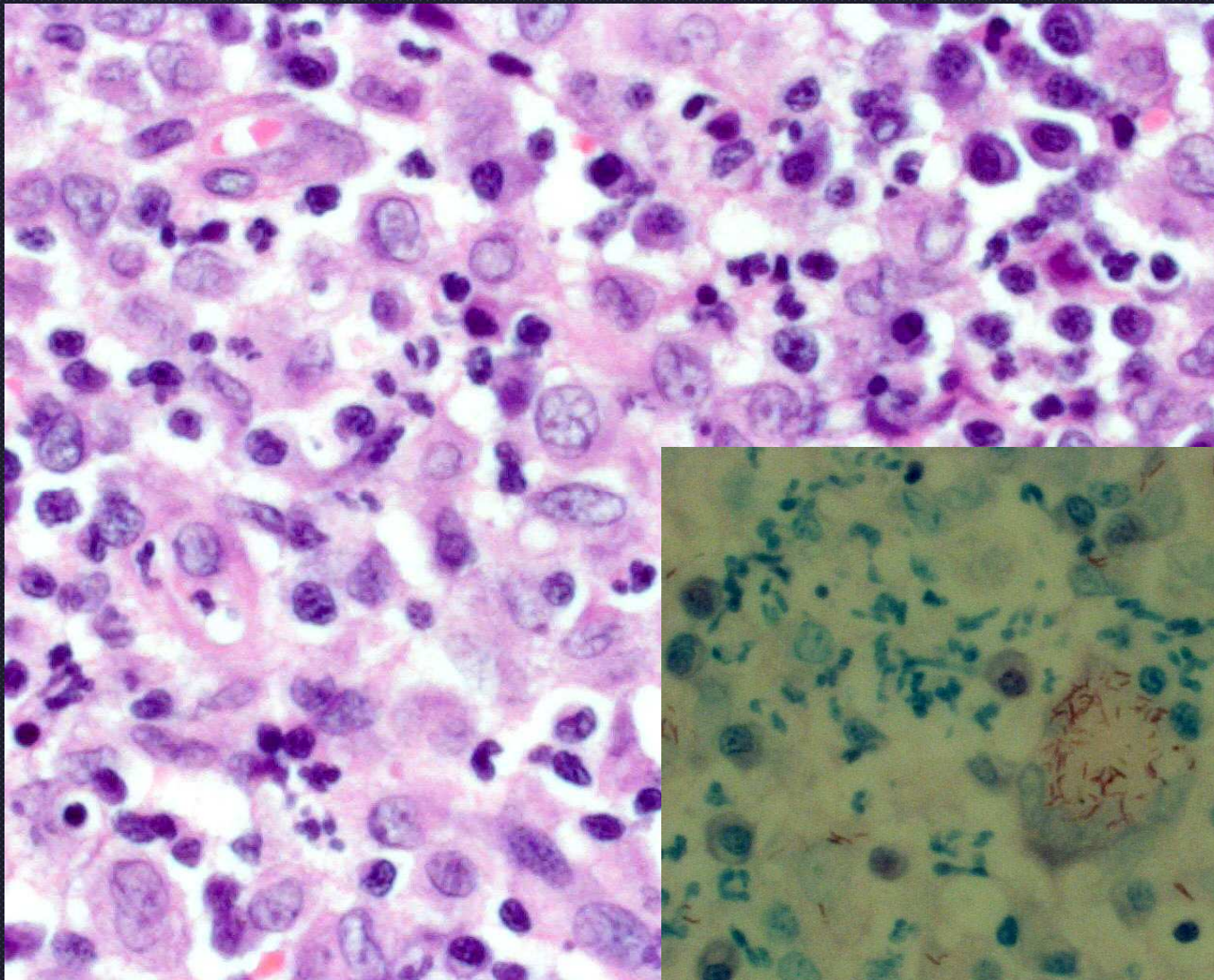


Sporotrichosis
PAS stain

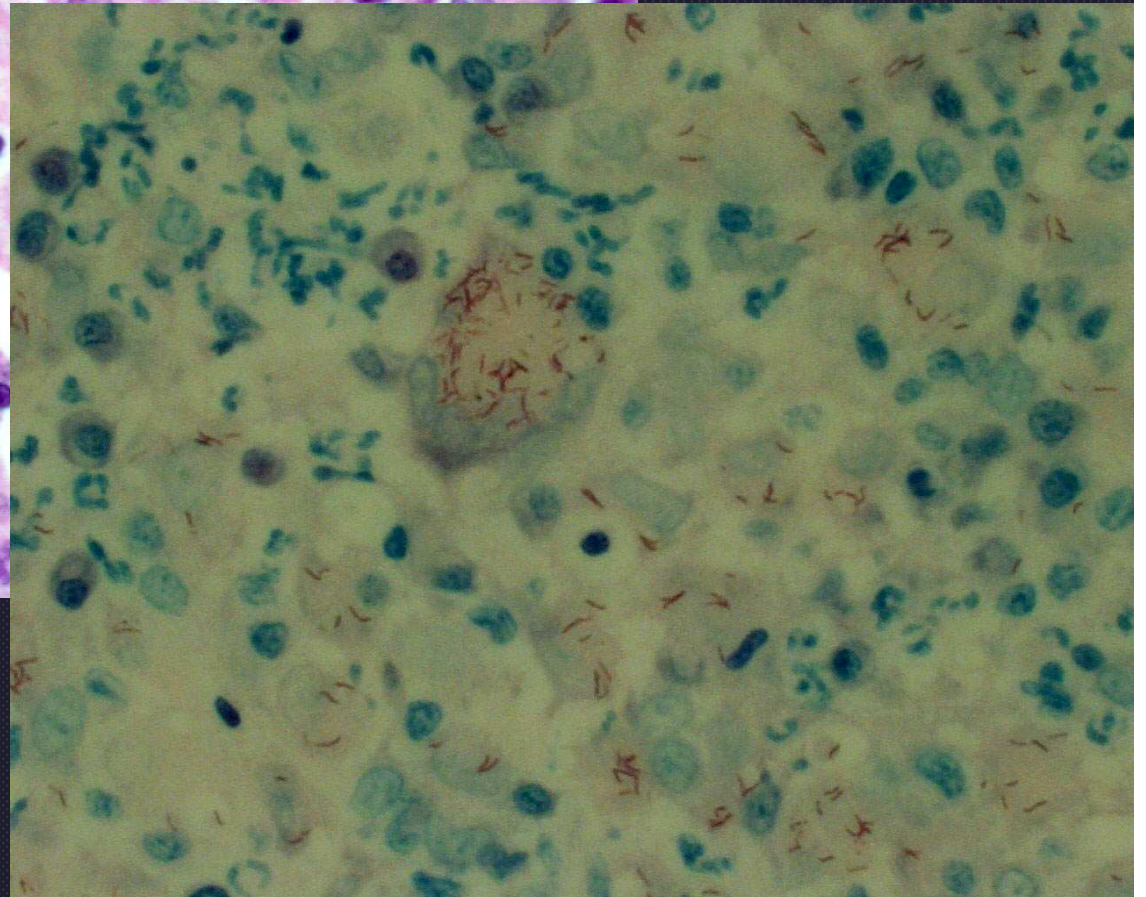


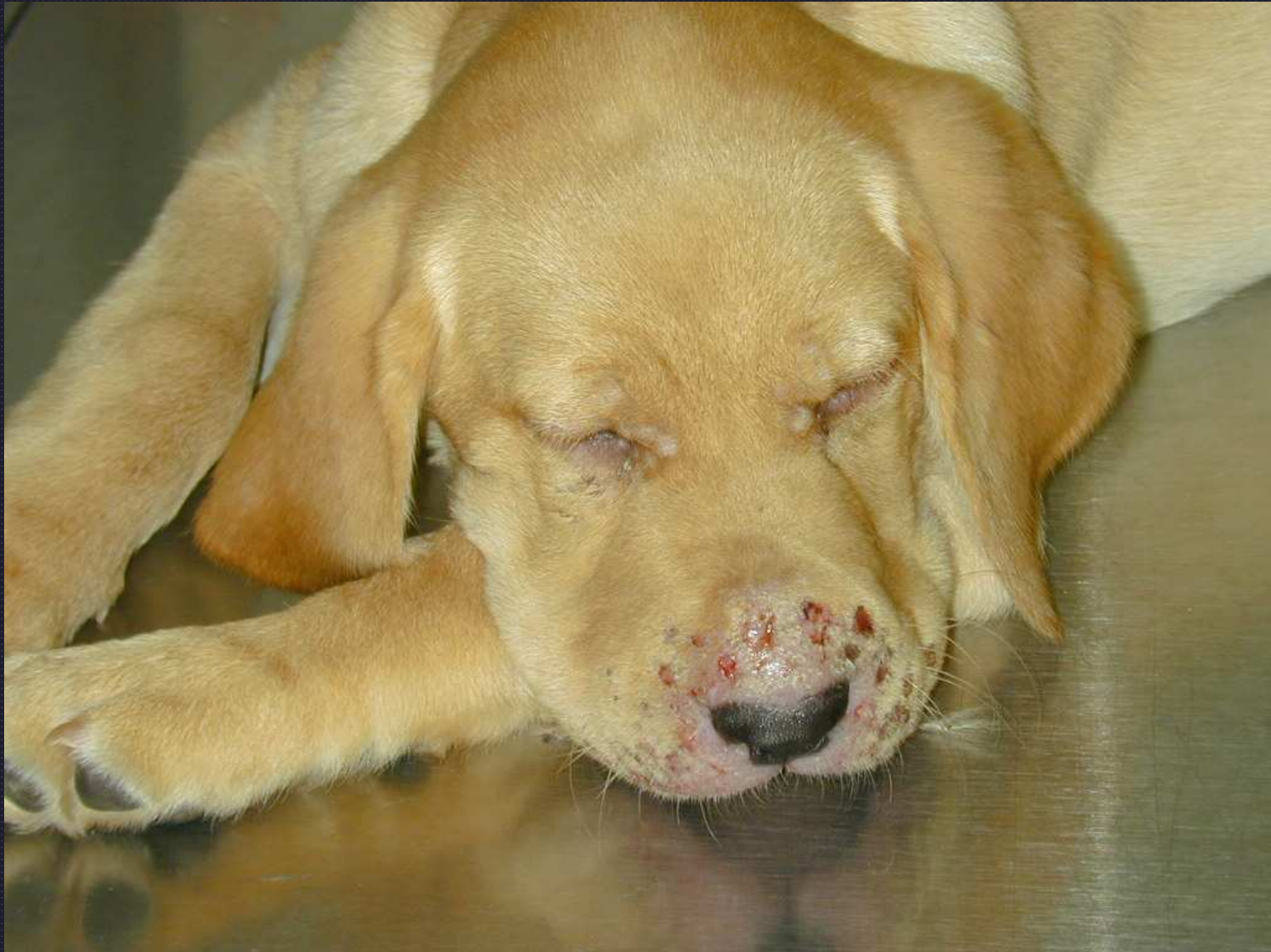Leproid granuloma in a hunting beagle





**Leproid
Granuloma**





Juvenile cellulitis