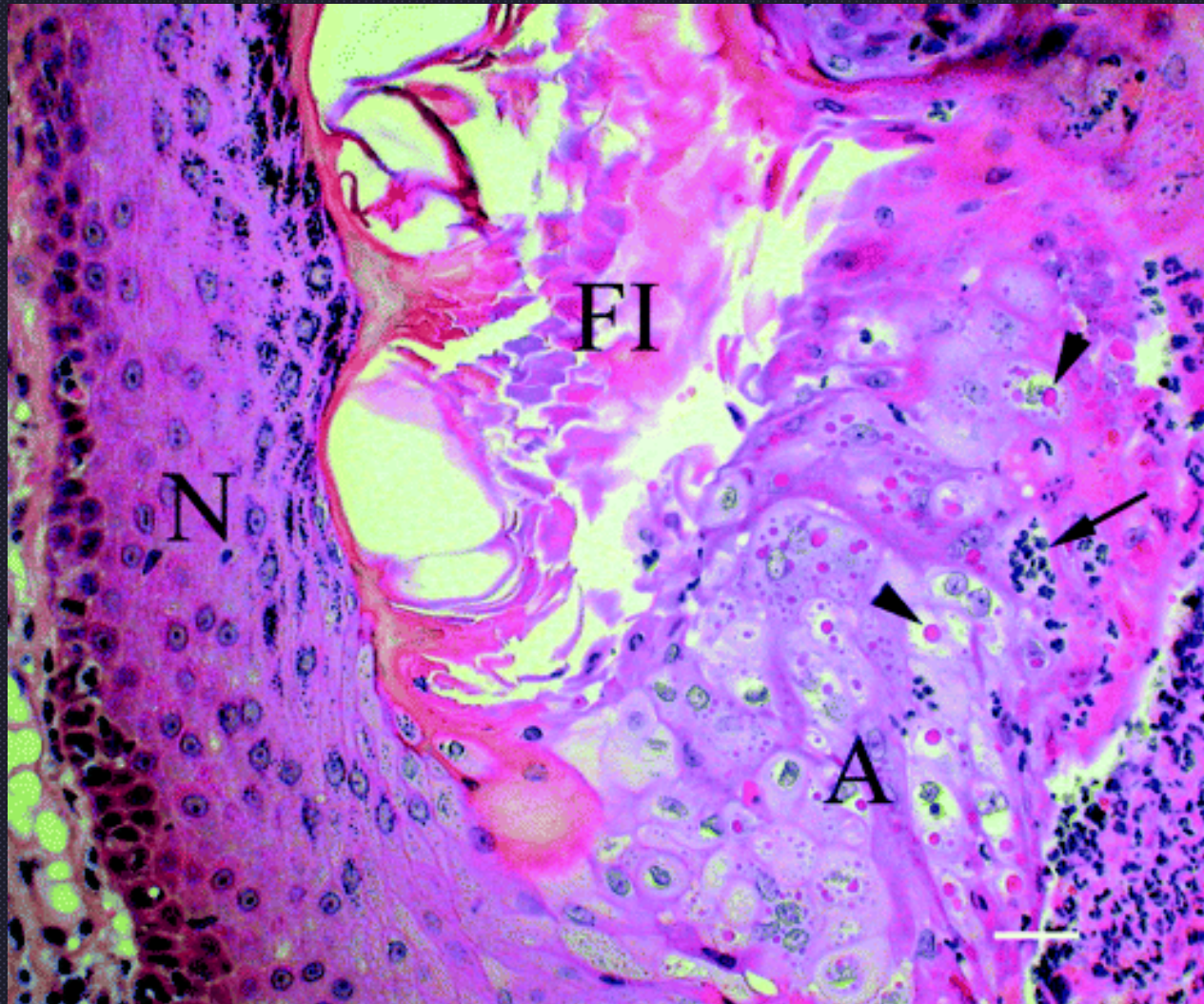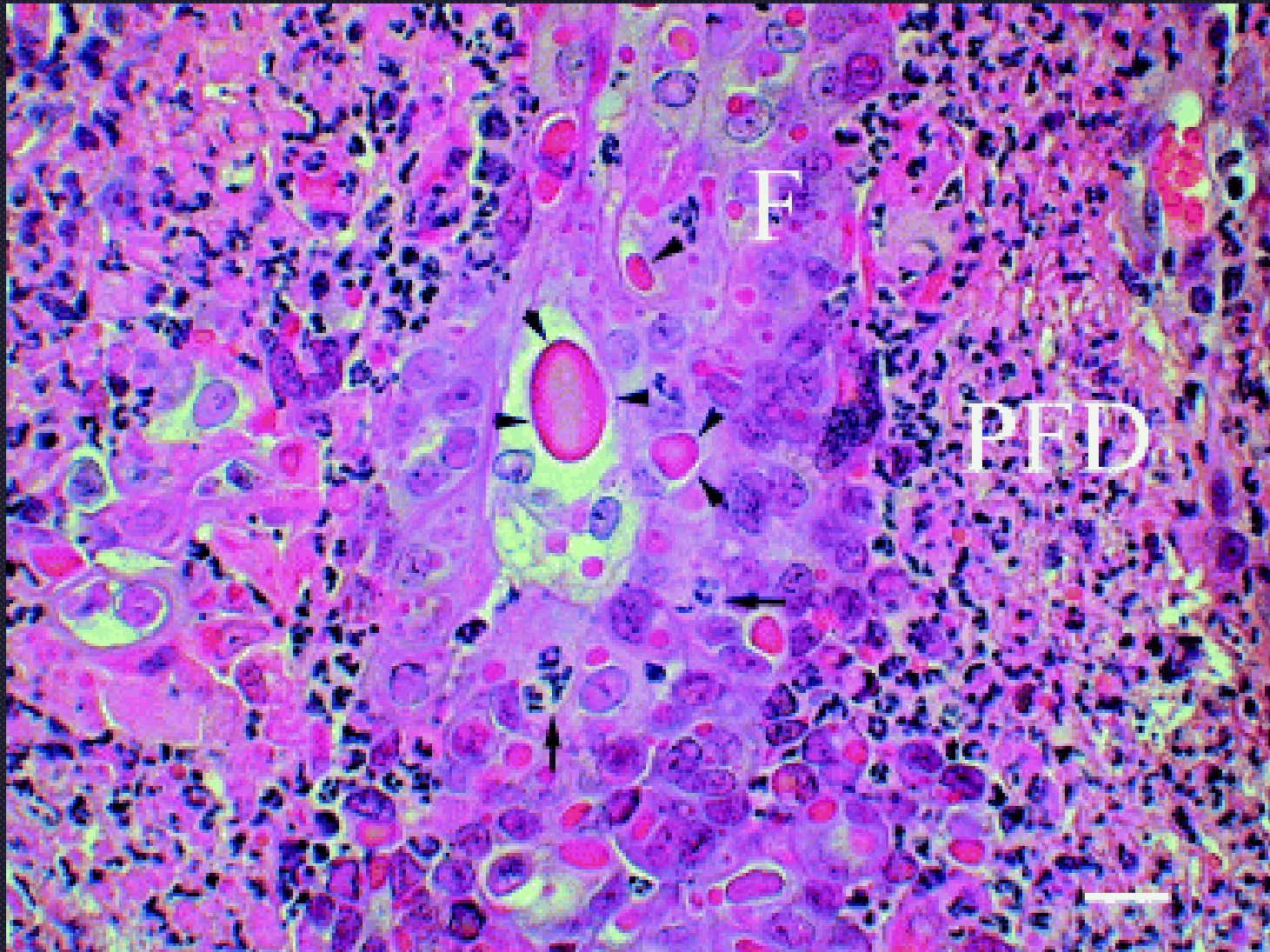
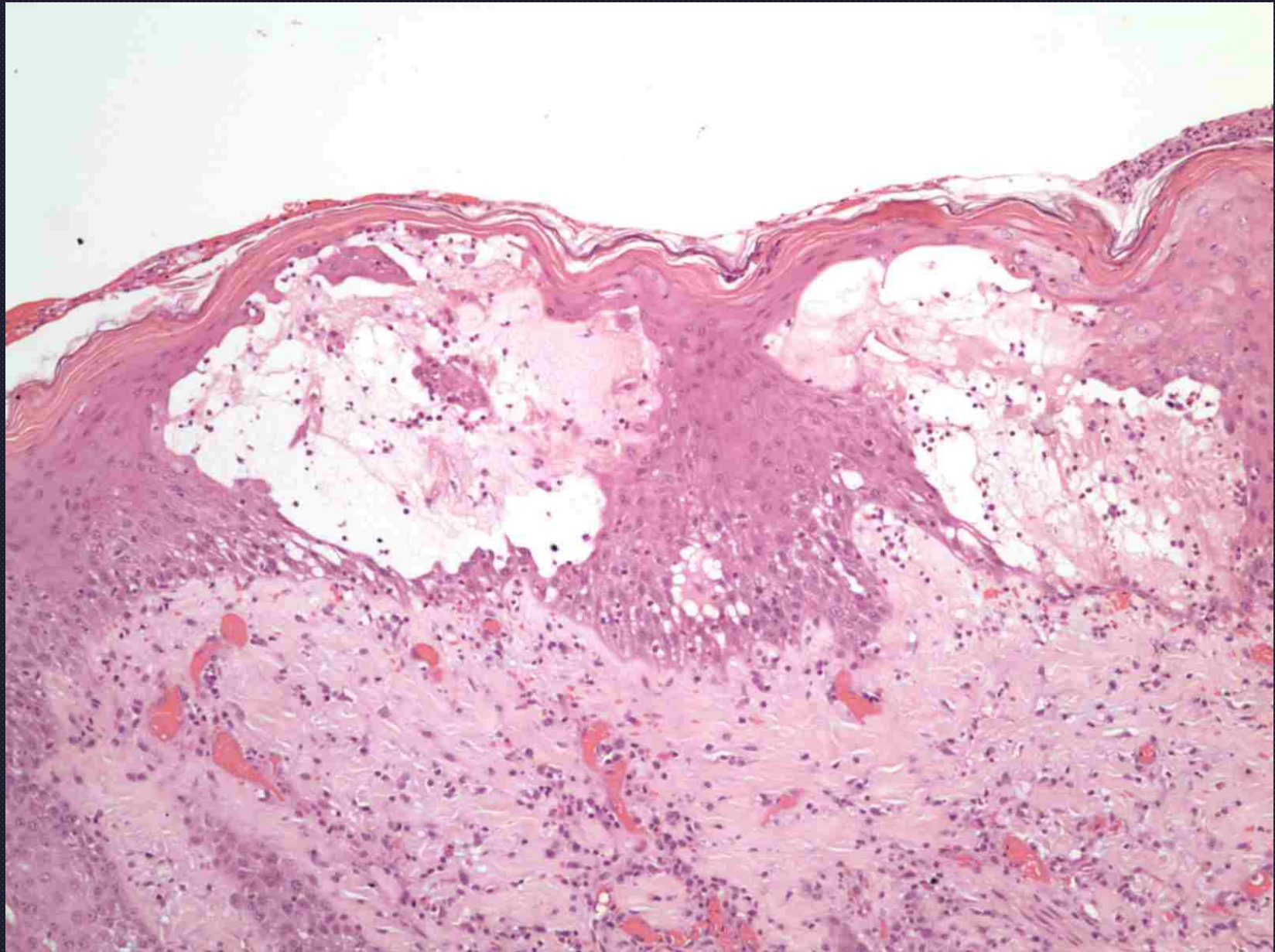


Yager, *et. al* Raccoon pox in a cat *Vet Derm* 2006



Yager, *et. al* Raccoon pox in a cat *Vet Derm* 2006




Spongiotic vesicular dermatitis in a horse
Note the mild acantholysis

Courtesy of Ann Hargis



“orf”

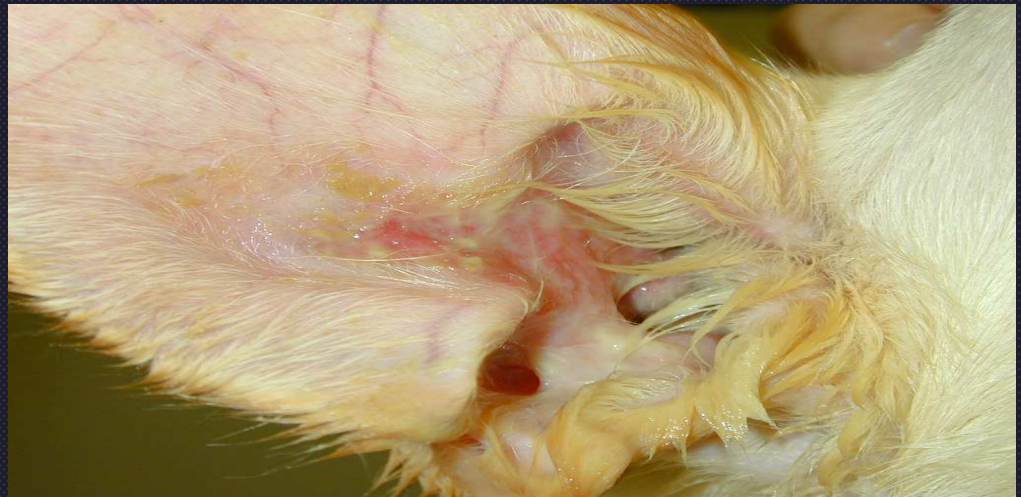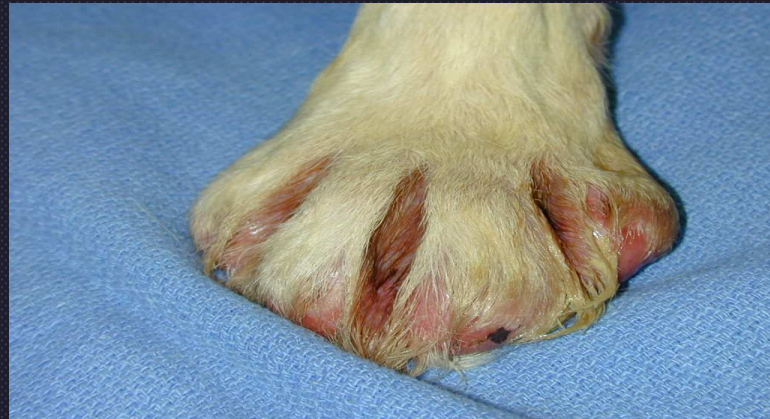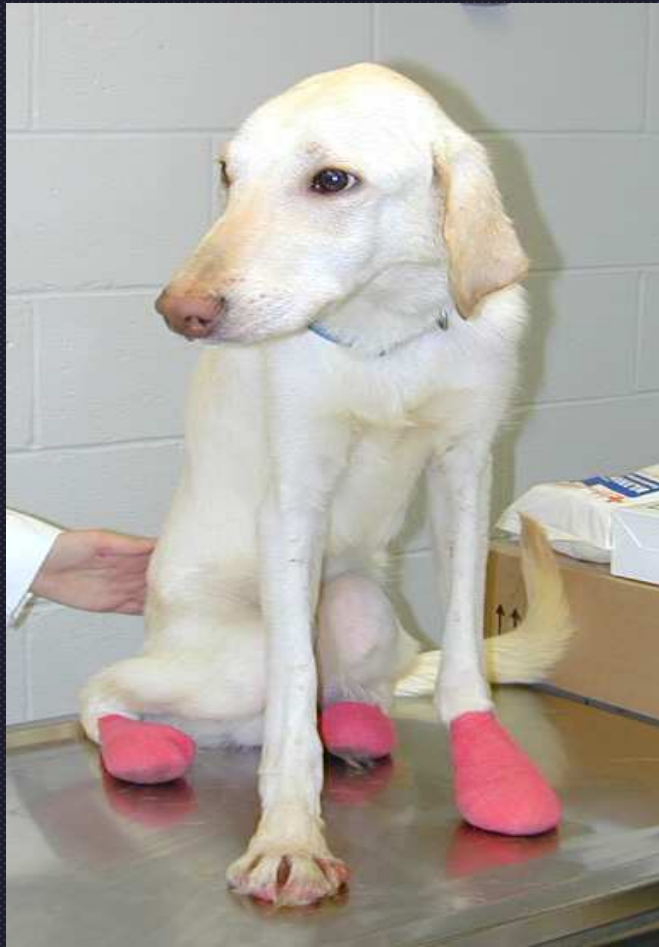Subepidermal vesicular dermatitis



Blistering Disorders of the BMZ

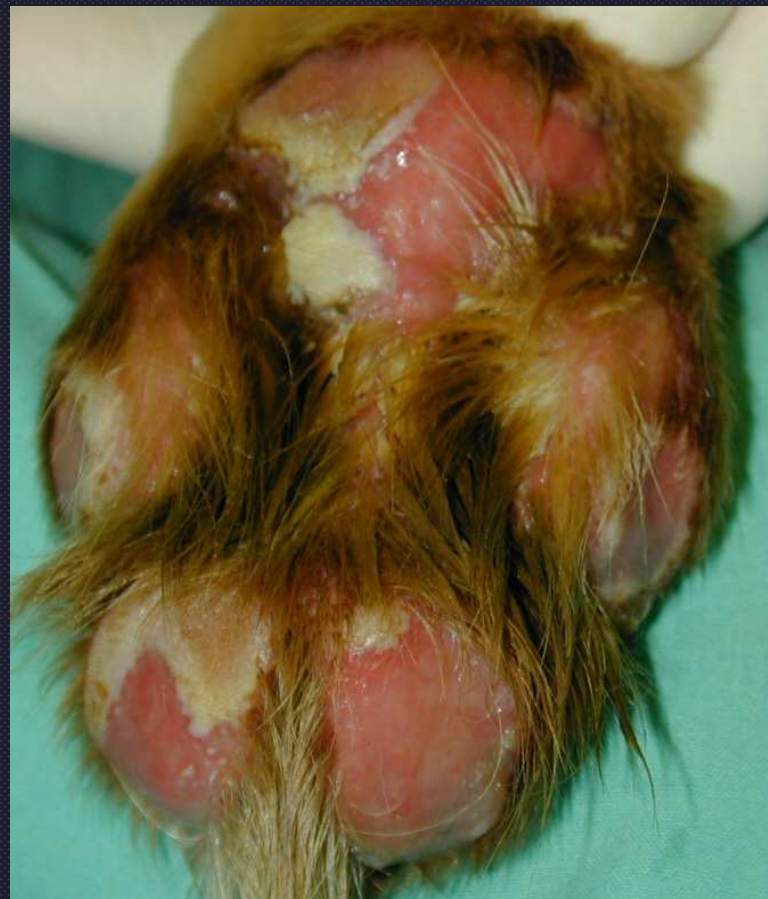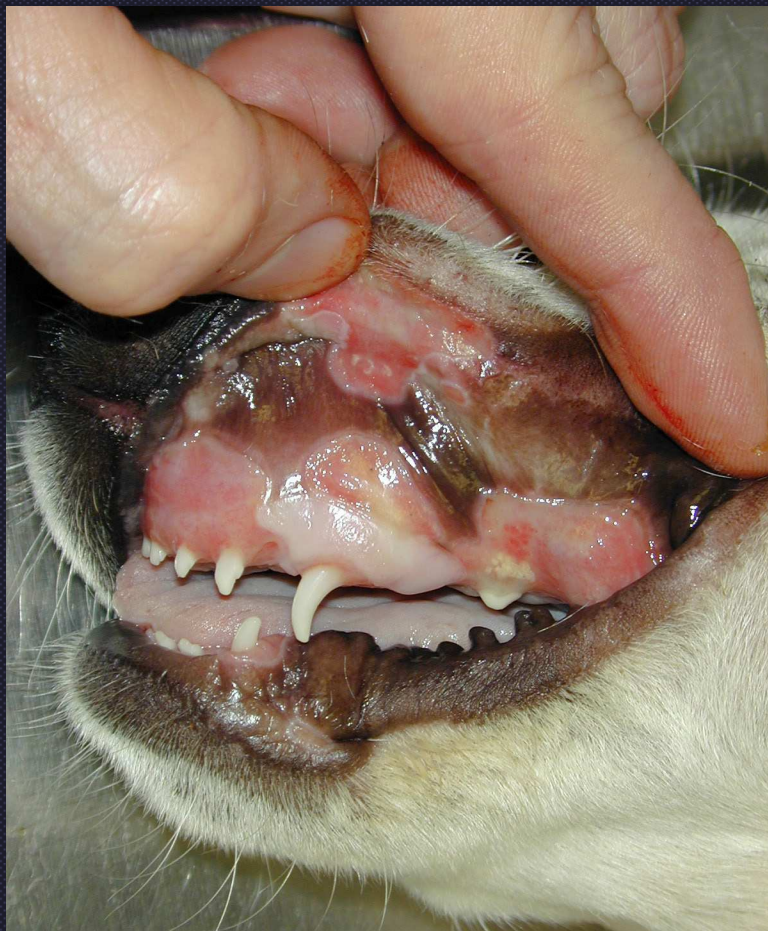- Autoab formation
 - Example: Bullous pemphigoid (OUT)
 - Mucous membrane pemphigoid (IN)
- Congenital Defect
 - Epidermolysis bullosa
 - Junctional- affects lamina lucida
 - Dystrophic- affects anchoring fibrils

Junctional Epidermolysis Bullosa

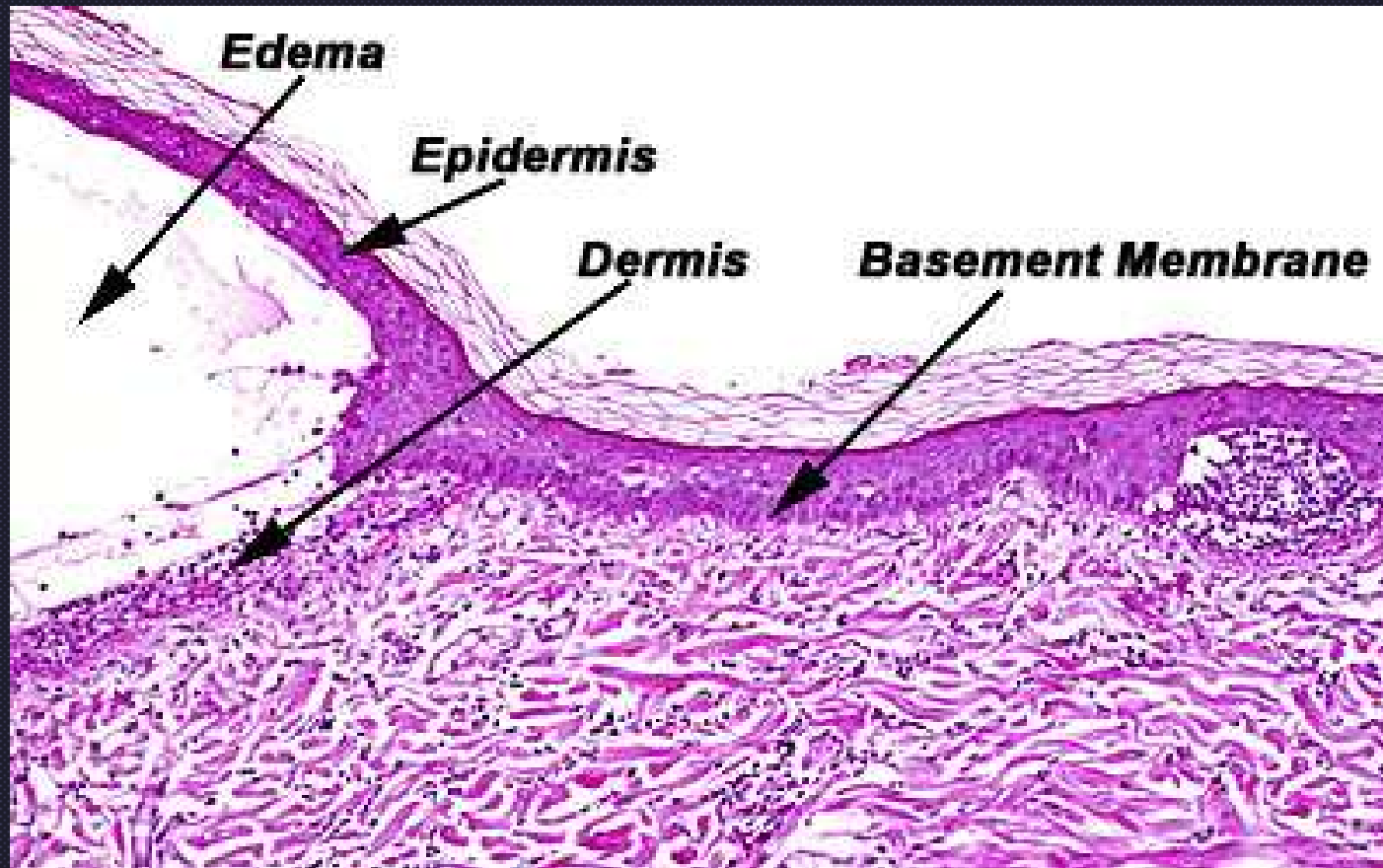


Congenital- autosomal recessive

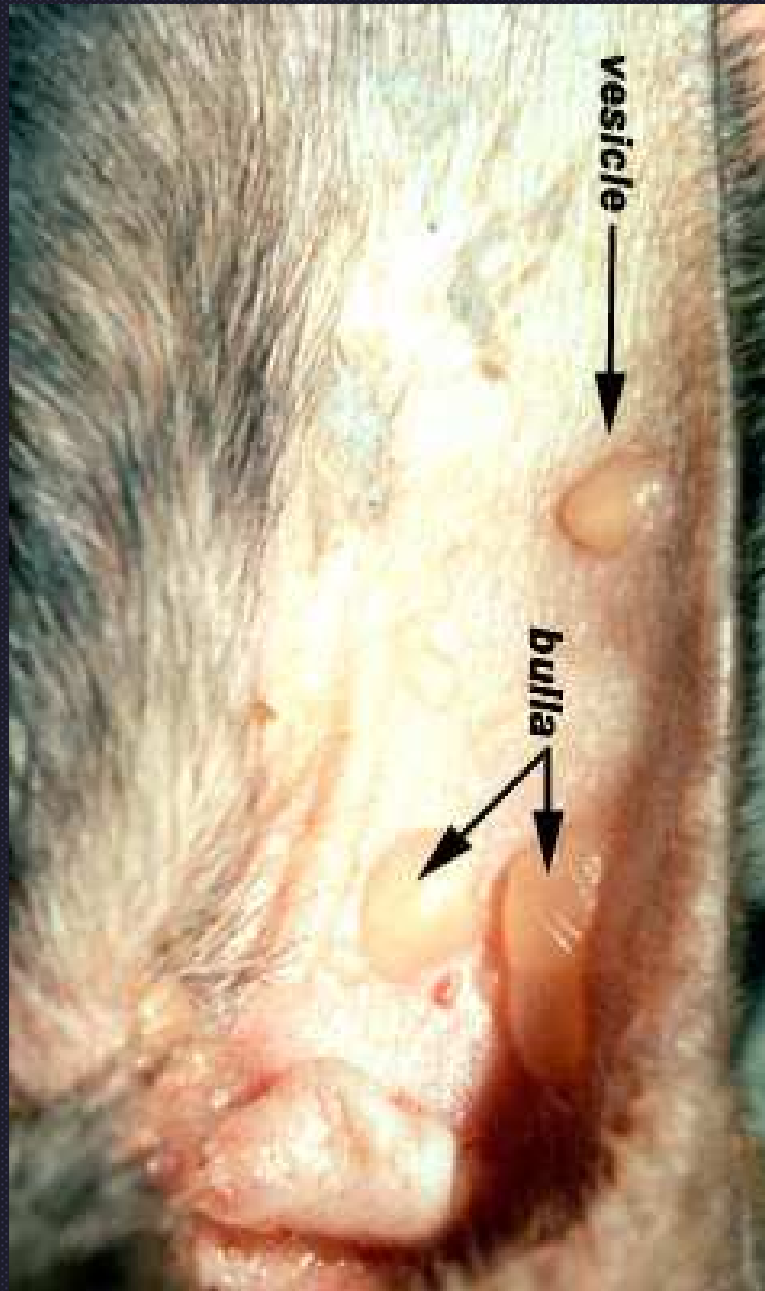
Junctional Epidermolysis Bullosa



Epidermolysis Bullosa Acquista



Acquired auto ab to collagen VII



Epidermolysis bullosa aquista in a Great Dane

Nodular/Diffuse Dermatitis



Character of Infiltrate

- (1) neutrophilic (e.g. bacterial)
- (2) eosinophilic (e.g. parasitic or eosinophilic granuloma)
- (3) histiocytic - chronic granulomatous or pyogranulomatous lesions (e.g. mycobacteria, fungal, foreign body)