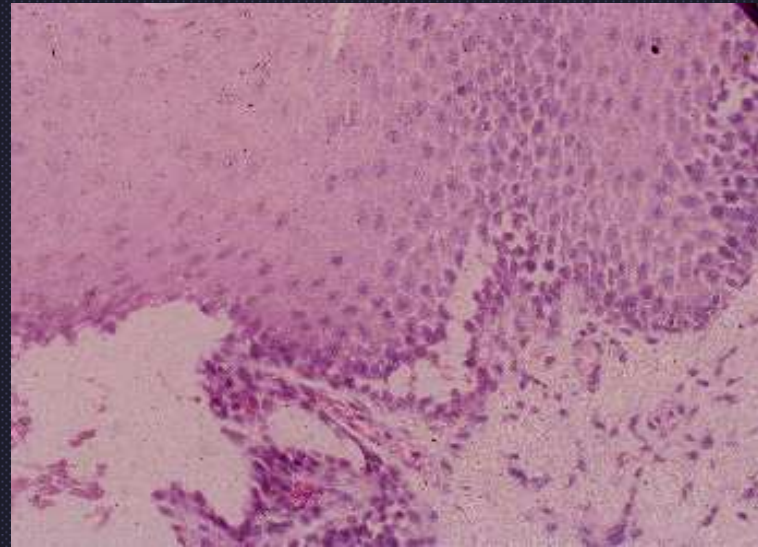



Be careful!

- Acantholytic dermatophytosis!
- When in doubt
- Do a PAS or GMS stain!!!



Pemphigus vulgaris

- Acantholysis with suprabasilar clefting
- Desmoglein-3 autoantibody
- Oral mucosa






Haired Skin



**Mucous
membrane**



Haired Skin

+

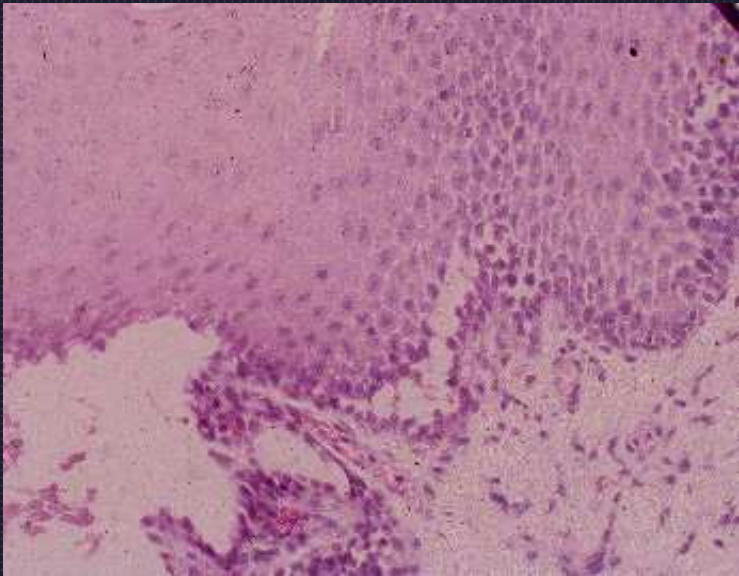
DSG1 ab



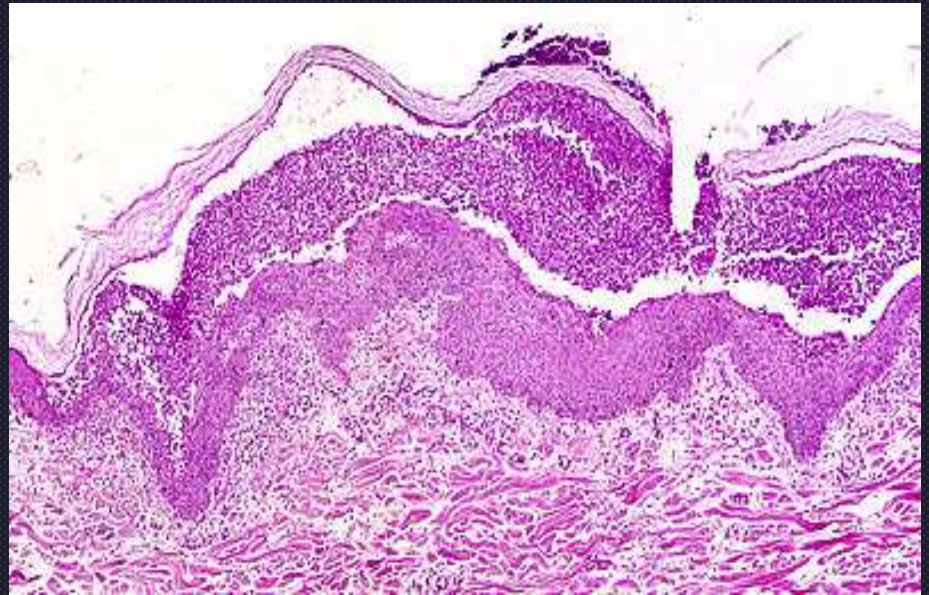
Mucous
membrane

+

DSG3 ab

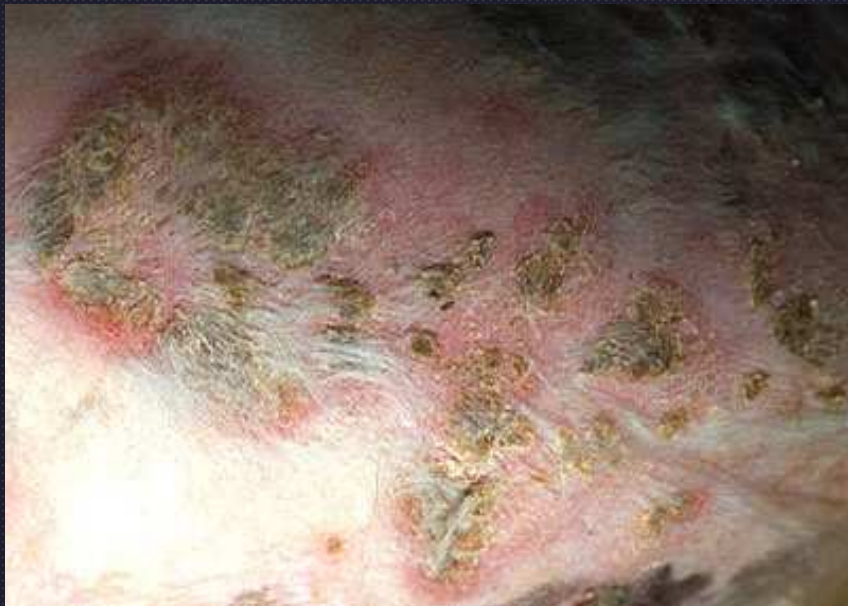

PV

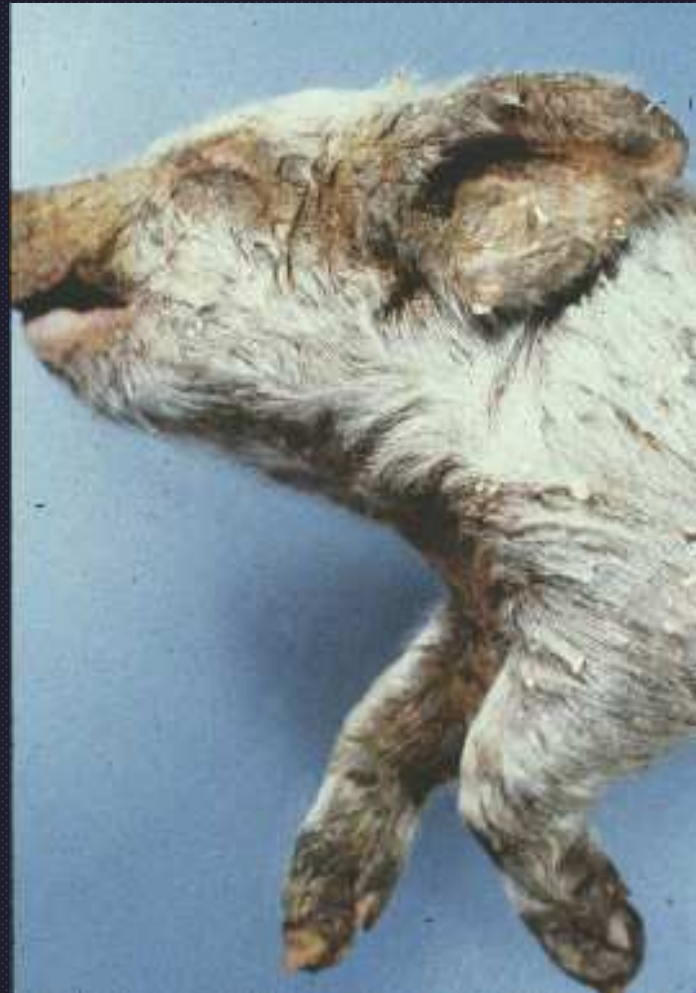

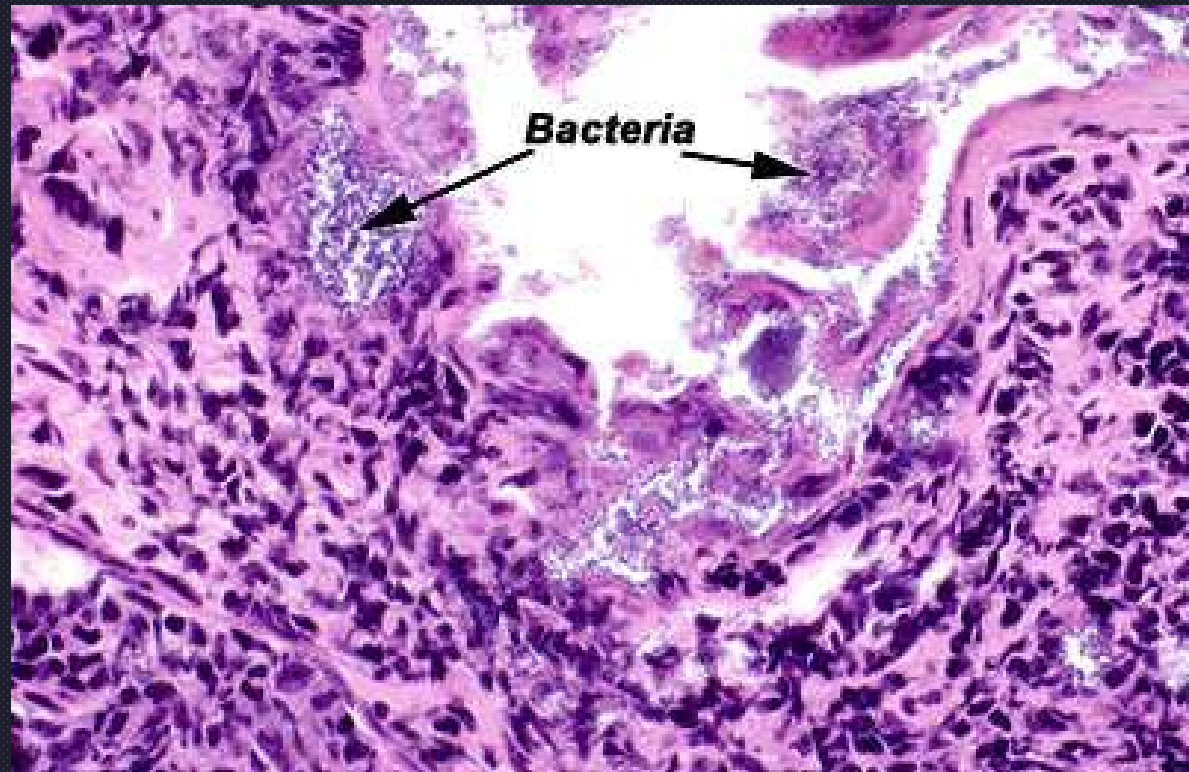
PF

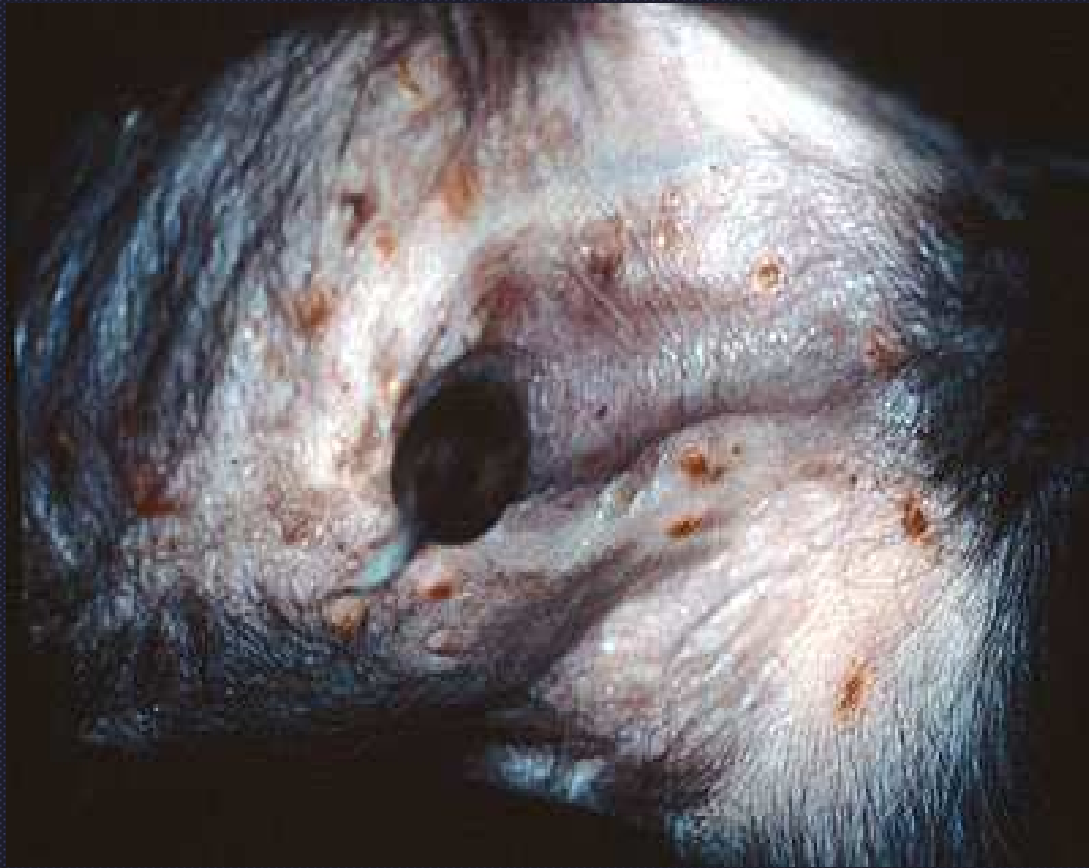Bacterial Disorders



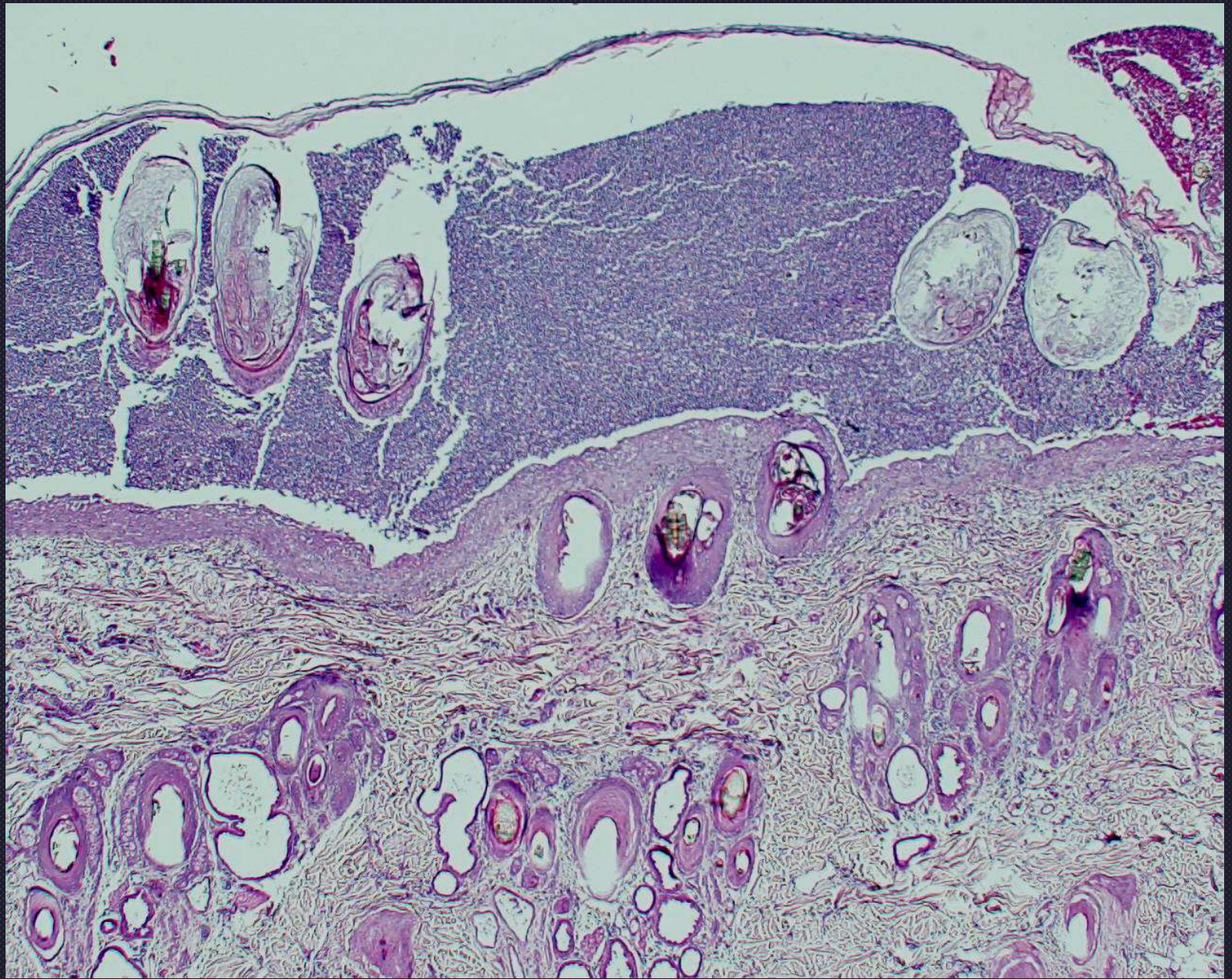
Greasy pig disease



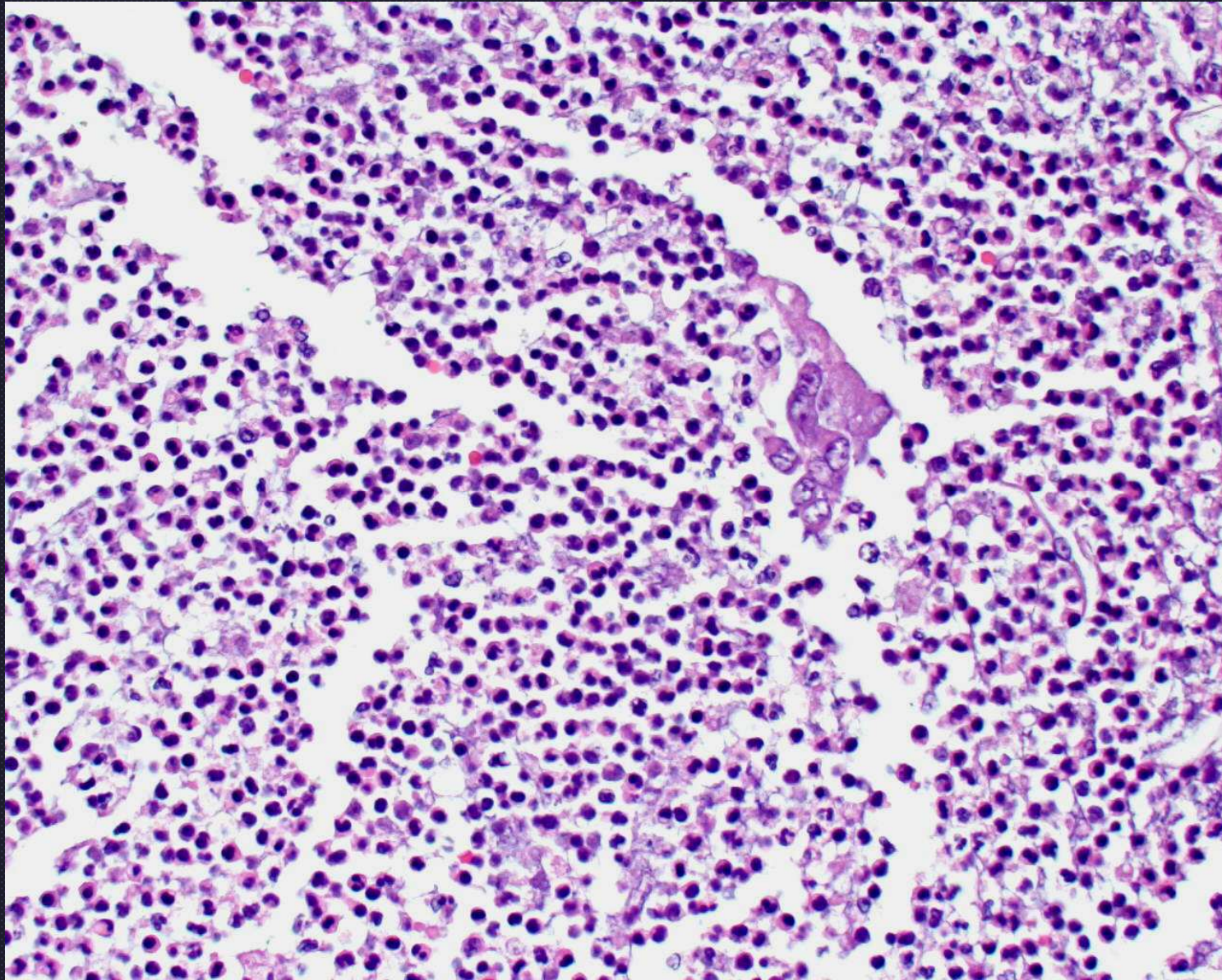




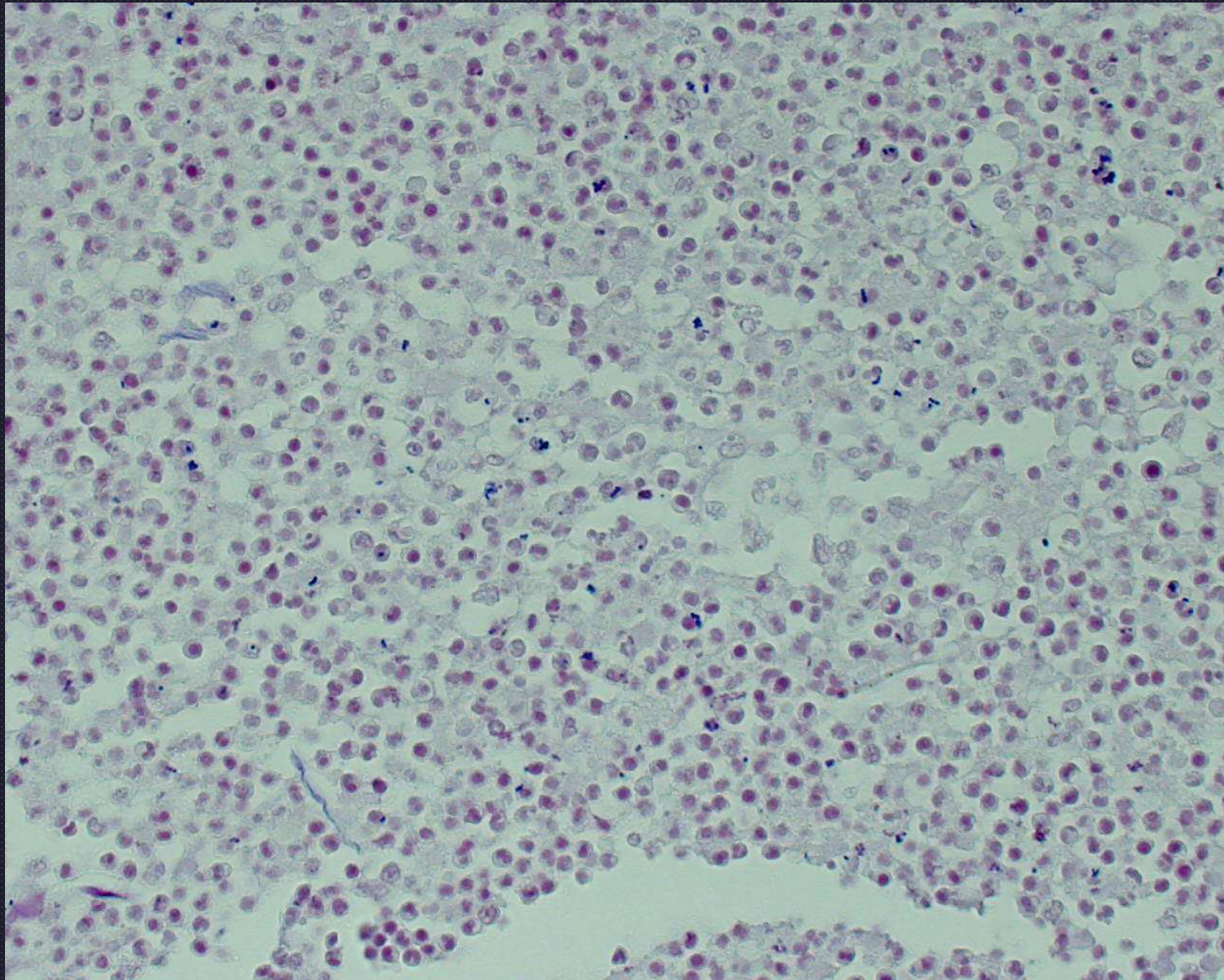
Small pustules on the abdomen of a puppy
“puppy pyoderma”



Bullous impetigo



You may find a few acantholytic cells; degenerate PMNs, cocci
Bullous impetigo



Gram positive cocci
Bullous impetigo