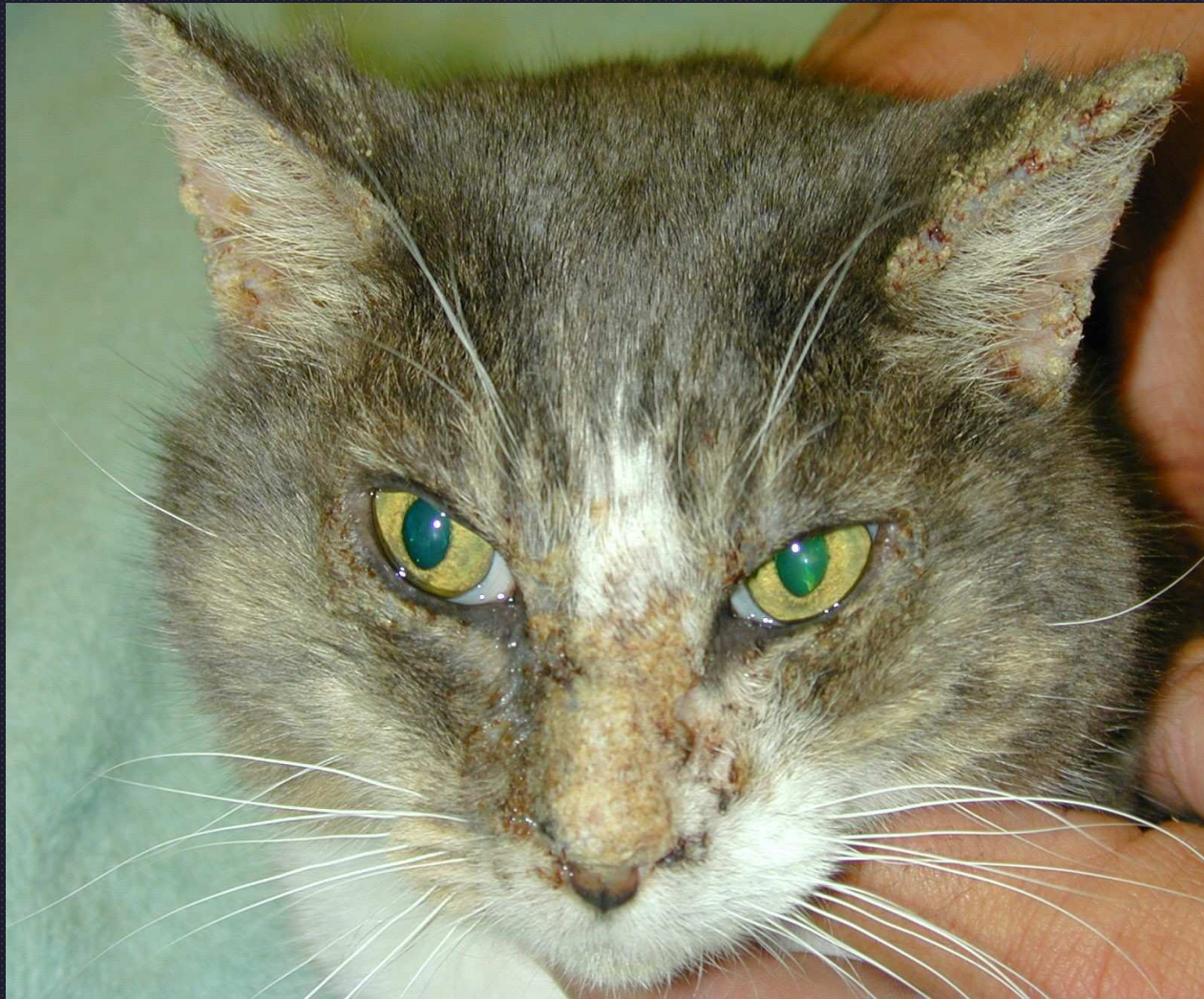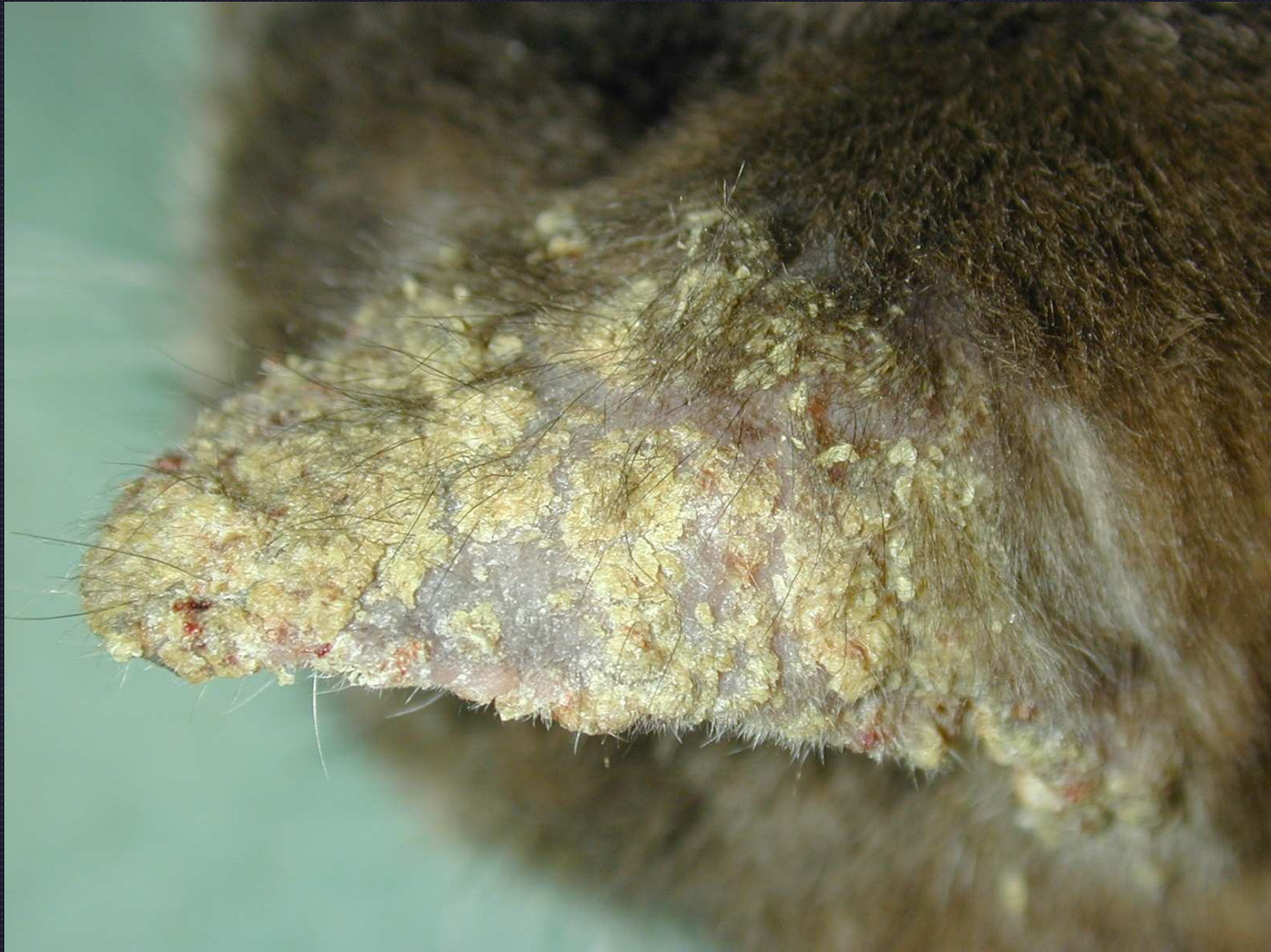
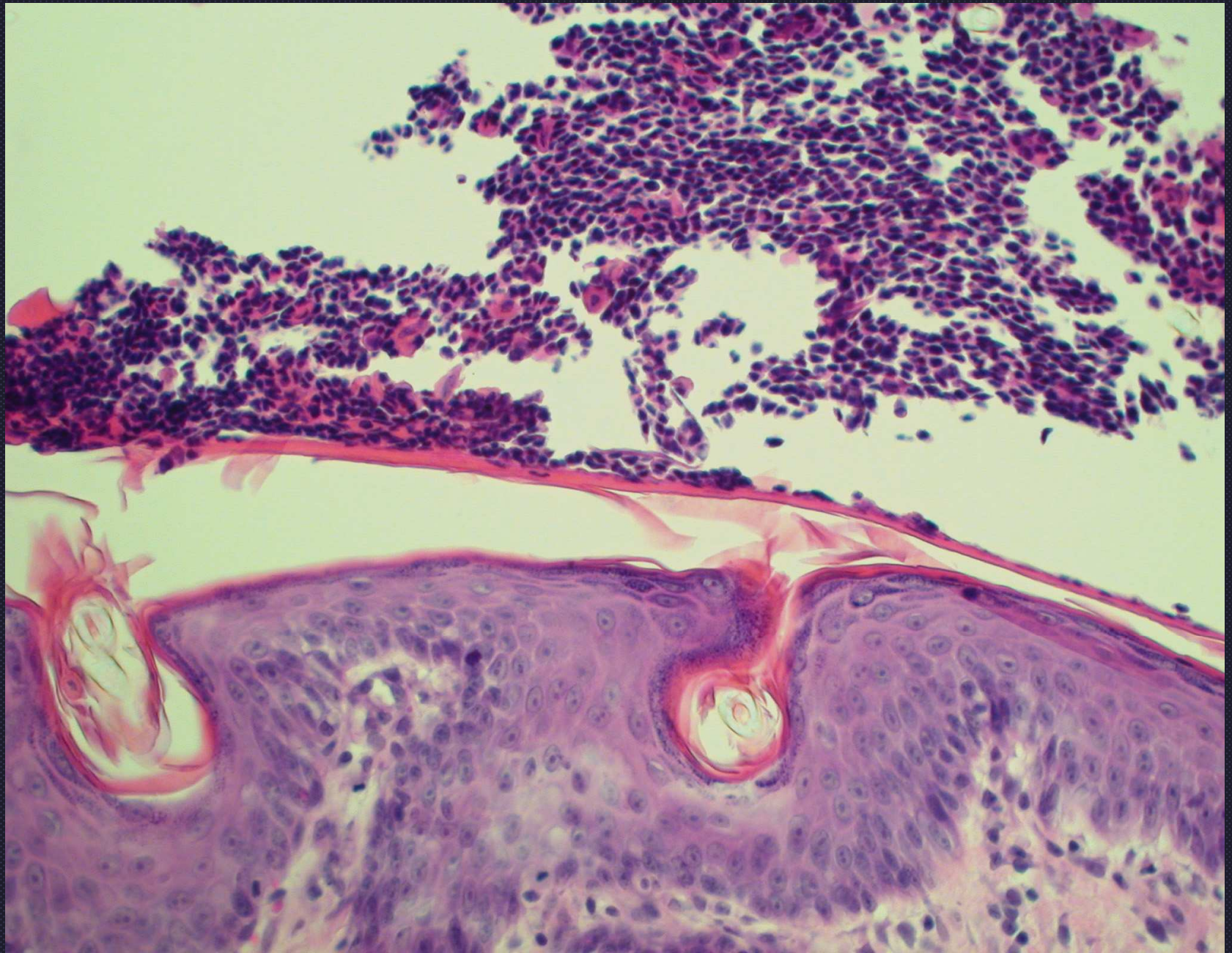


Feline Pemphigus Foliaceus

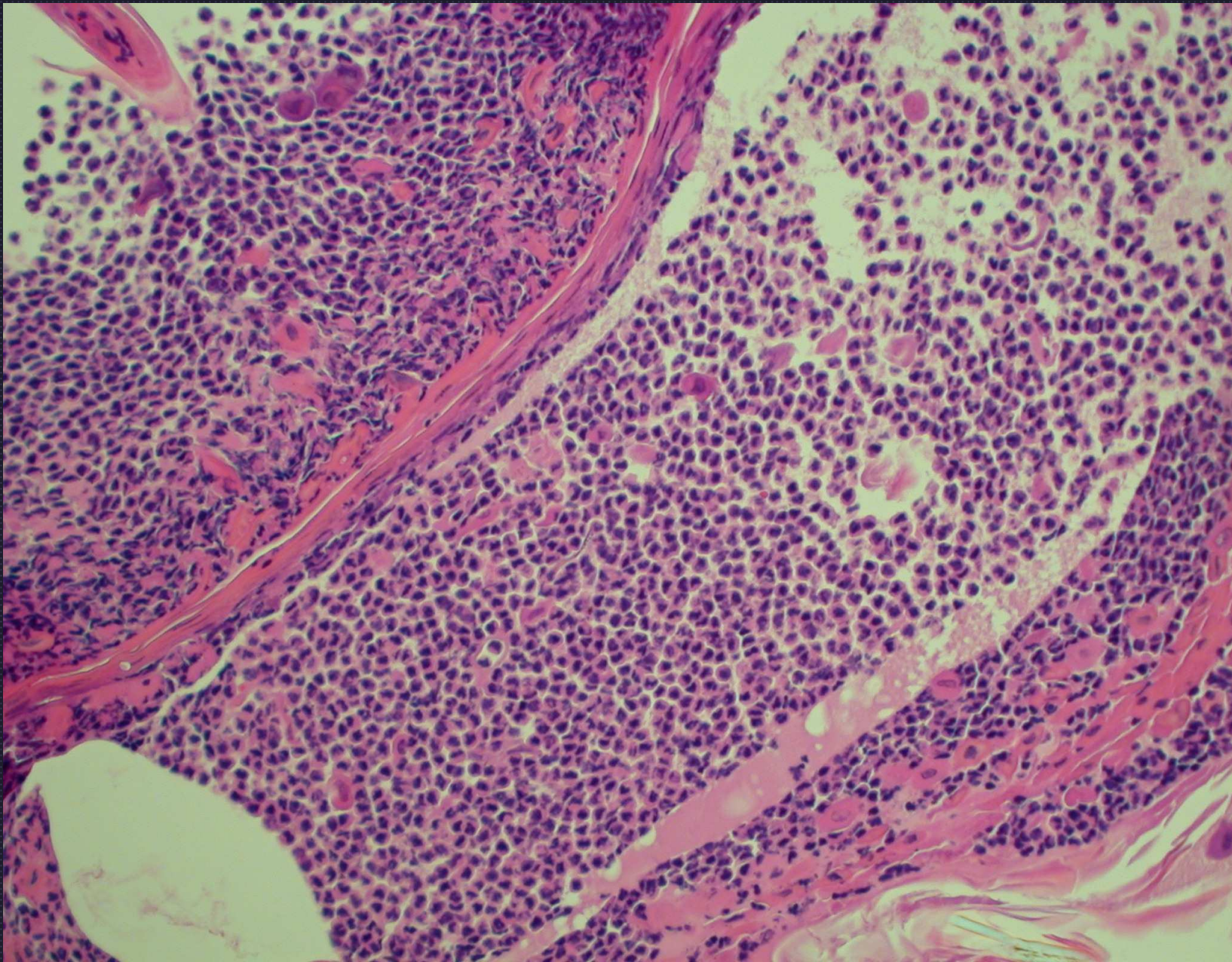




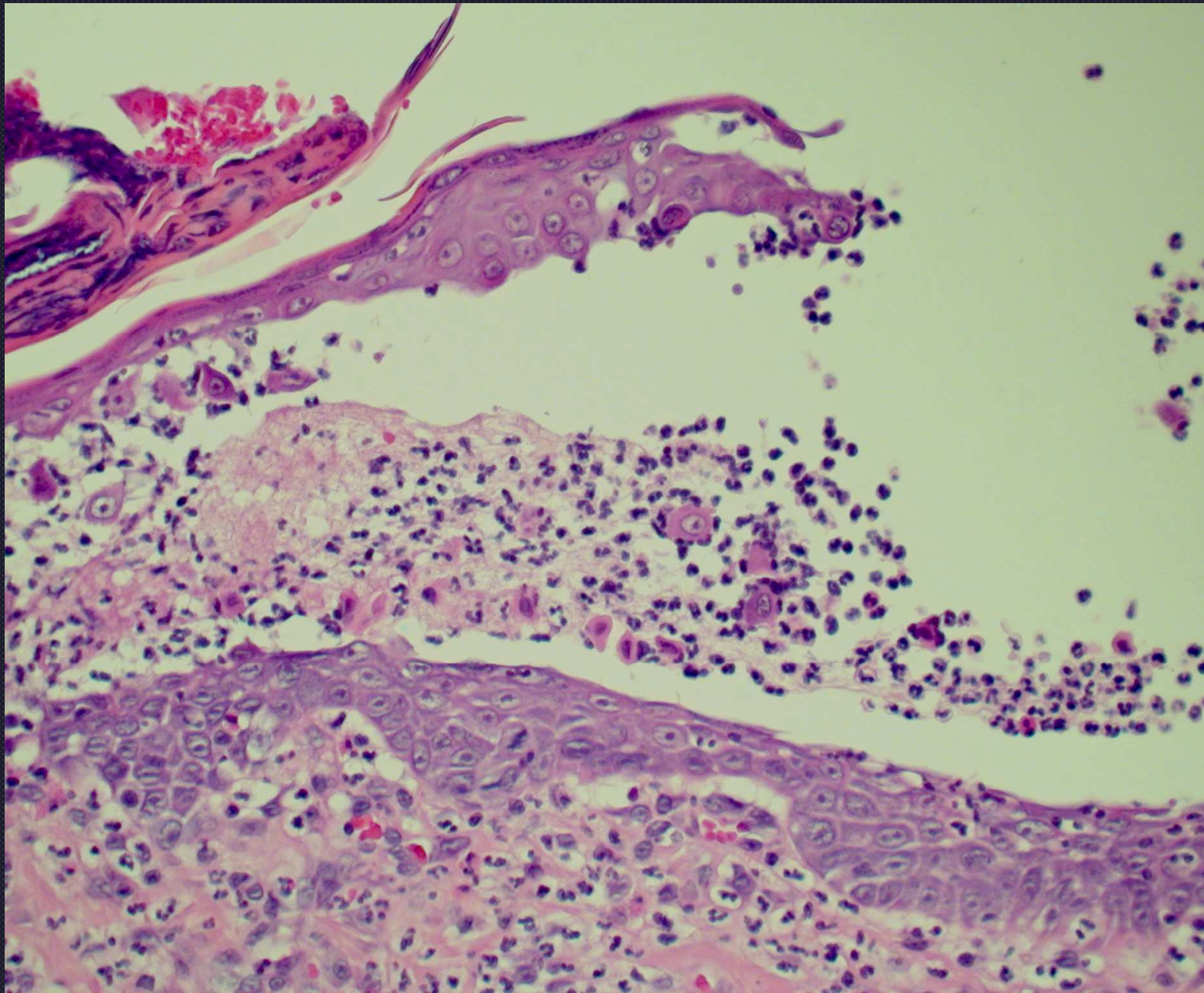
Ear margin crusting is common in cats with PF



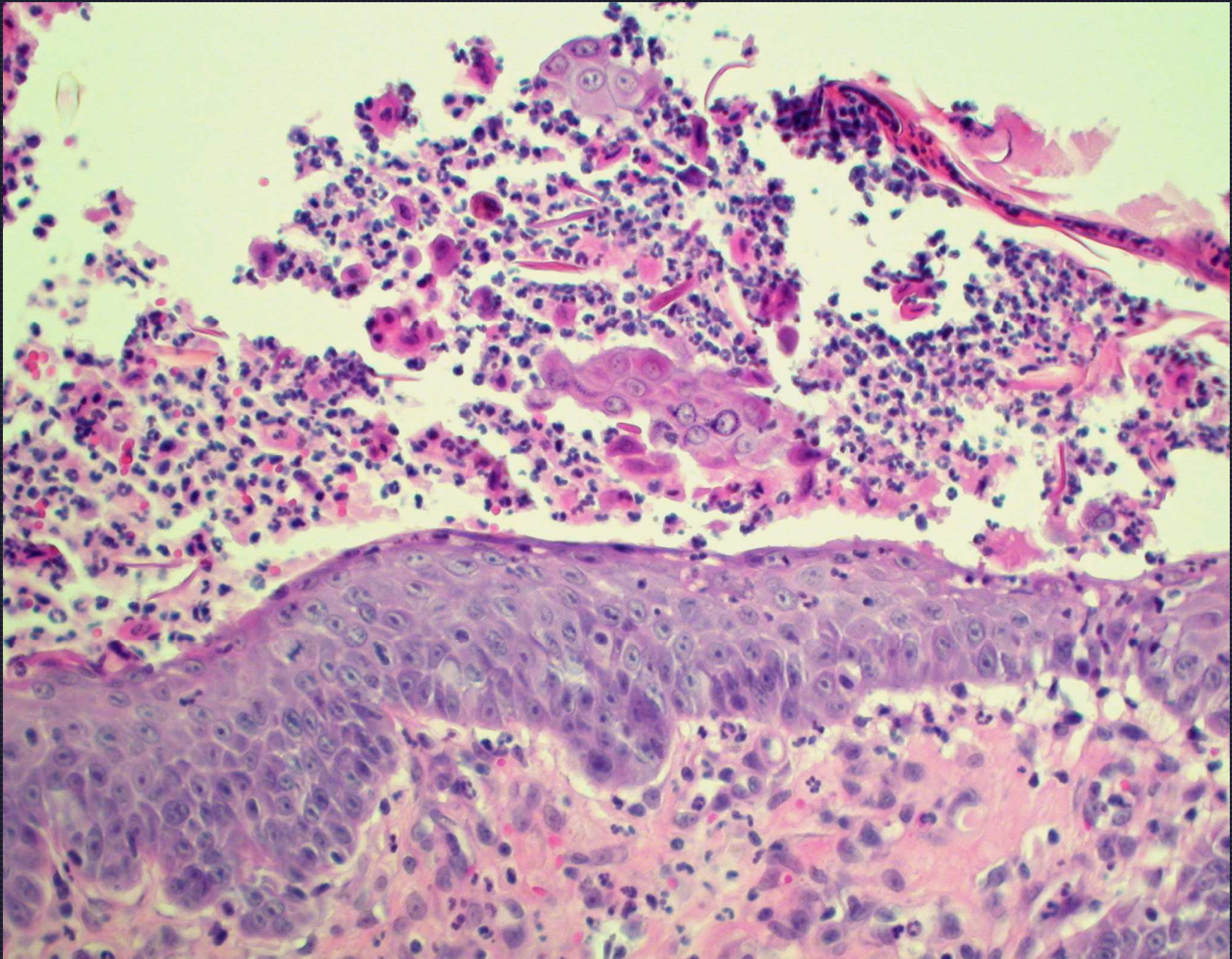
Feline PF



Waves of pustules and multiple zones of cornification in feline PF



Newly erupted PF pustule



Rafts of acantholytic cells in PF