

# Methods of Acantholysis

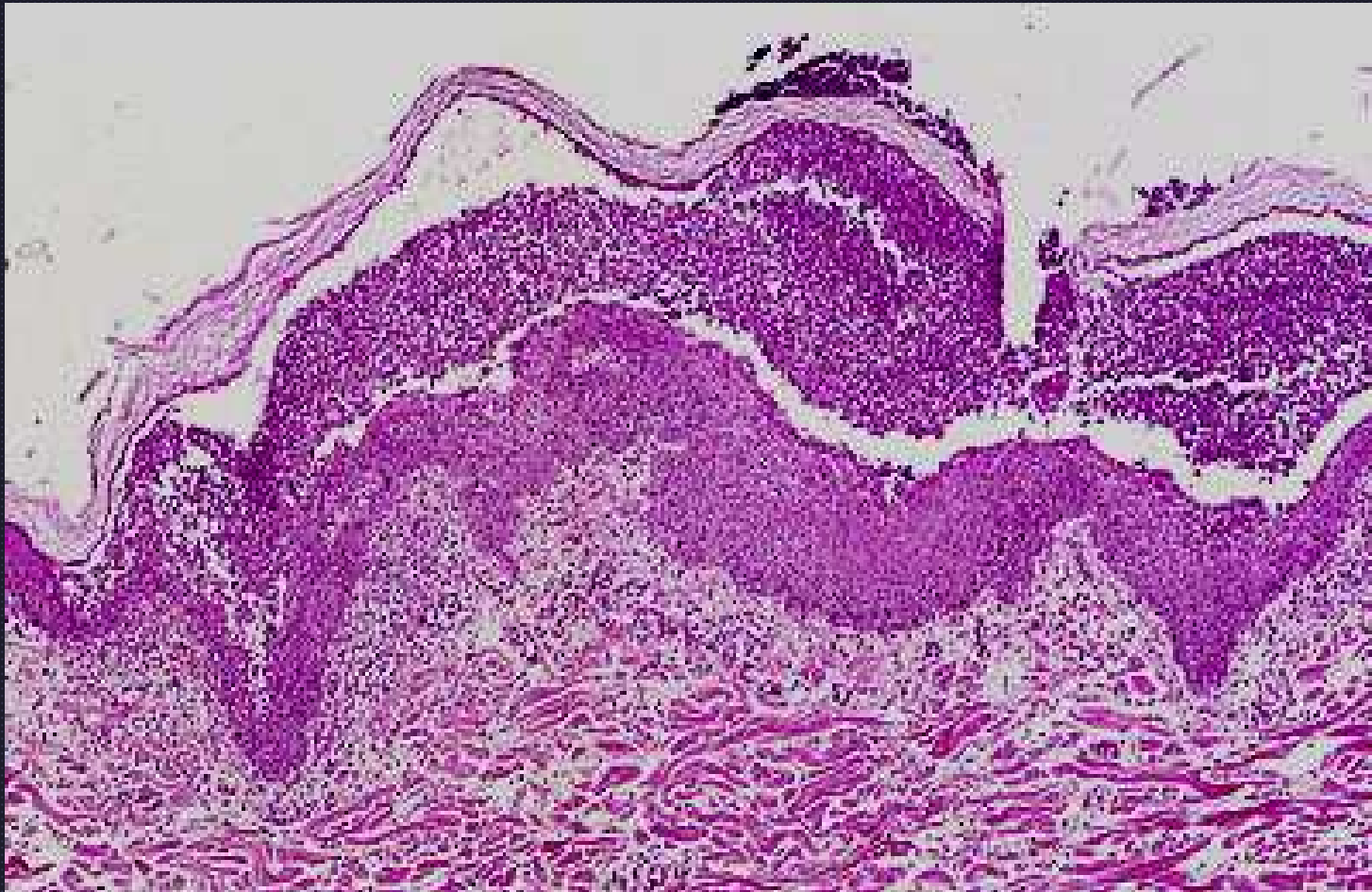
- #1 Autoimmune disease due to autoantibody production to cell adhesion molecules

# Methods of Acantholysis

- Bacterial infection with release of proteolytic enzymes and bacterial toxins
  - \*\*mild acantholysis
  - \*\*bacteria usually present
  - \*\* small pustules
- Dermatophytosis
  - Trichophyton sp. (equine and canine)

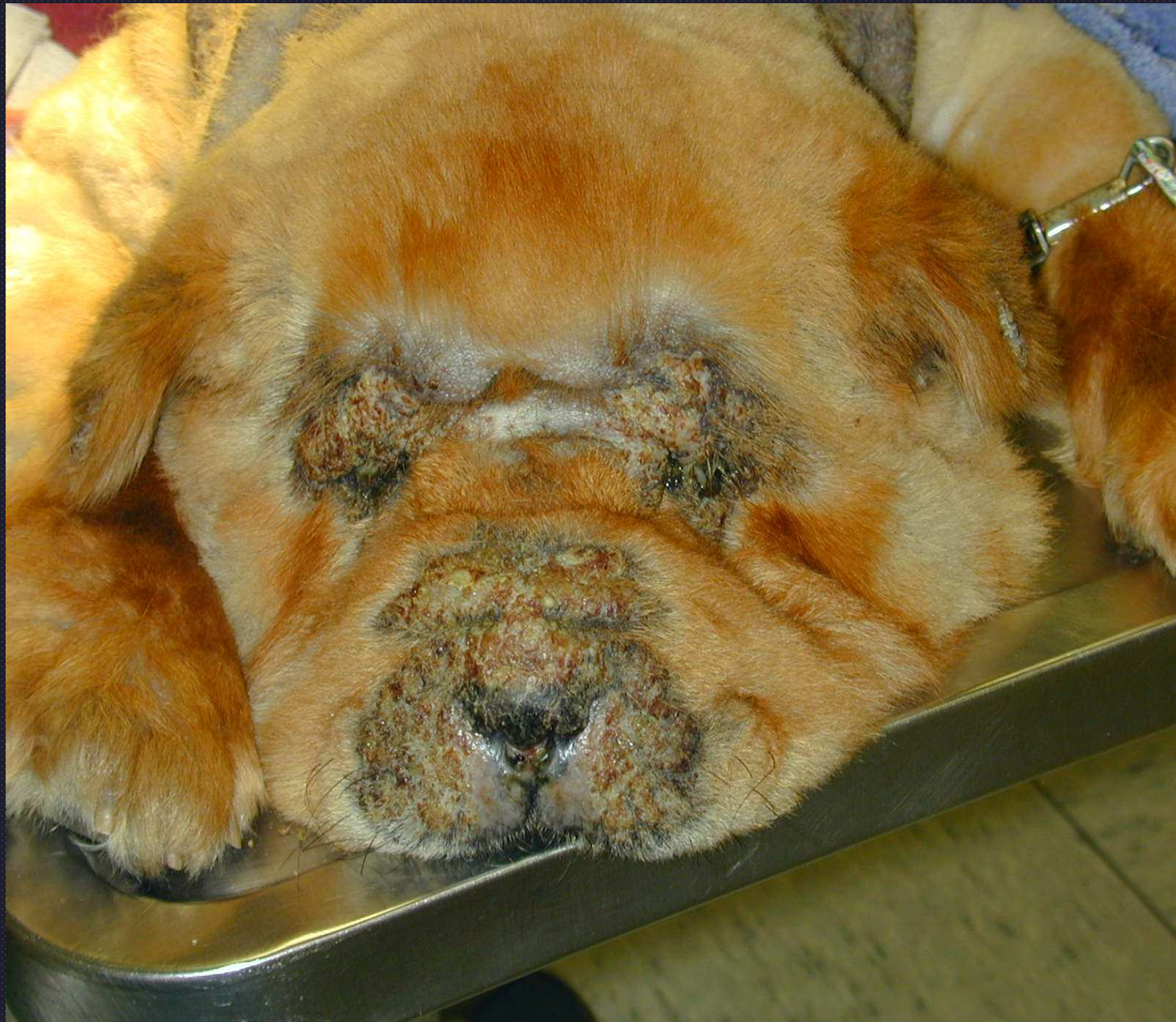# Methods of Acantholysis

- \*SEVERE!!\* edema
  - Intercellular edema- Spongiosis
  - Intracellular edema- “Ballooning degeneration” ??? *Is this true?*
  - Equine urticarial reaction



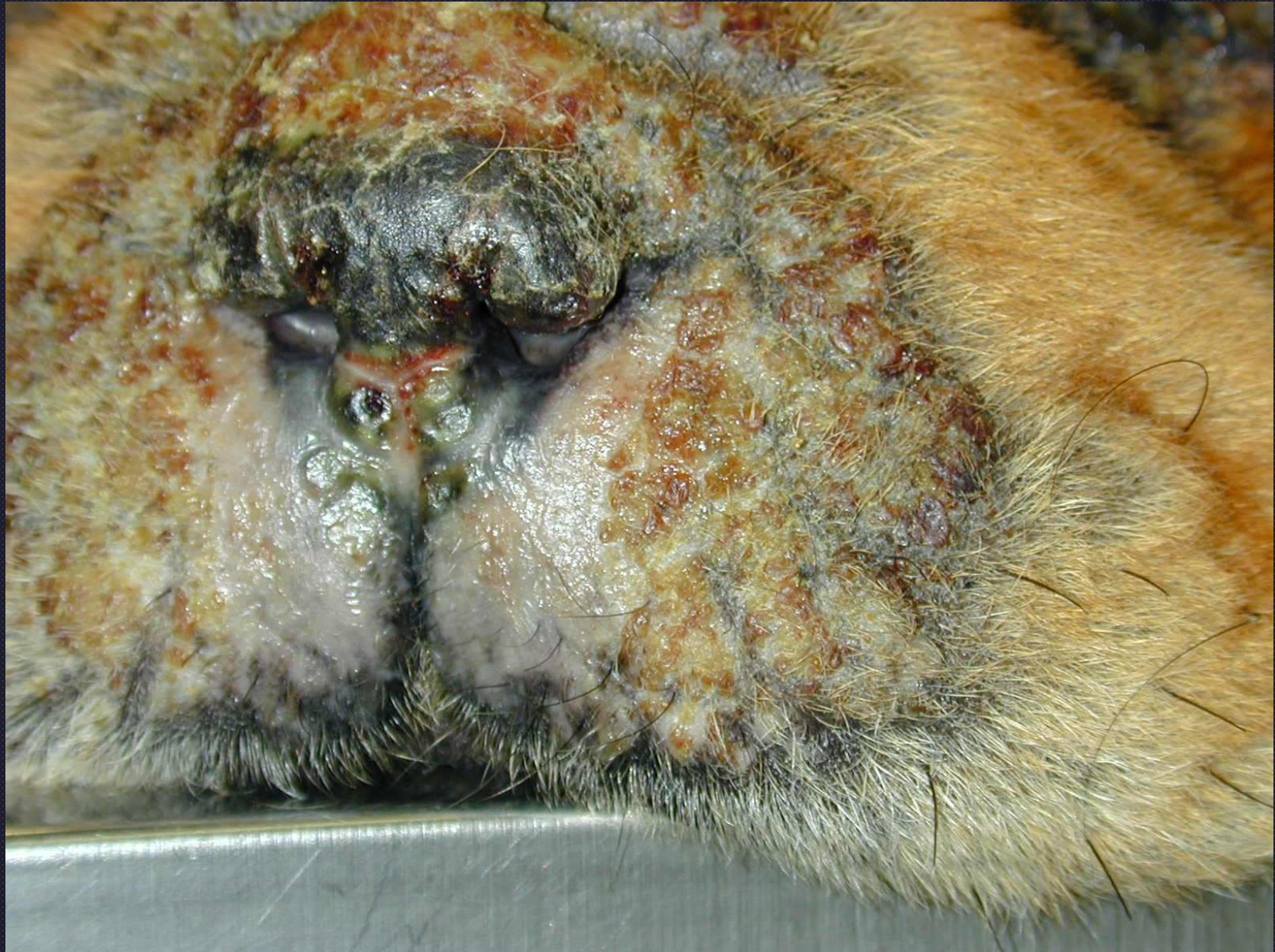Intraepidermal pustular dermatitis  
Pemphigus foliaceus (PF)





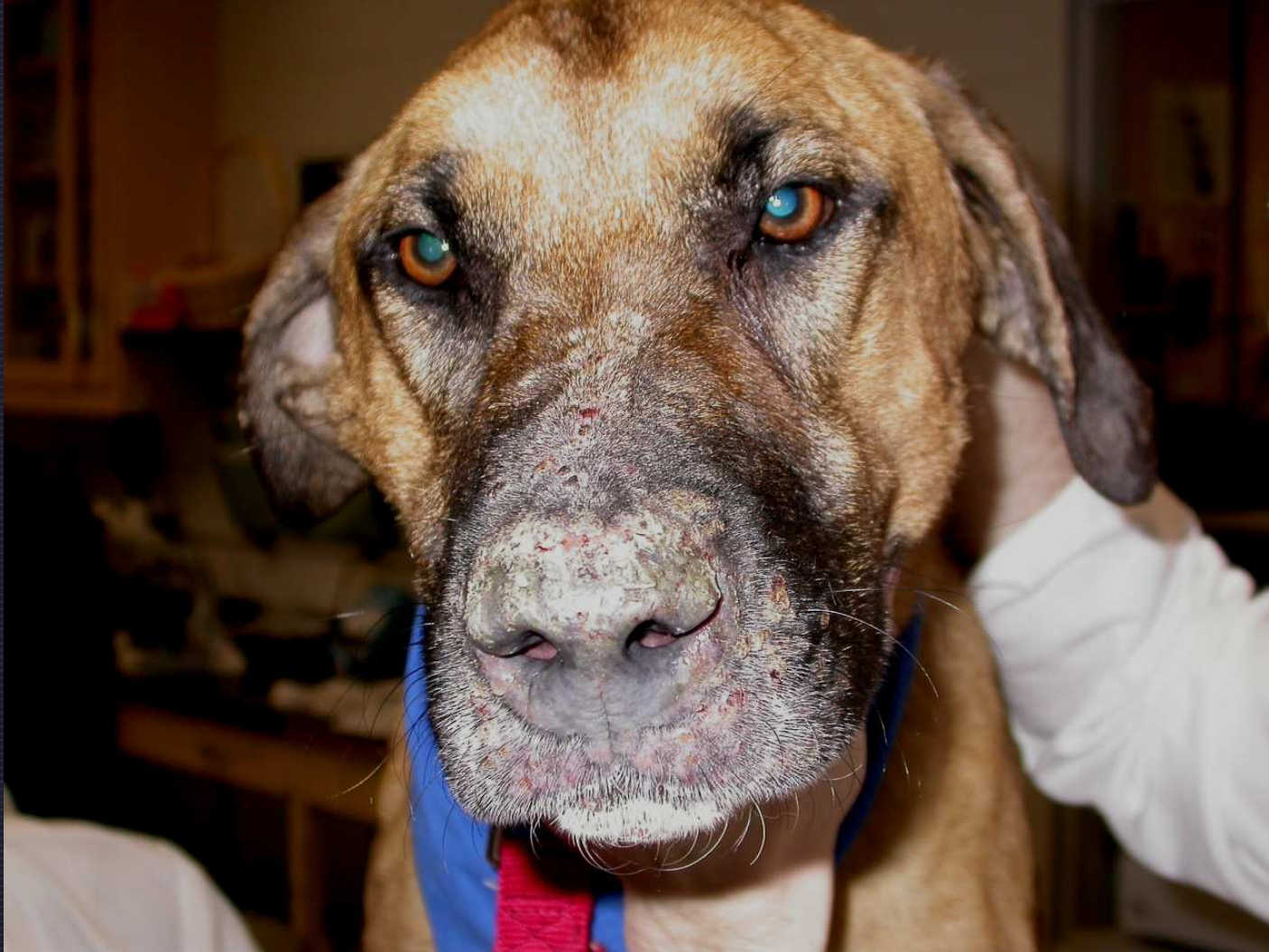*Pemphigus foliaceus*



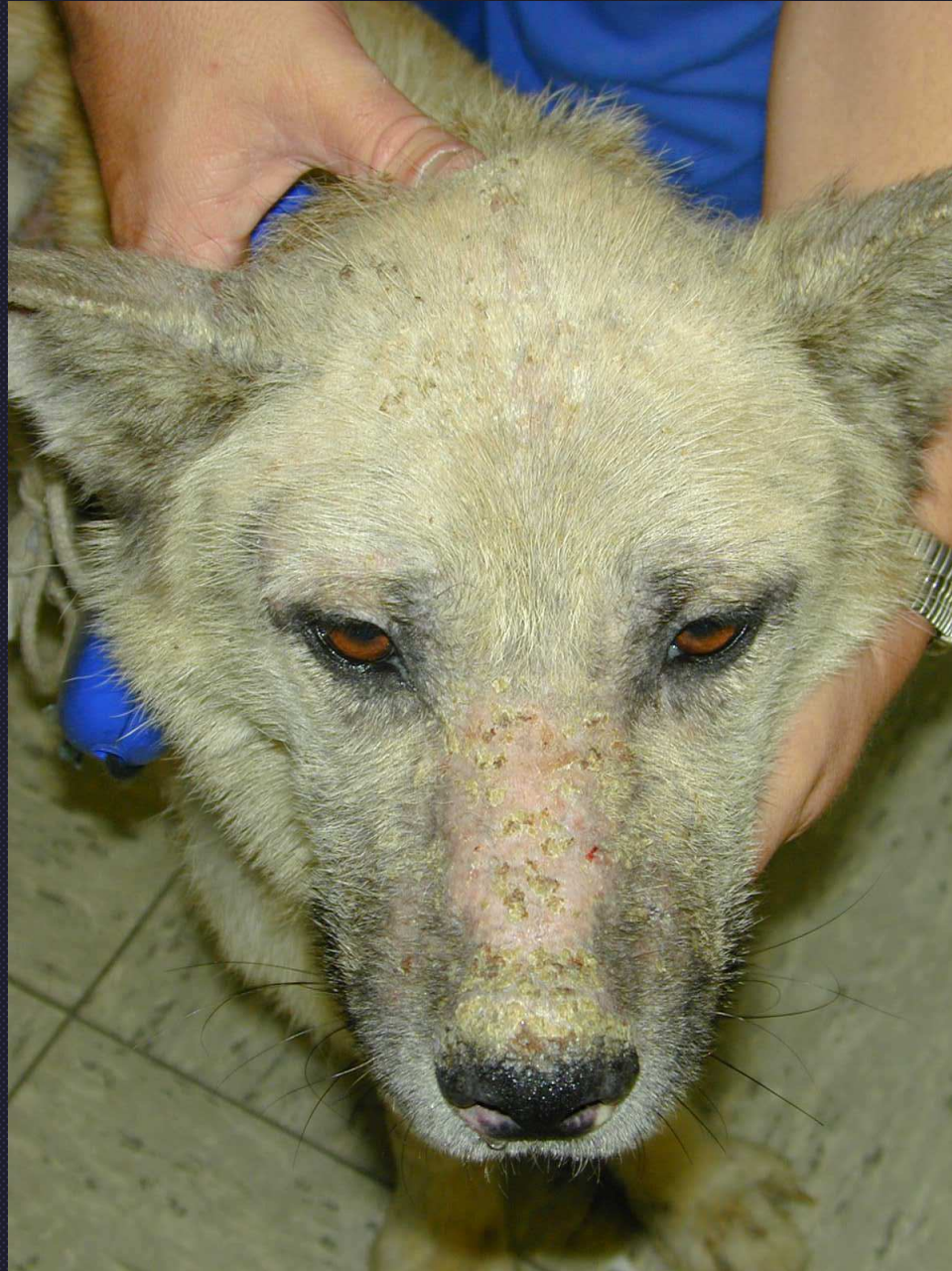

*Pemphigus foliaceus*



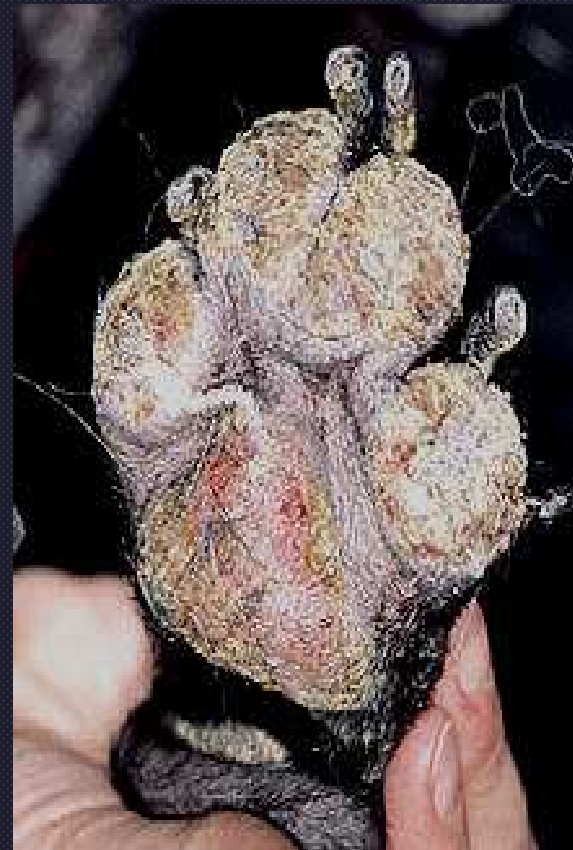
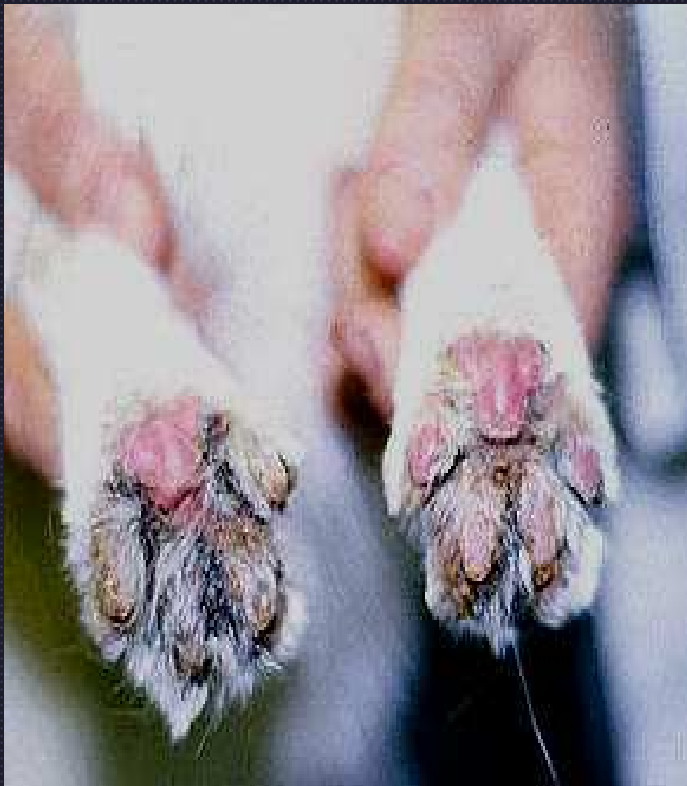
*Pemphigus foliaceus*



*Pemphigus foliaceus*





Footpad hyperkeratosis and crusting due to pemphigus foliaceus

# PF vs Pyoderma

- Large subcorneal pustules (span several adnexal units) and crusts
- Corneal layer contains waves of pustules
- Nondegenerate neutrophils
- Absence of bacteria