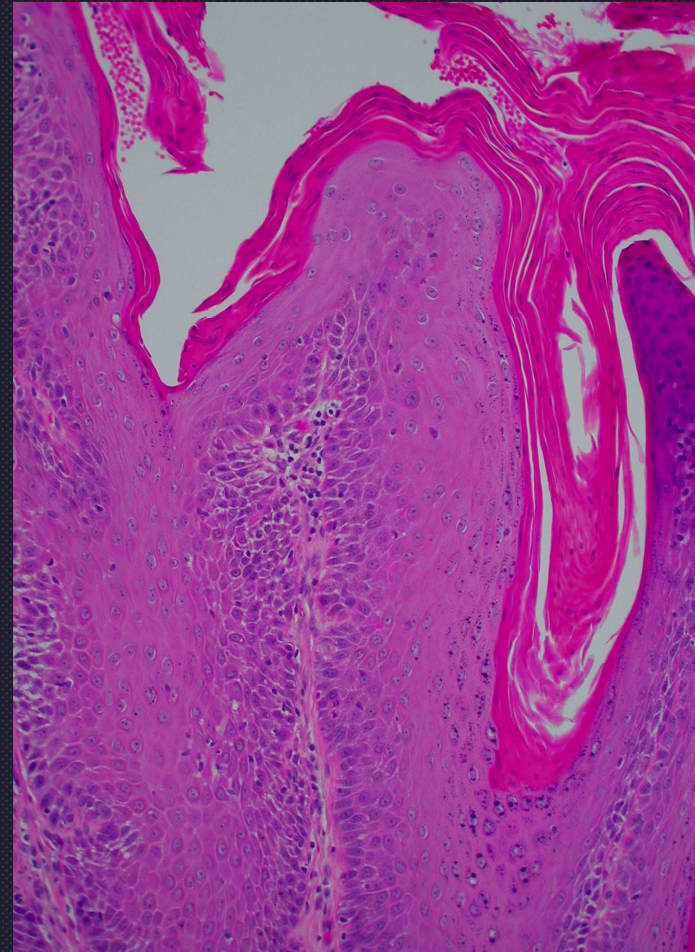
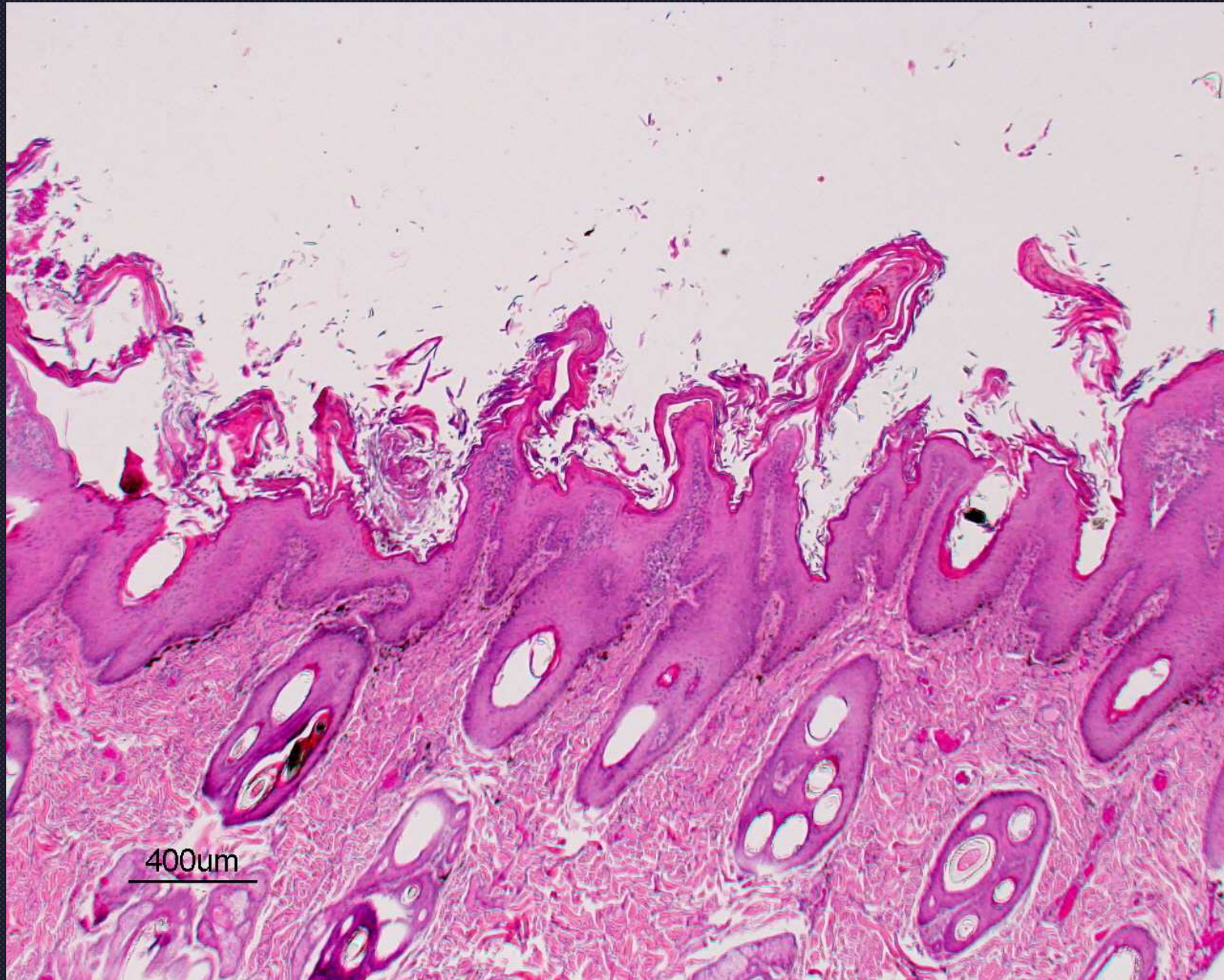


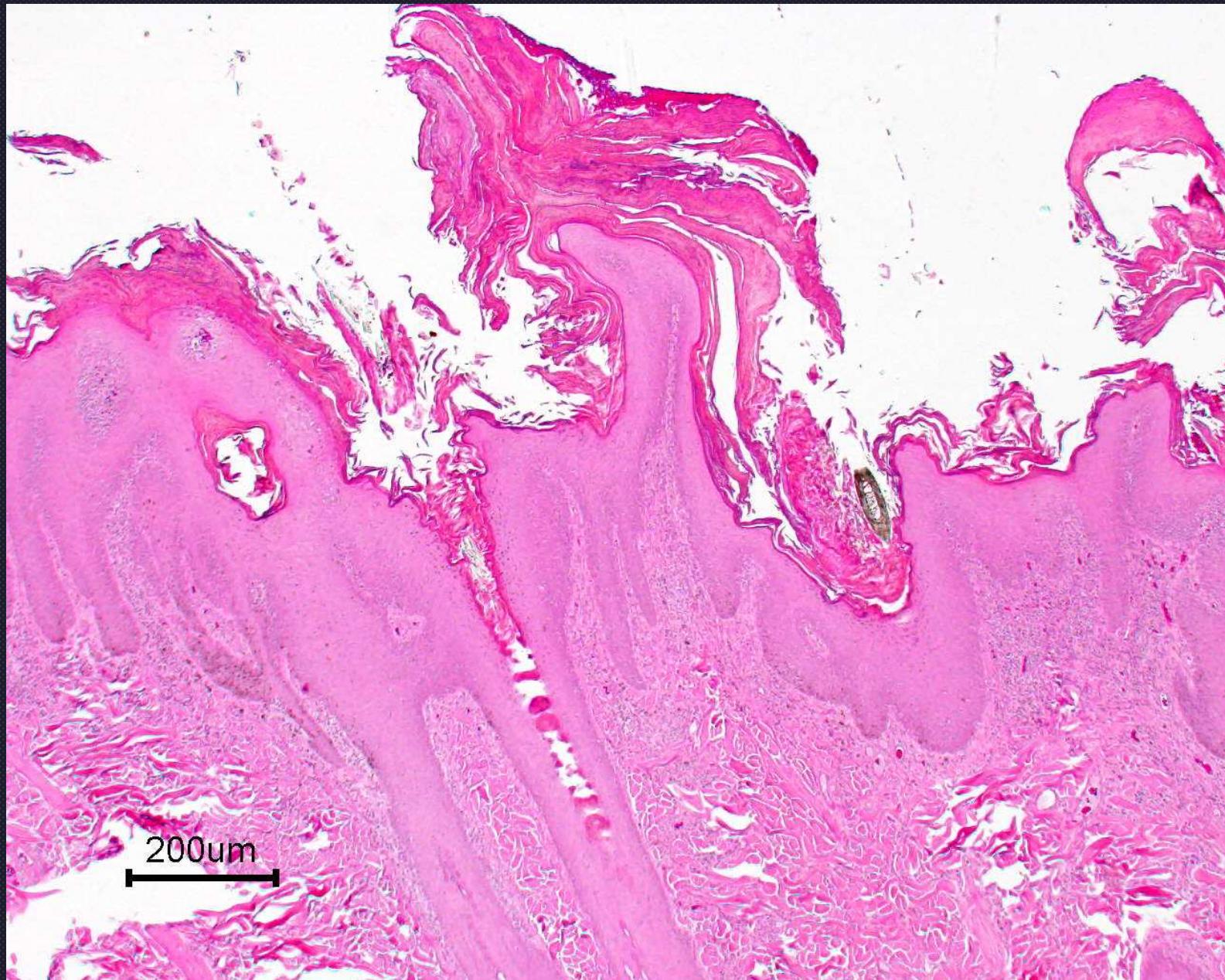
Zinc Responsive Dermatoses

- Parakeratotic hyperkeratosis
 - Follicular caps or “church spires”
 - May have perivascular dermatitis
- Not unusual to have eosinophils

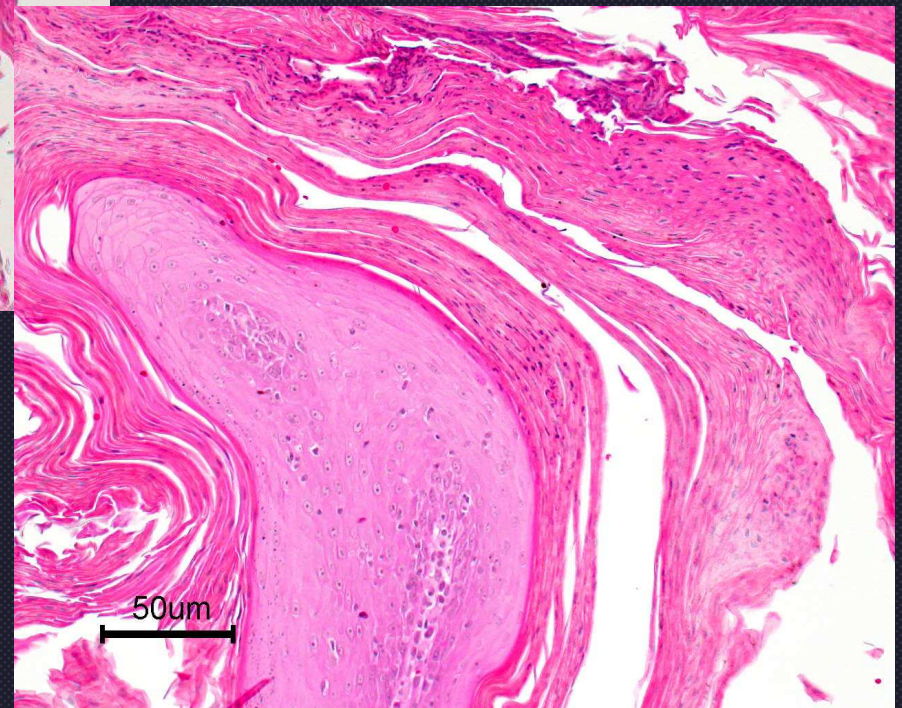
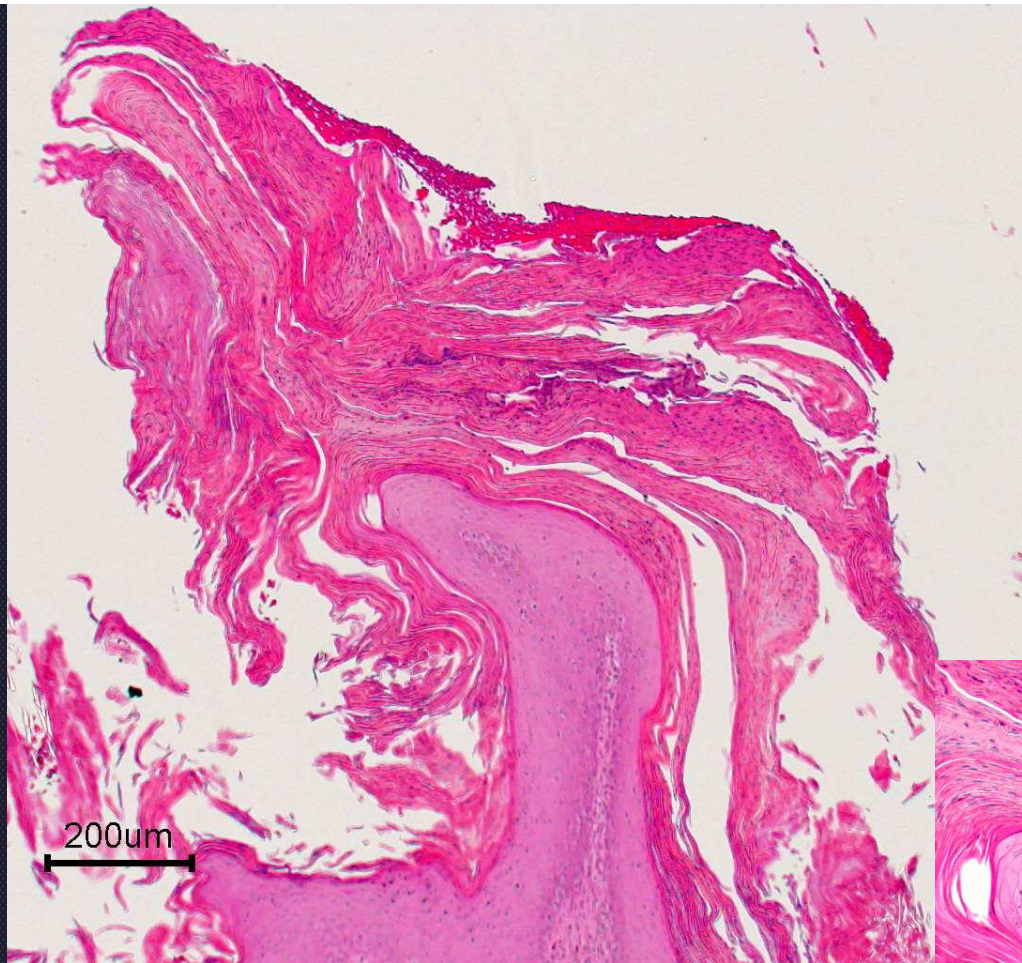




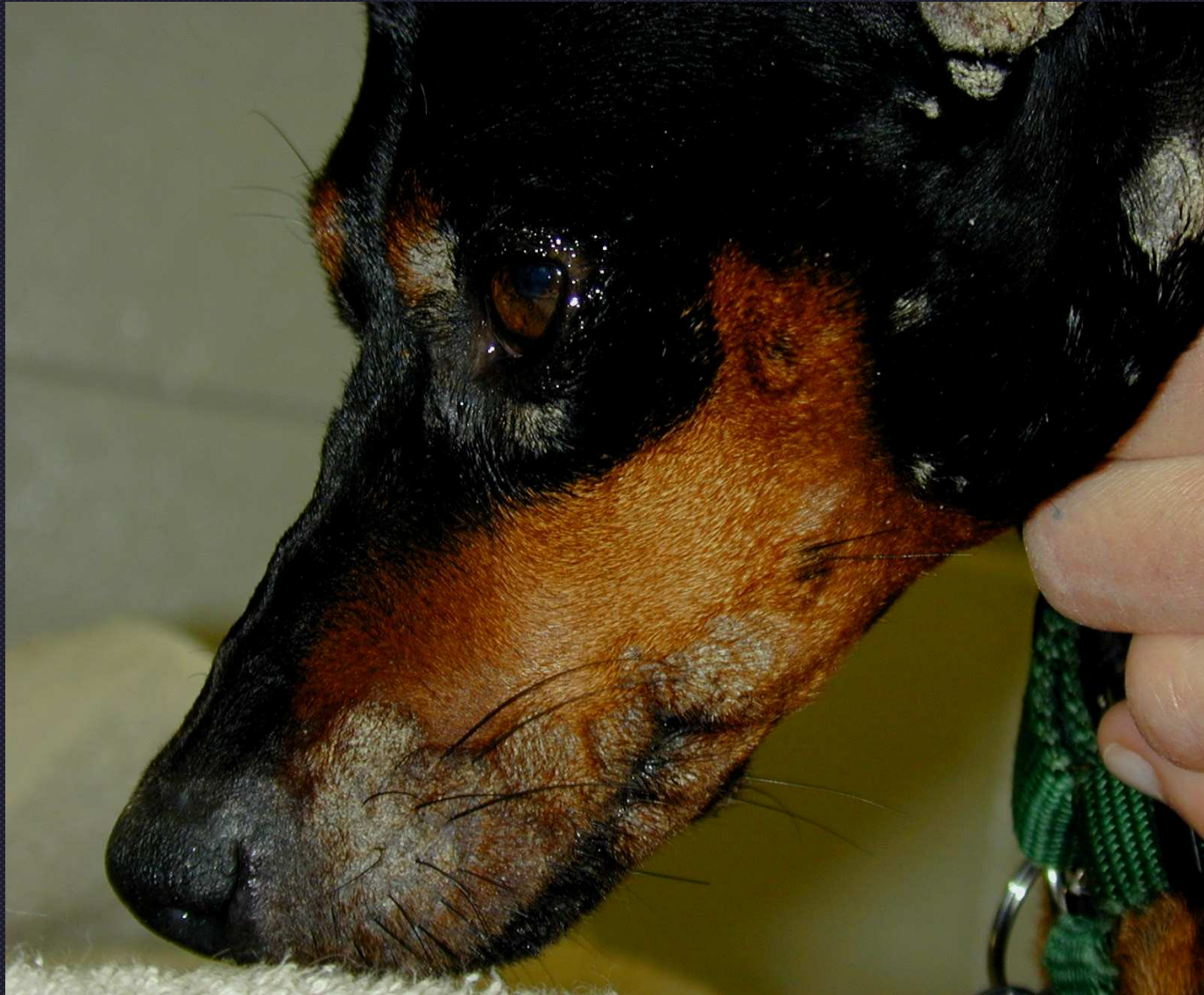Zinc responsive derm




Zn responsive derm



Zn responsive derm



Zinc responsive dermatitis in a miniature pinscher



Zn responsive dermat in a dog
from a rescue shelter;
responded completely to good diet

