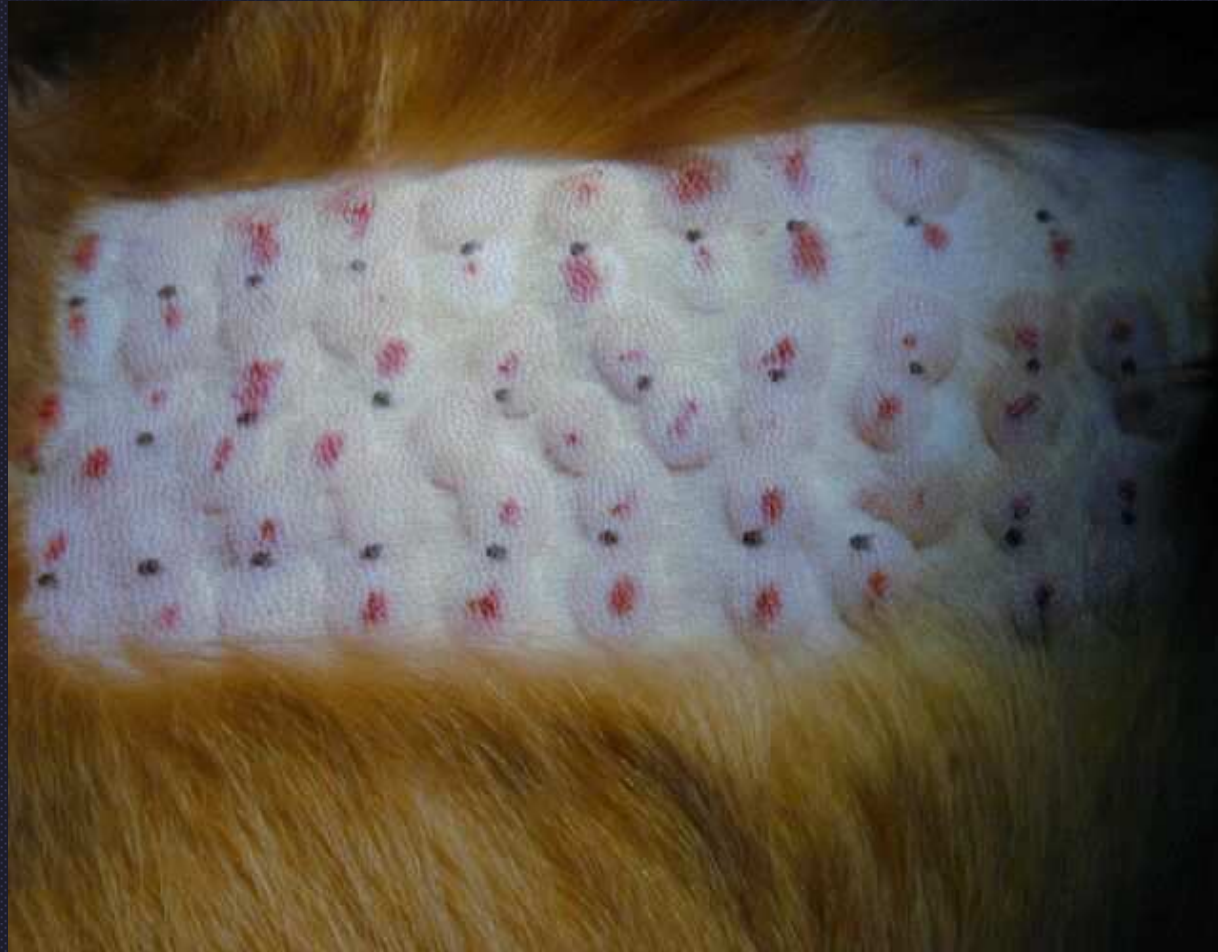
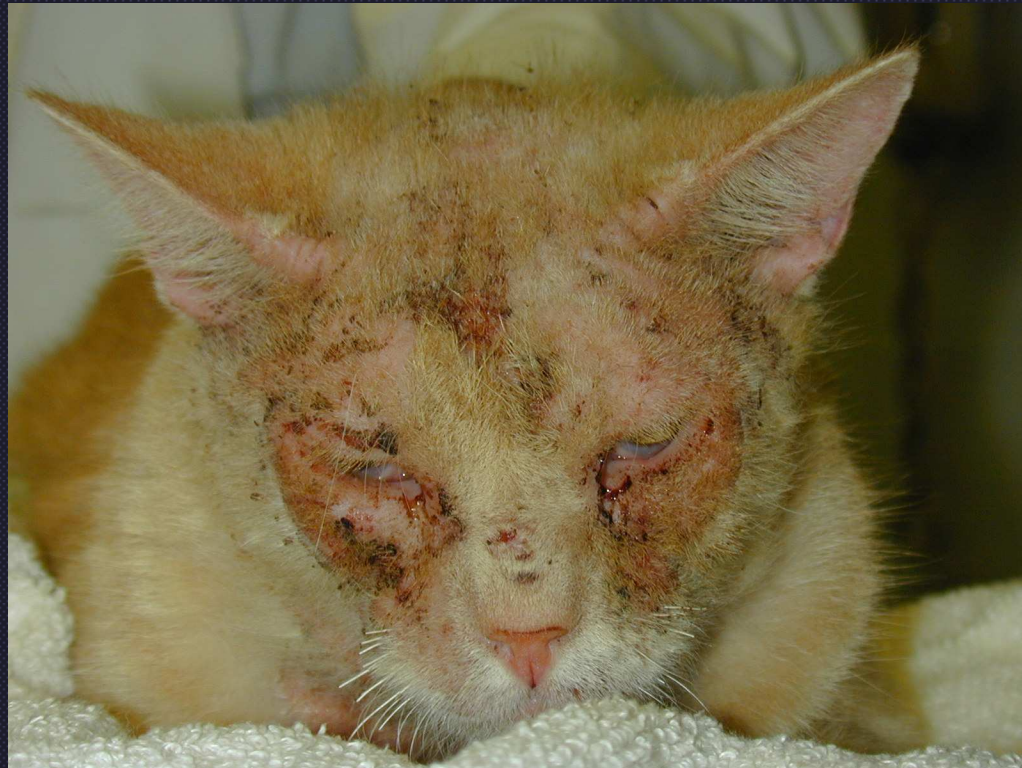
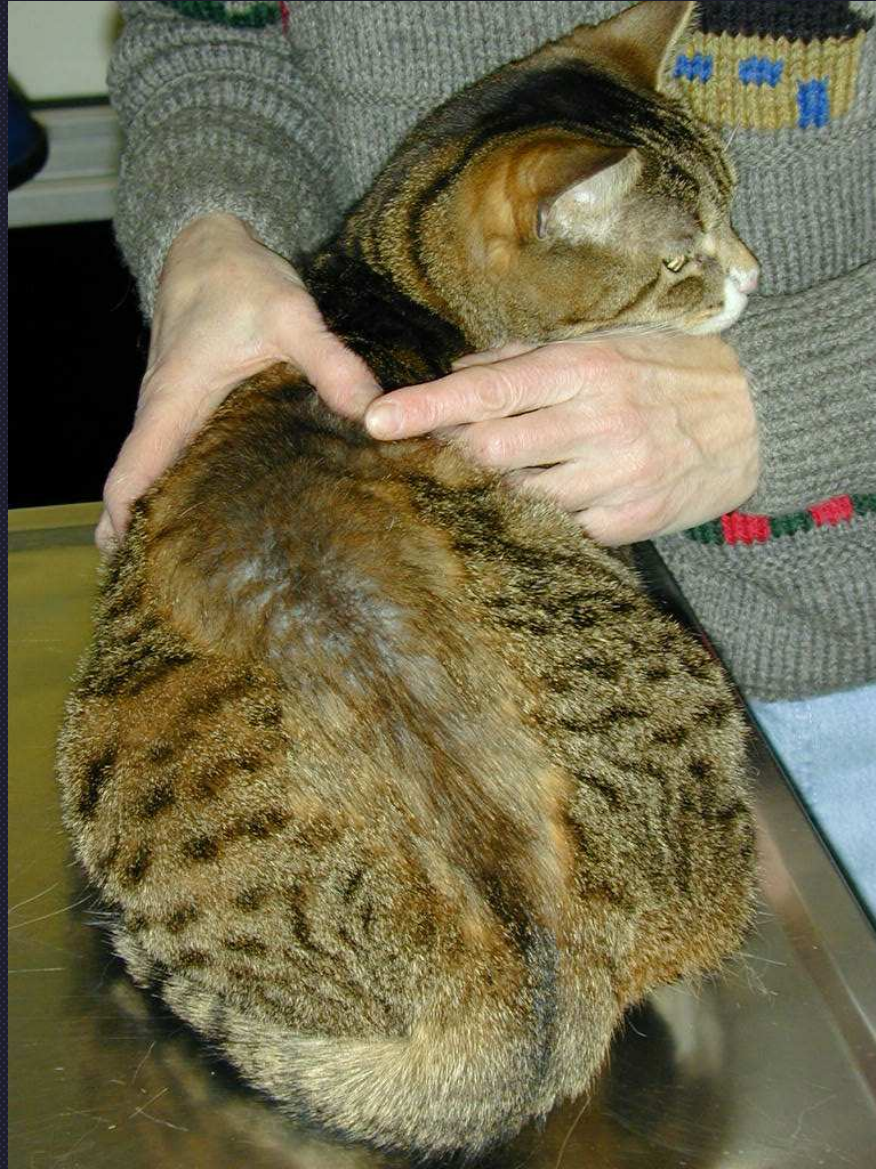- Suspect malassezia if alternating orthokeratotic and patchy parakeratotic hyperkeratosis with acanthosis
- Allergic reaction pattern
- Intertriginous areas
- Recommend tape stripping to quantitate organisms
  - Lost in histopathology processing



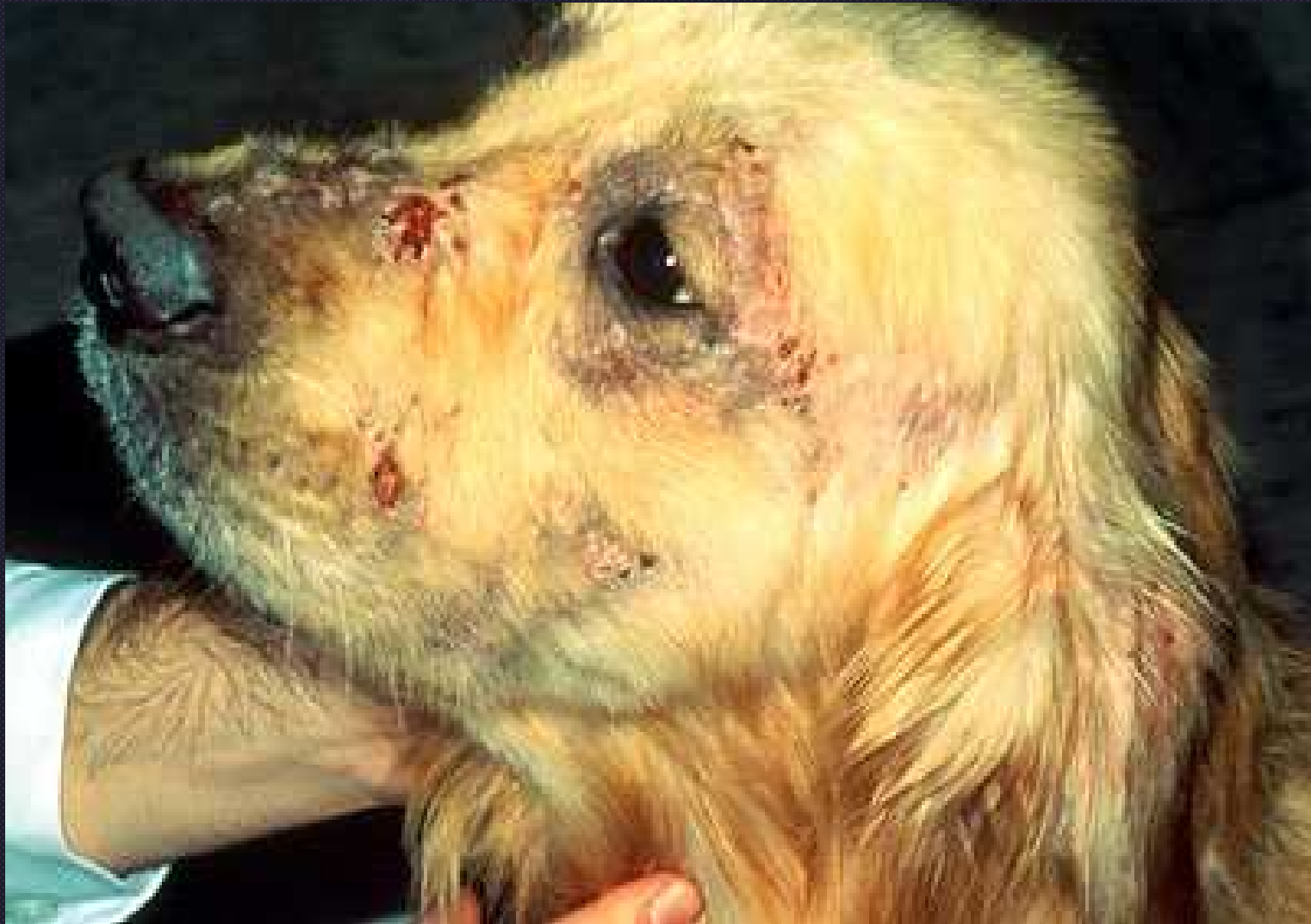Intradermal skin test for allergen specific immunotherapy



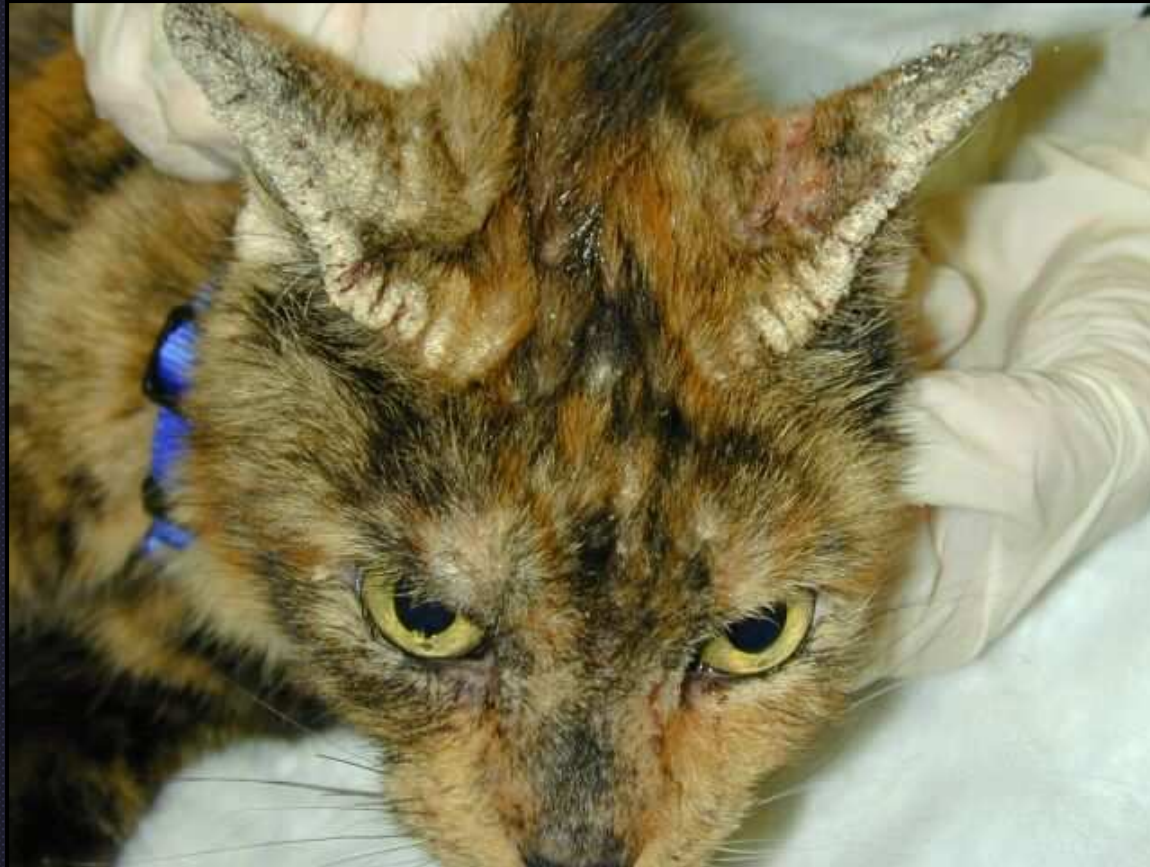Severe facial pruritus in a food allergic cat



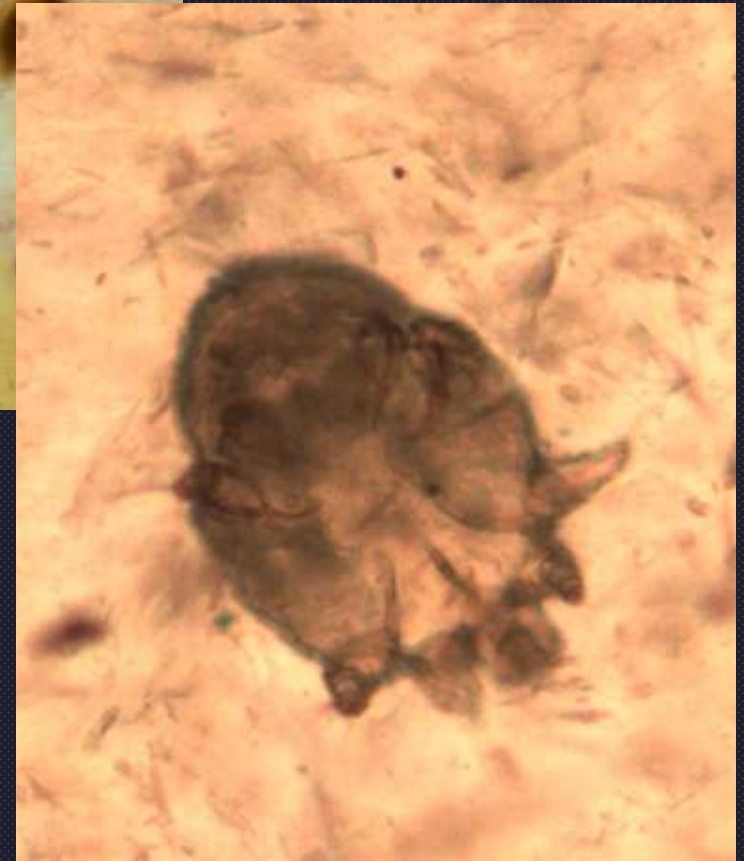
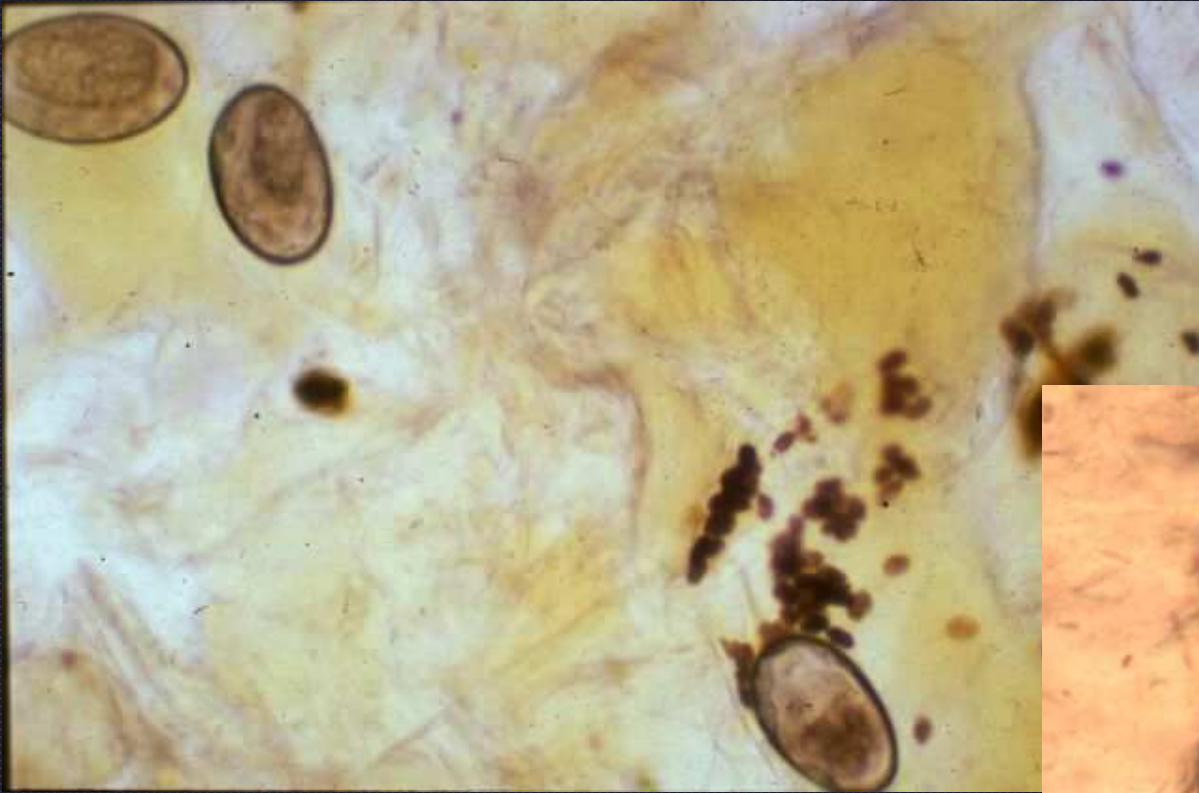
Flea allergy dermatitis



Sarcoptic mange— It is a hypersensitivity rxn to the mites!



Notoedres dermatitis



Skin scraping: sarcoptic mange mites  
and fecal pellets