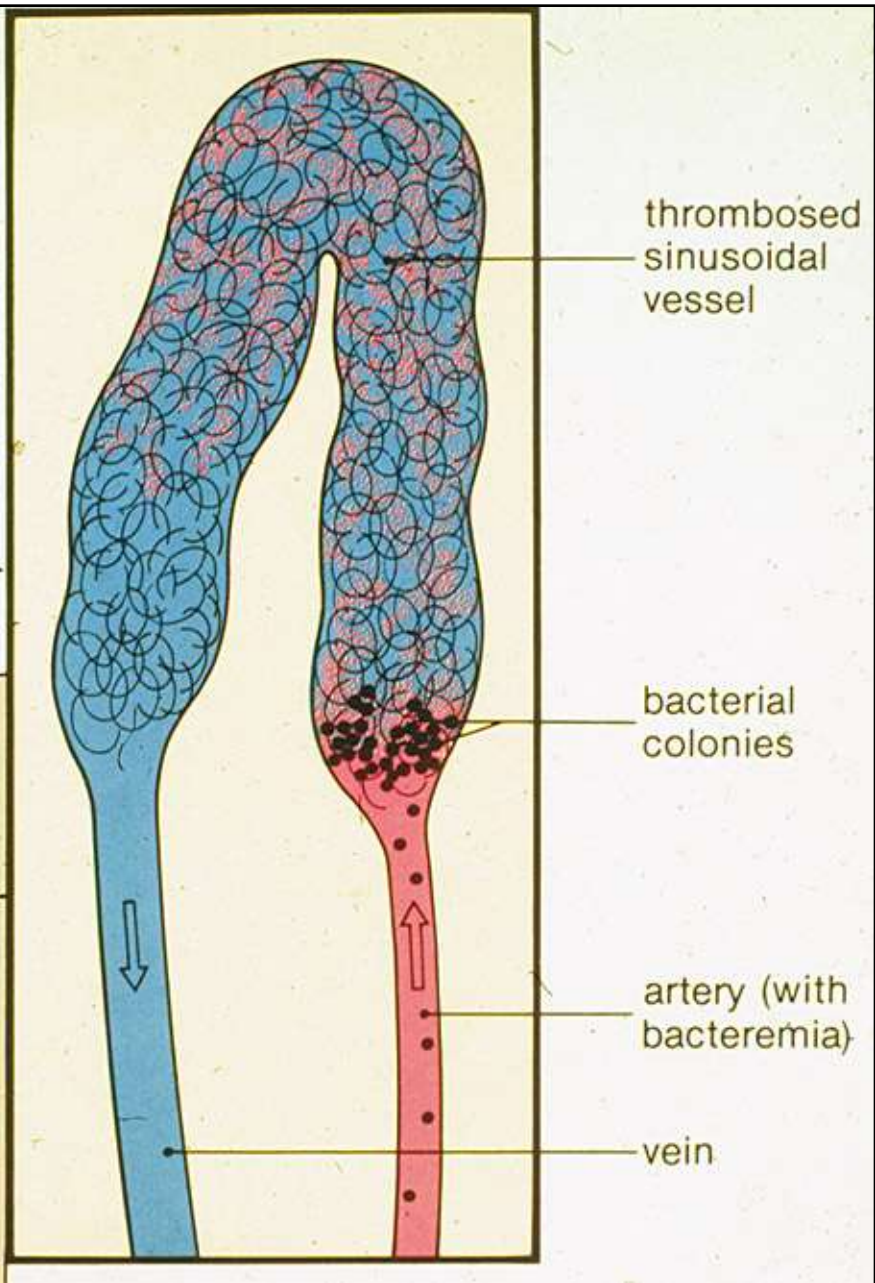
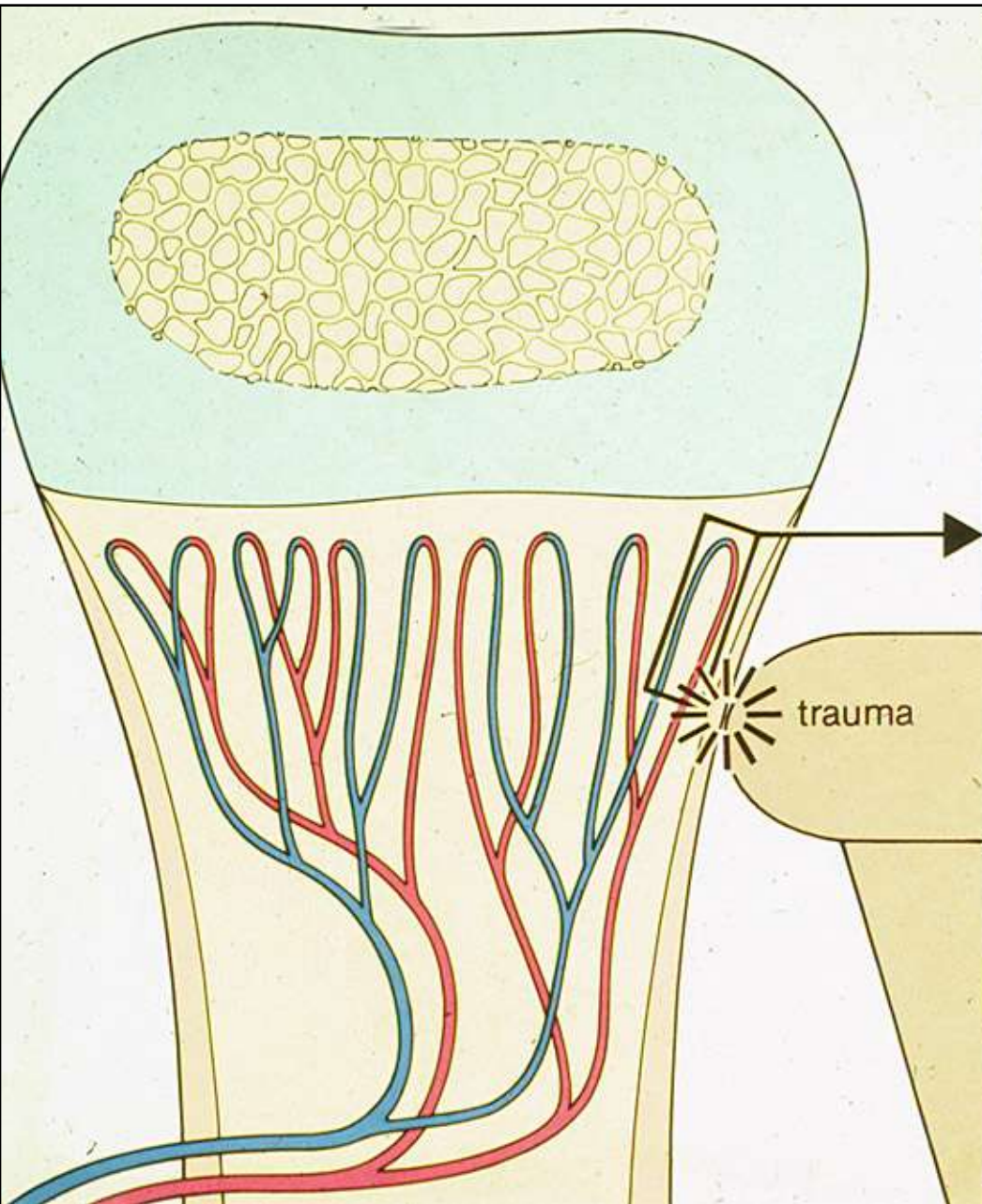
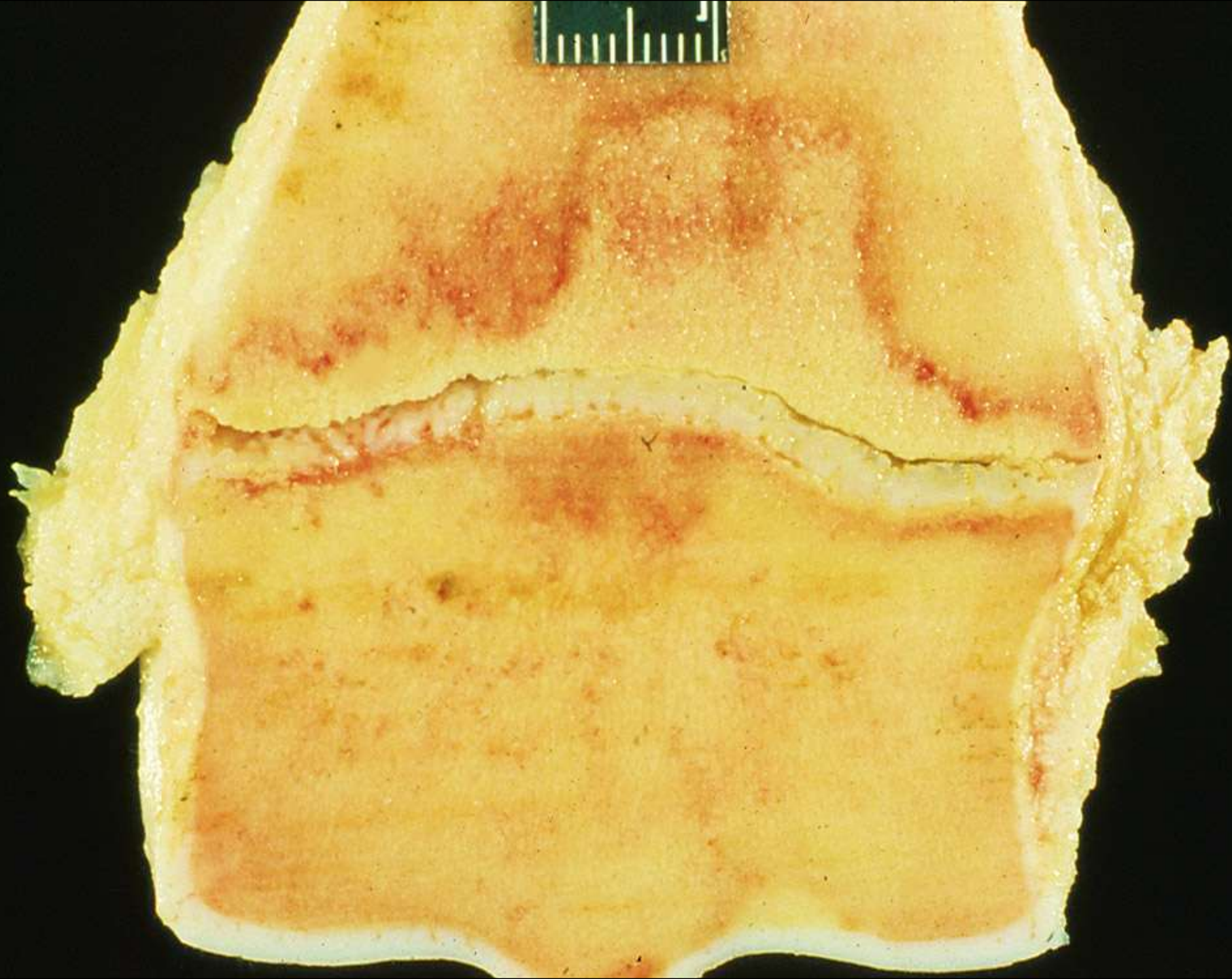
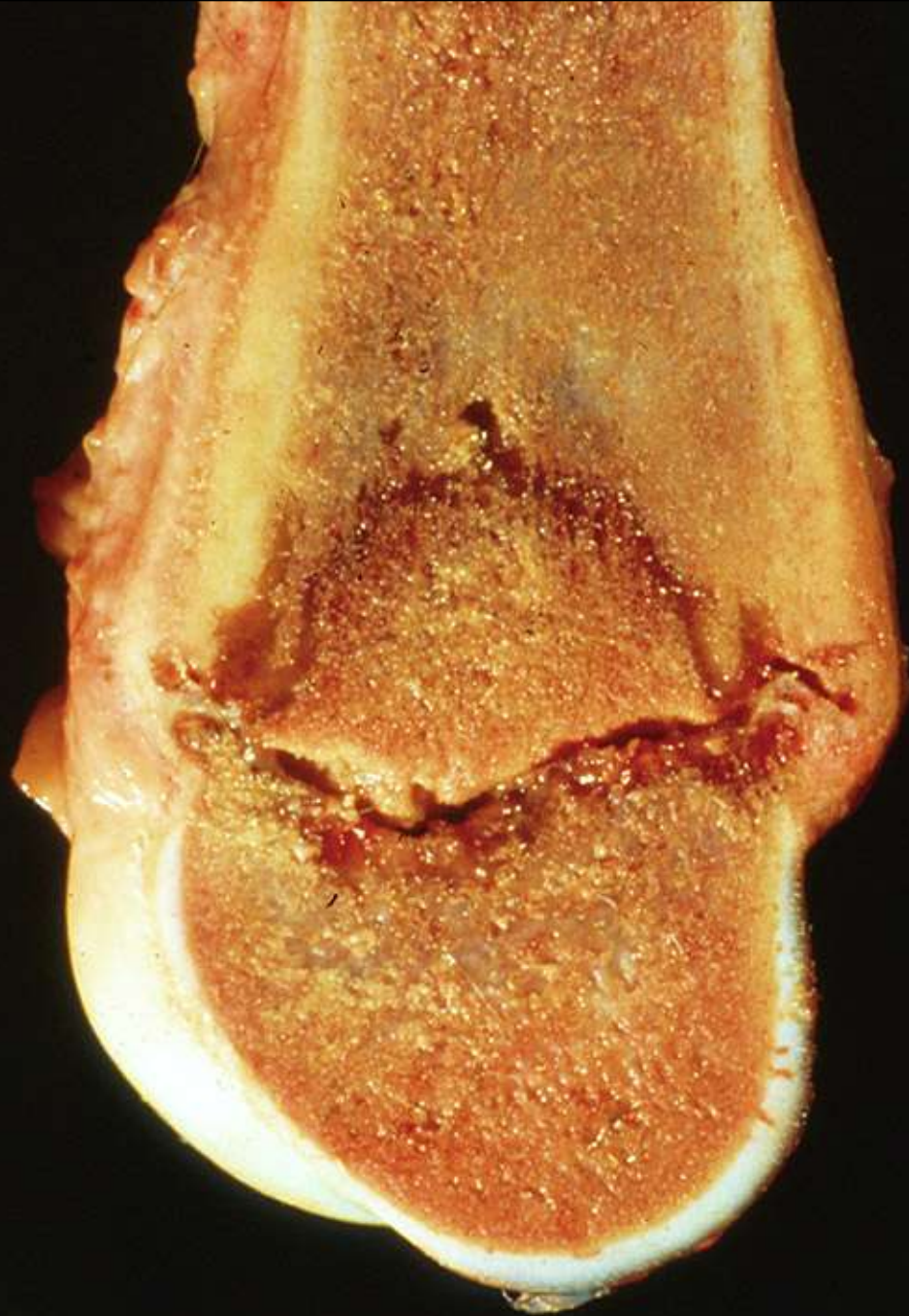
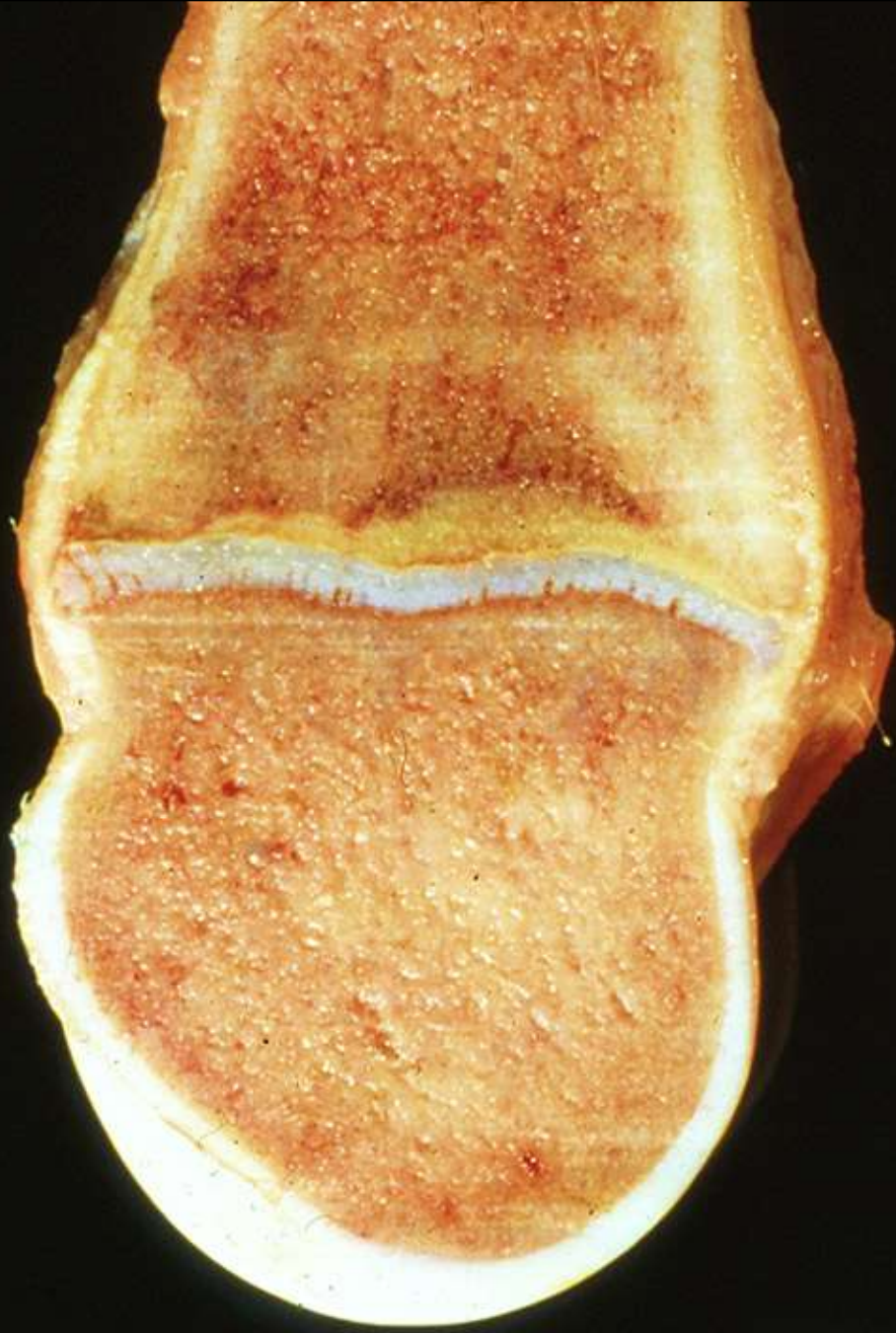

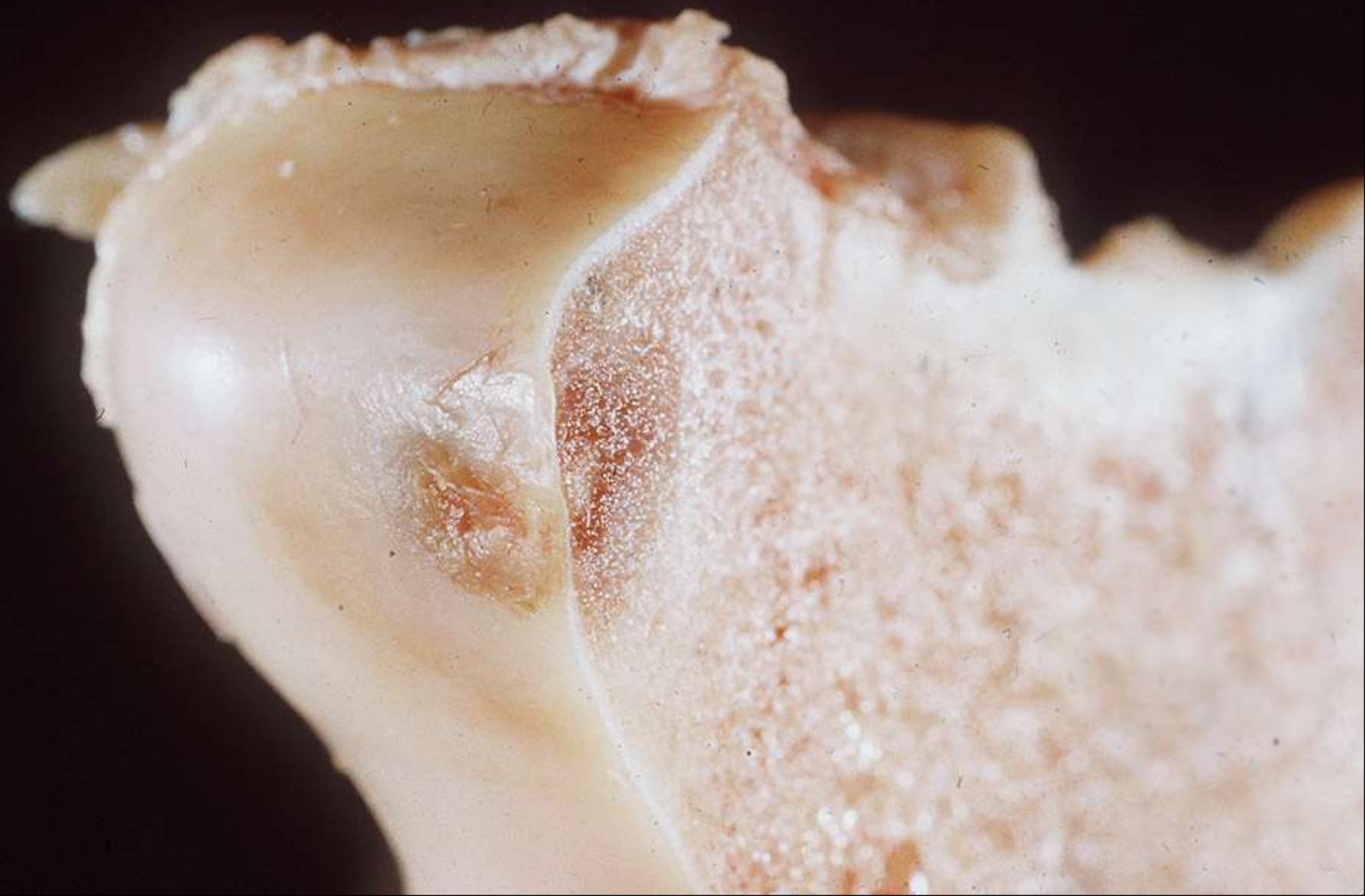Infectious inflammation of Bone

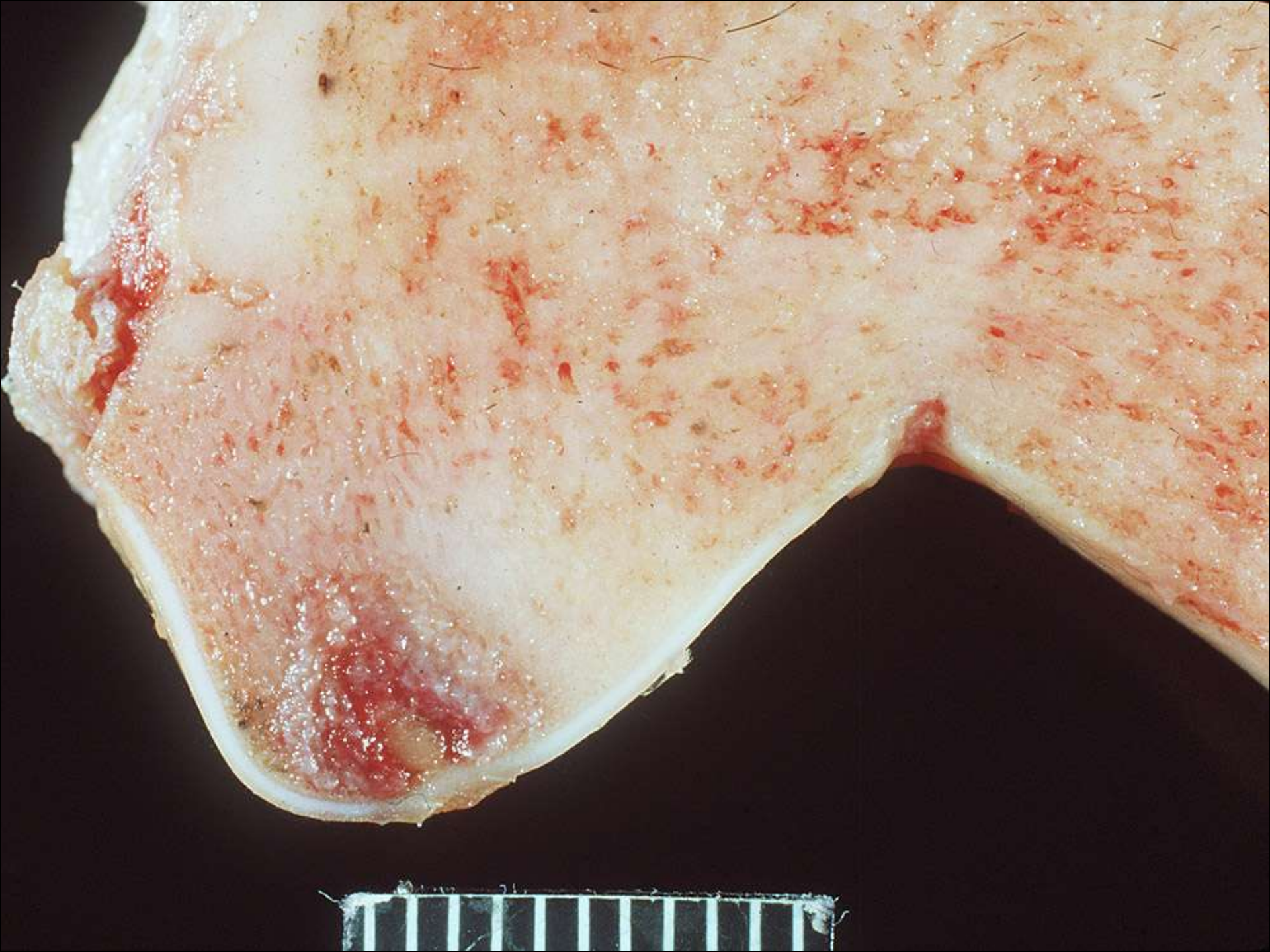Predilection at traumatized sites
of endochondral ossification

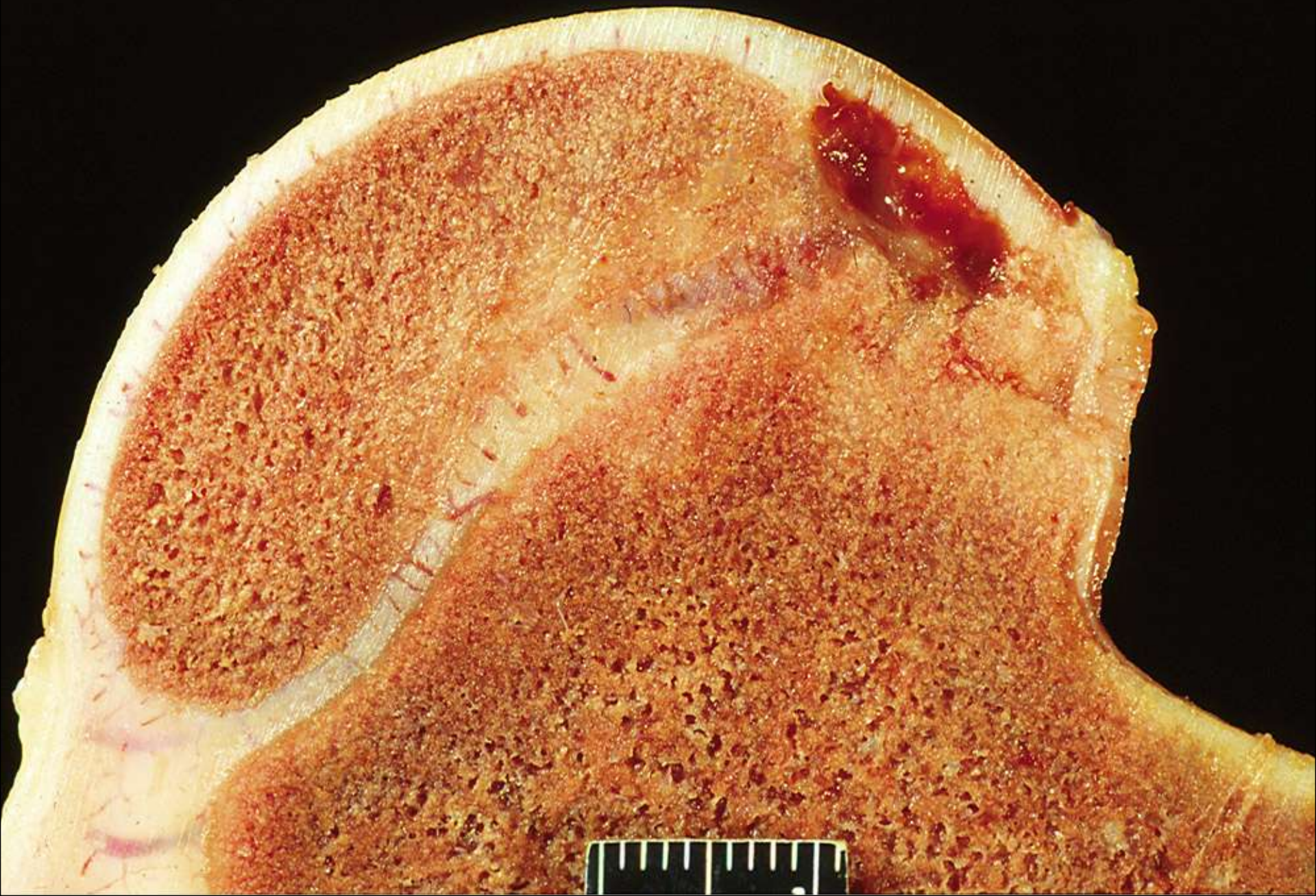


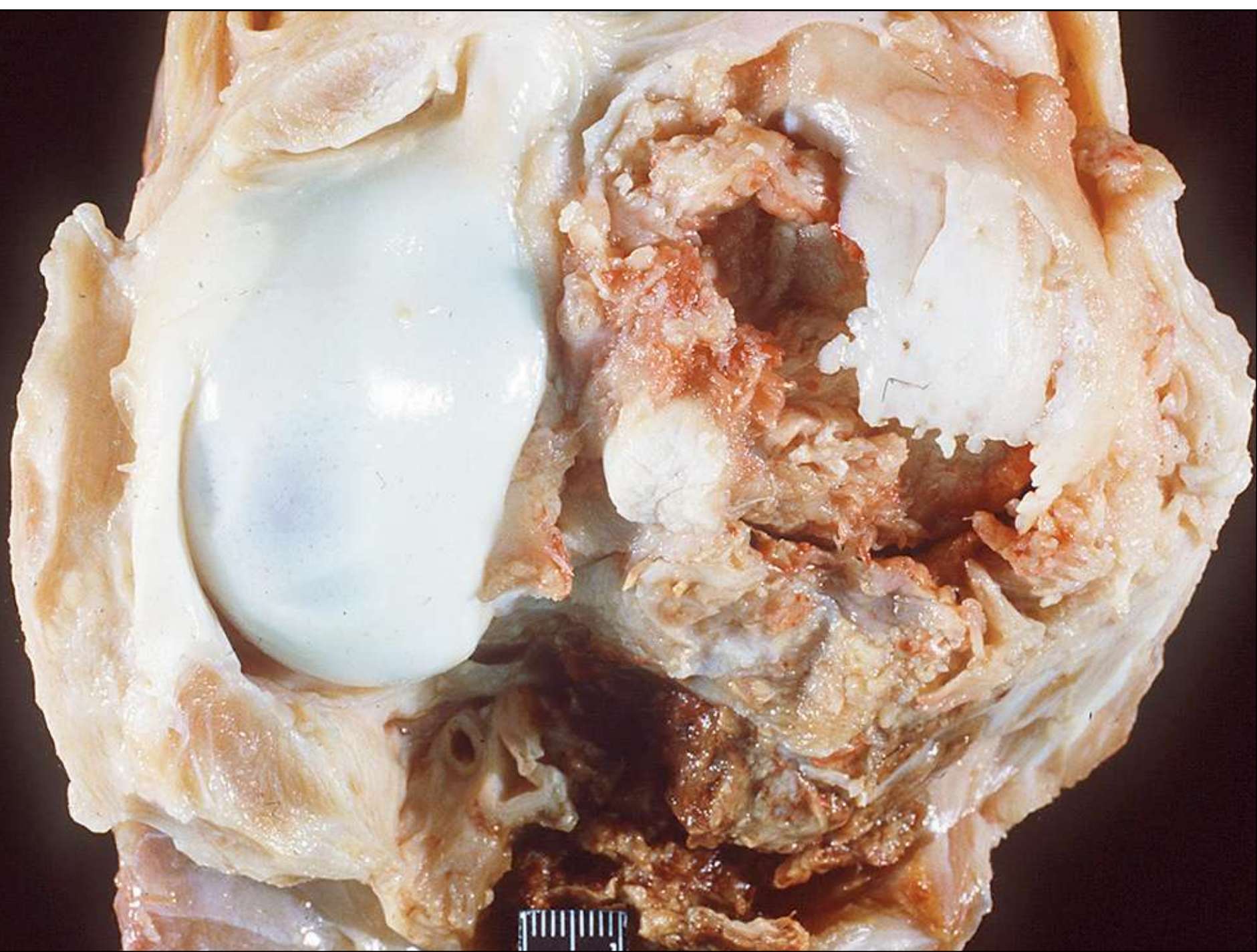




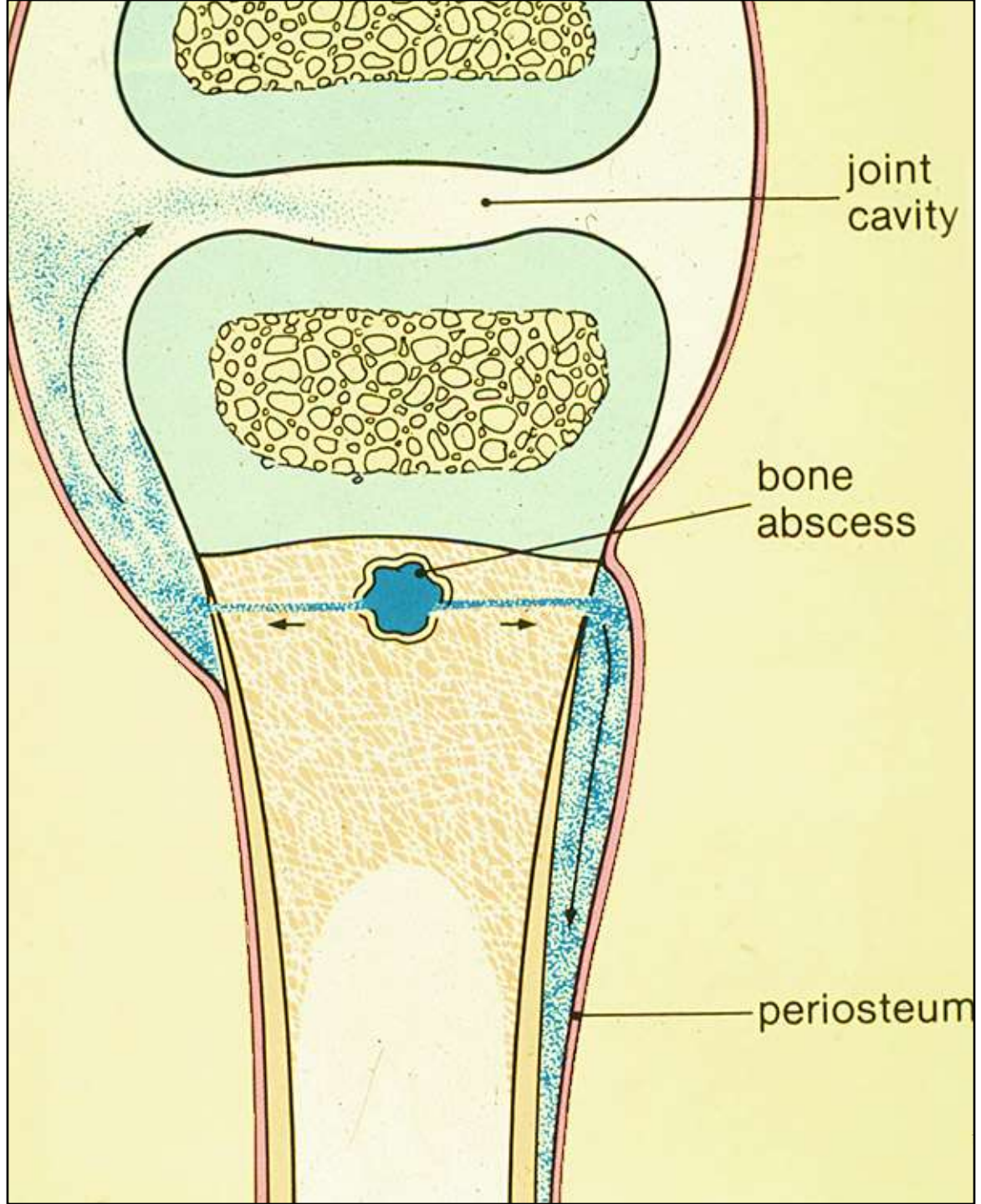








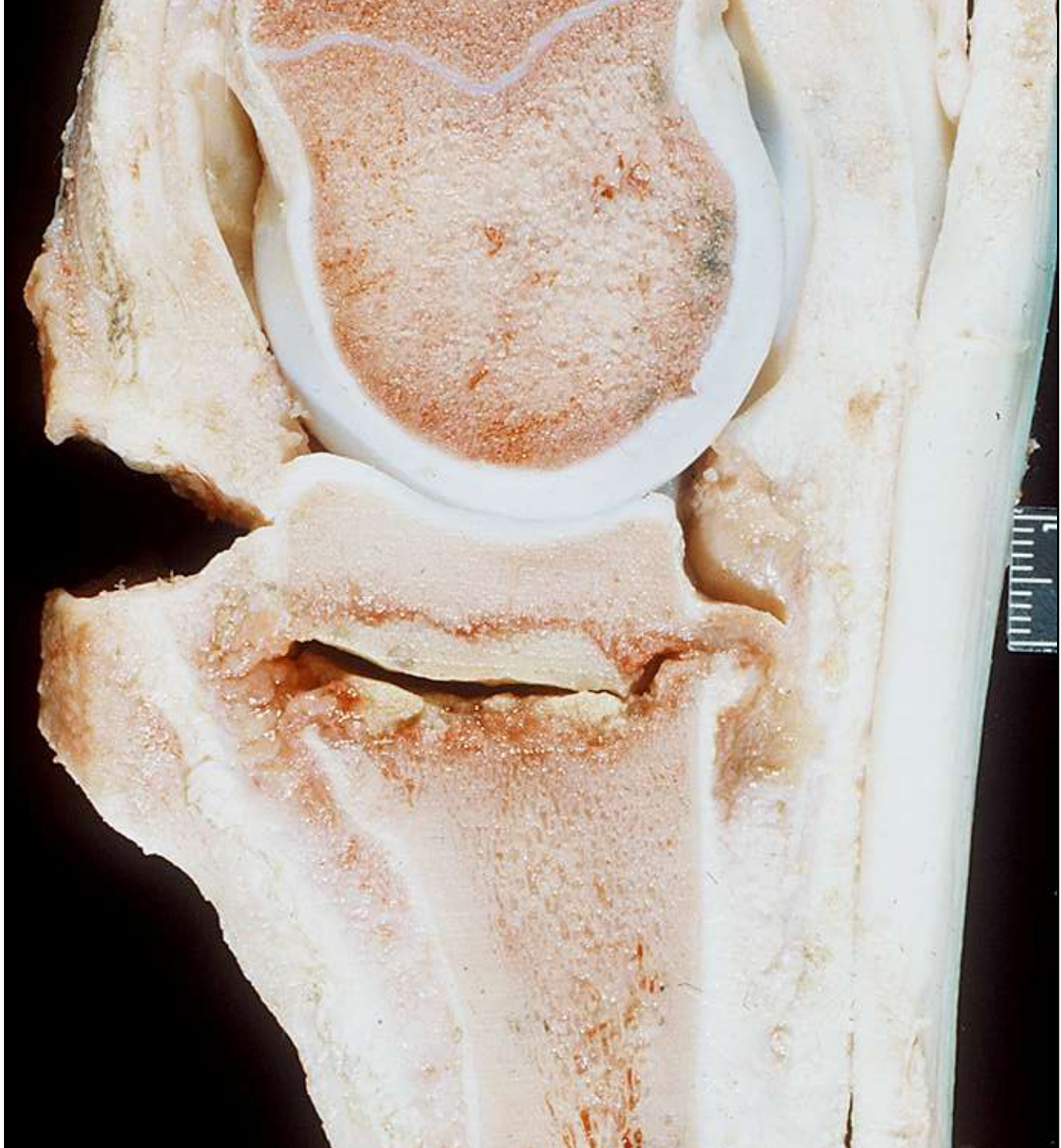Extension of Embolic Osteomyelitis to Periostitis and/or Arthritis



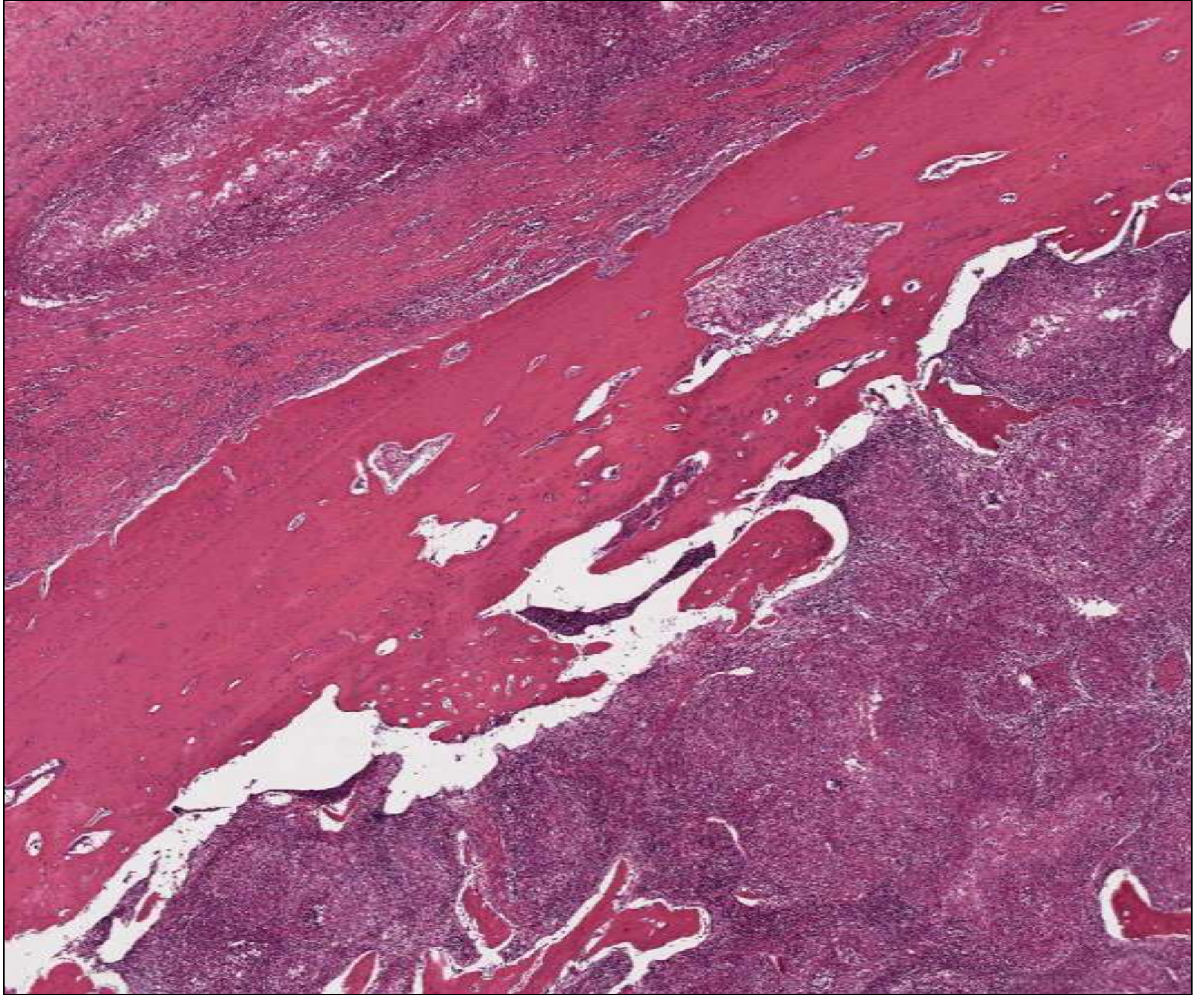
joint
cavity

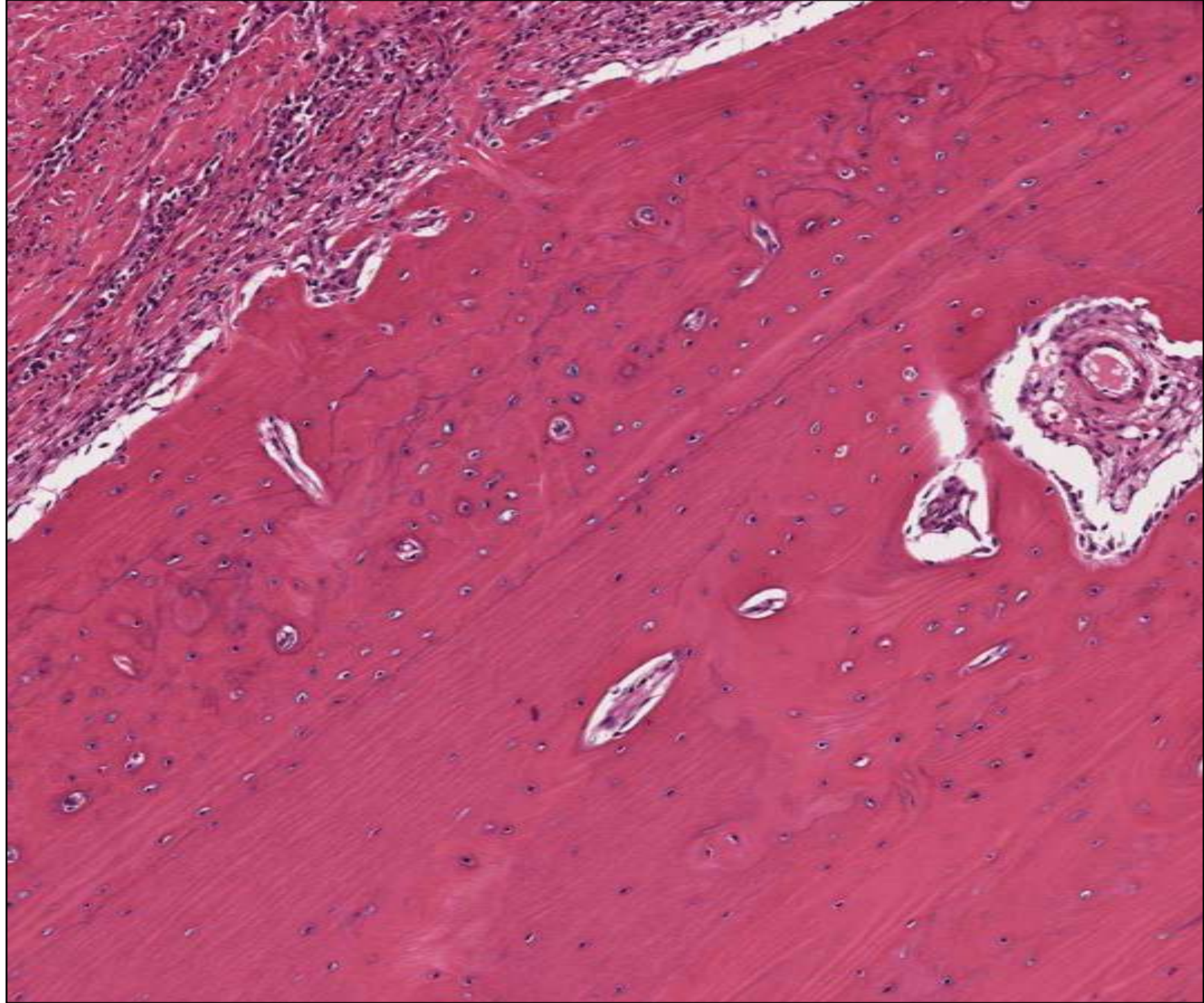
bone
abscess

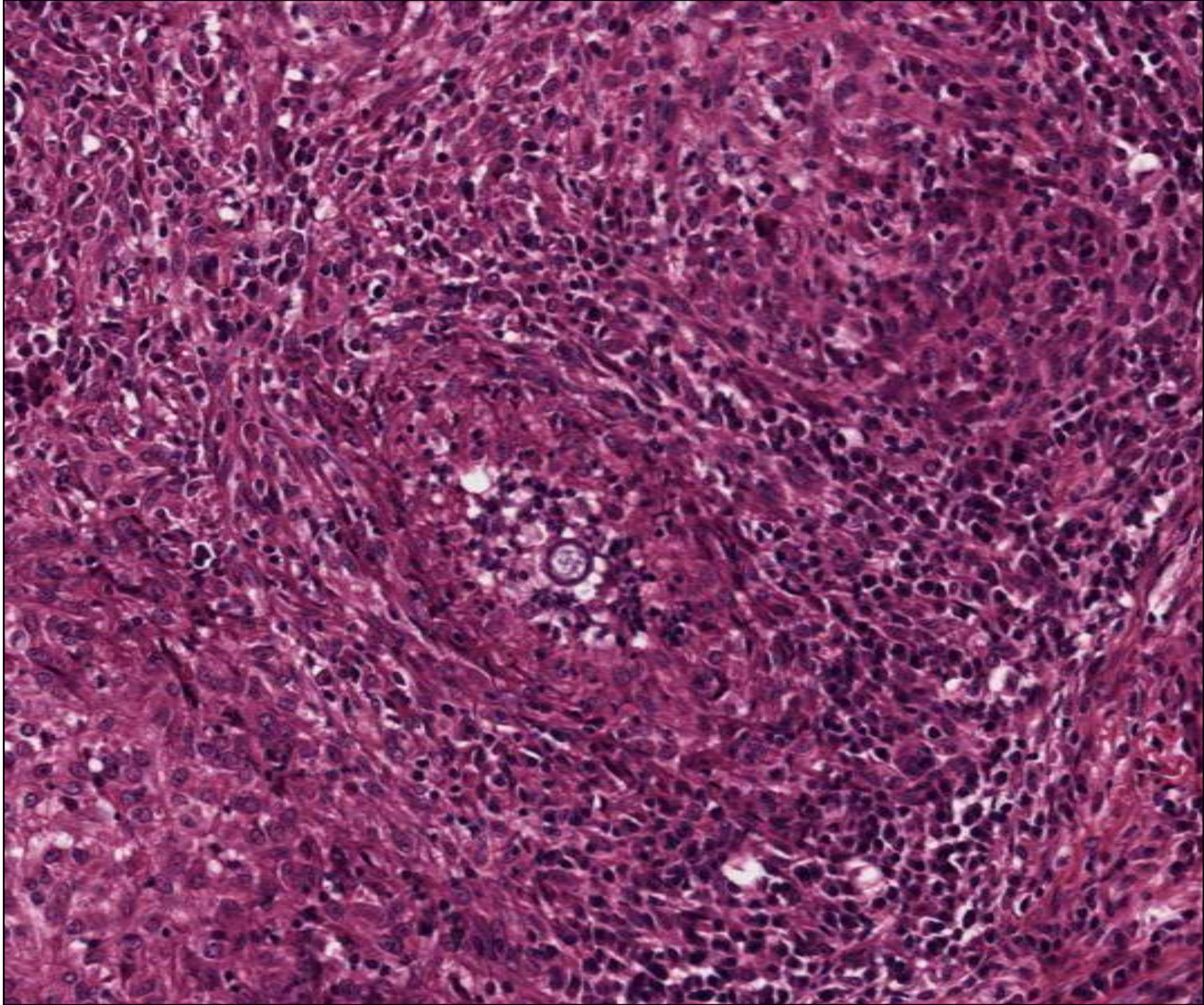
periosteum



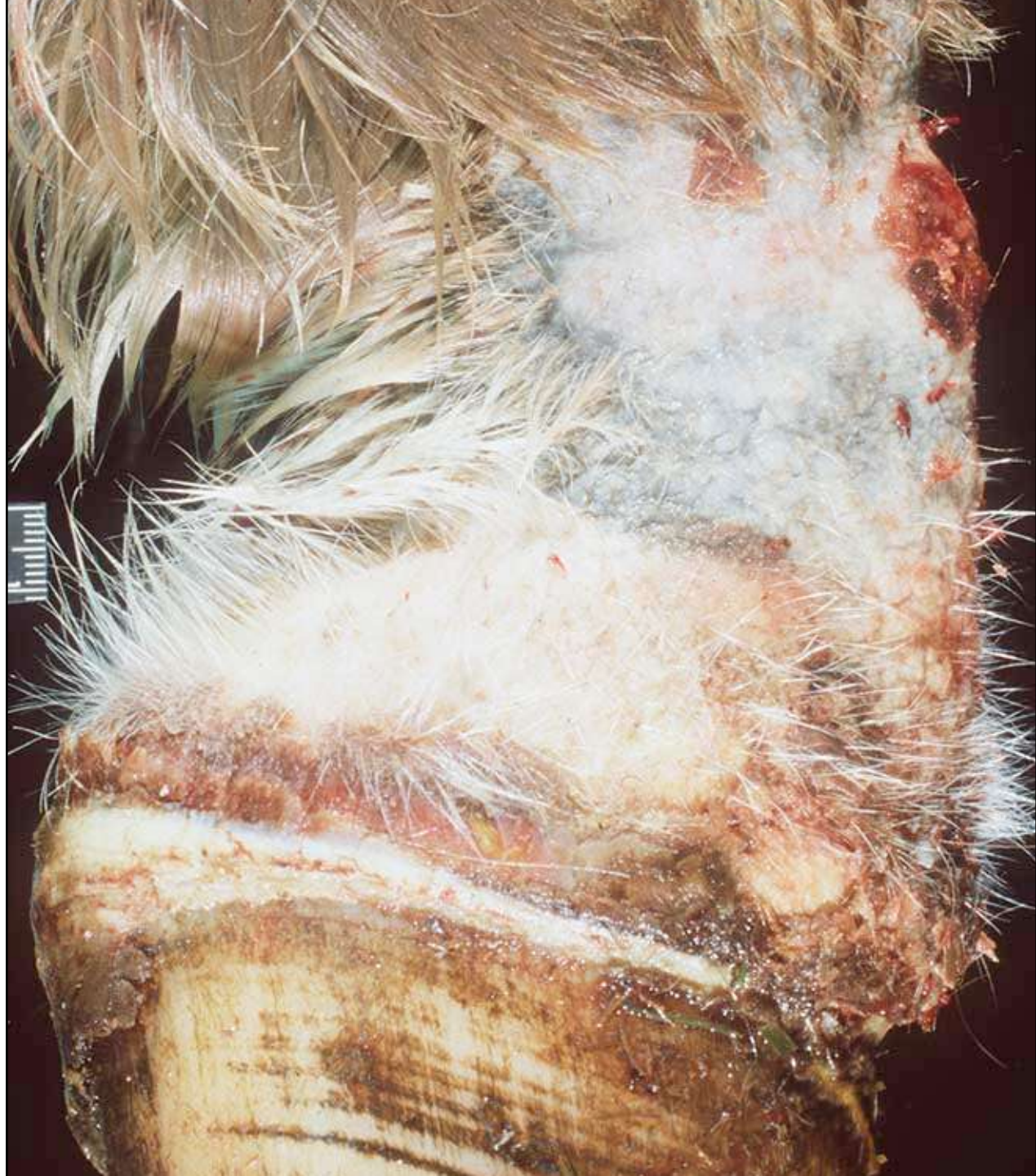
Embolic Yeast Fungal Osteomyelitis

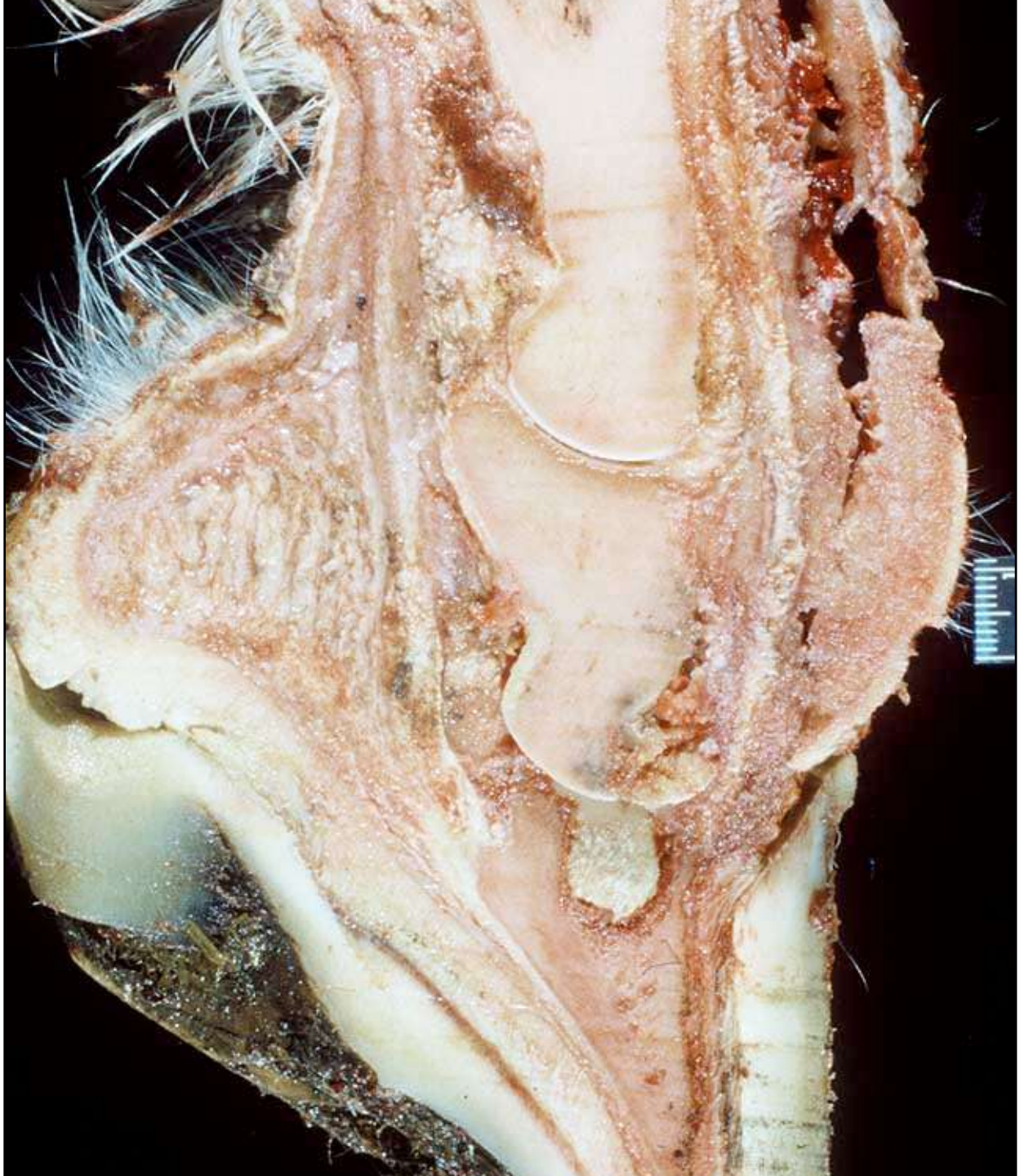


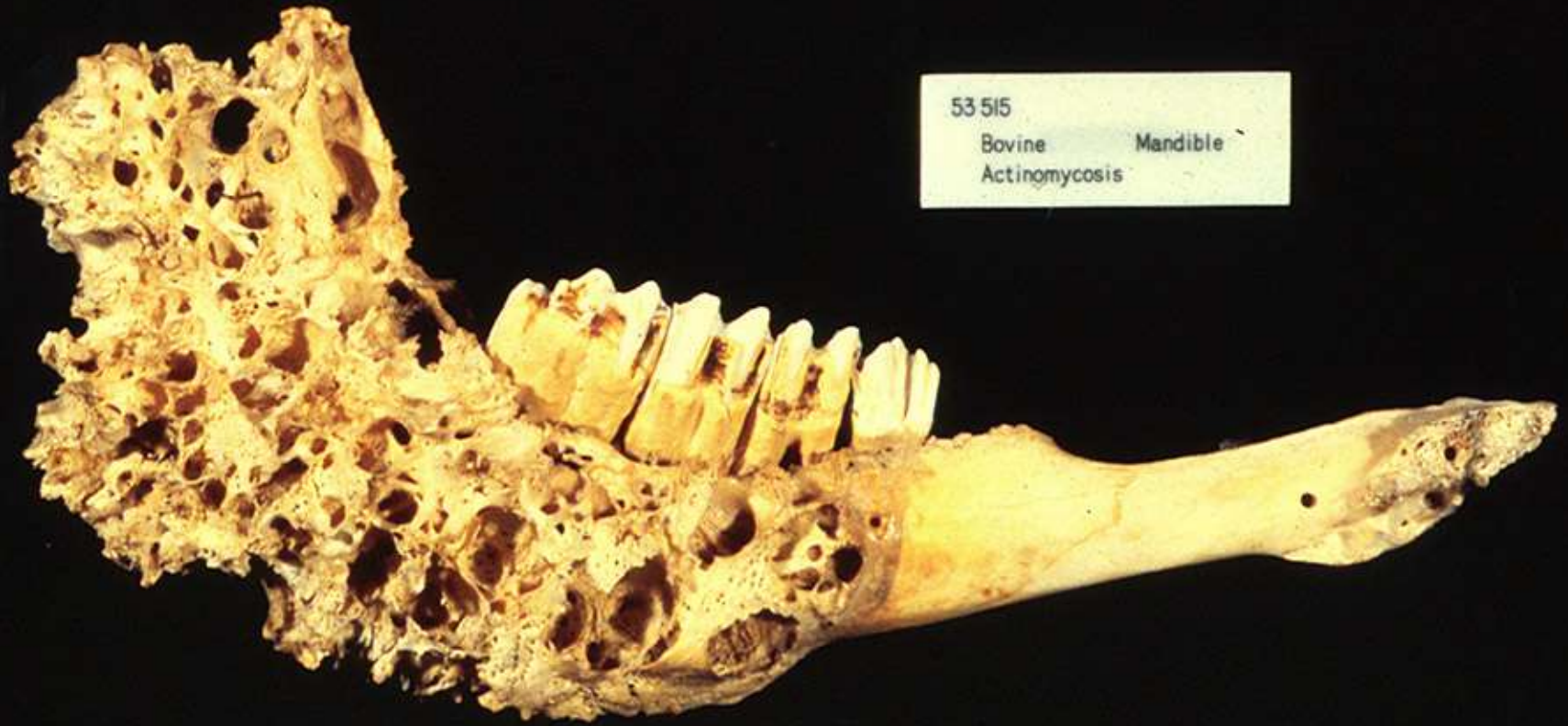



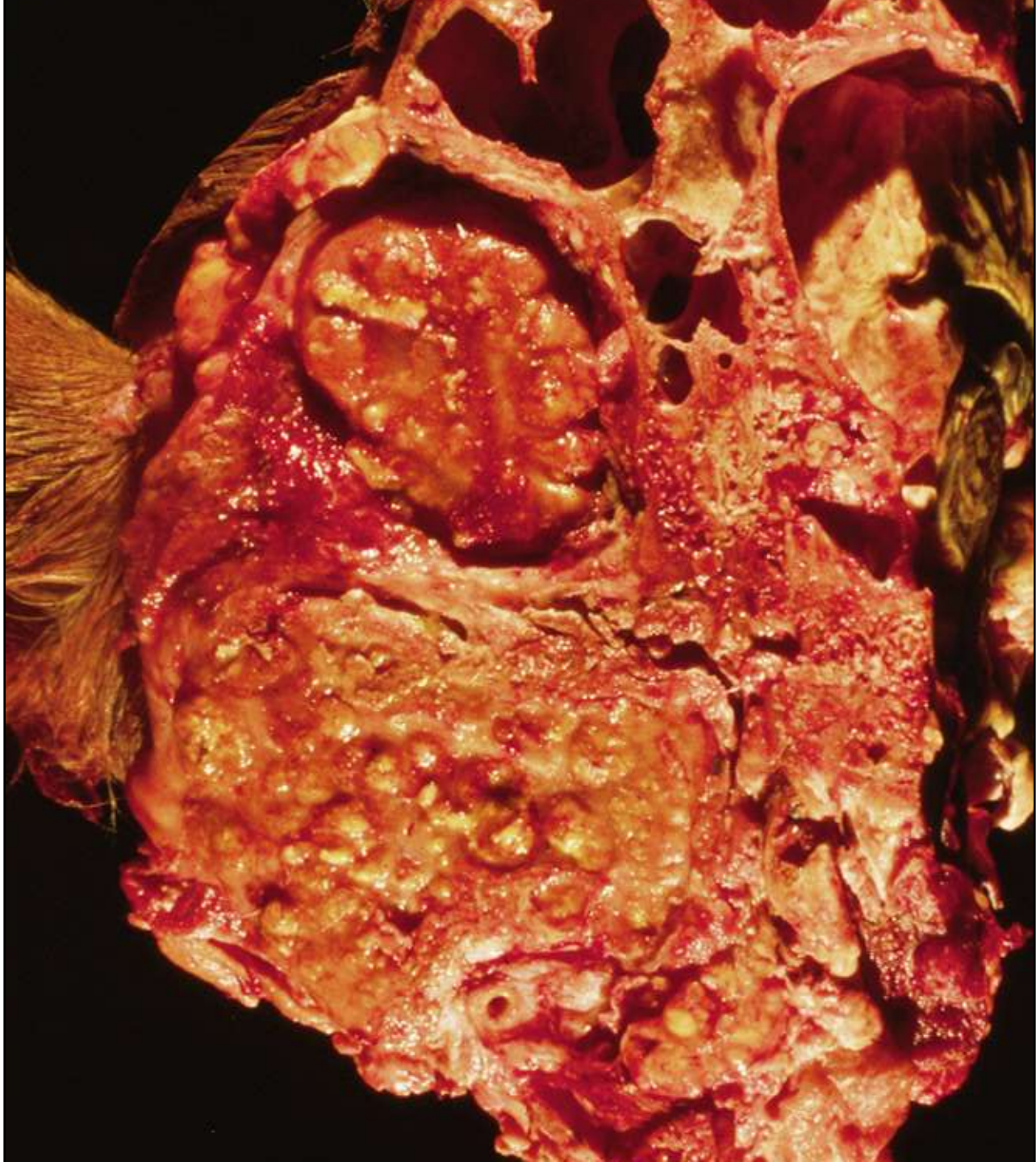
Osteomyelitis as sequela to
local trauma

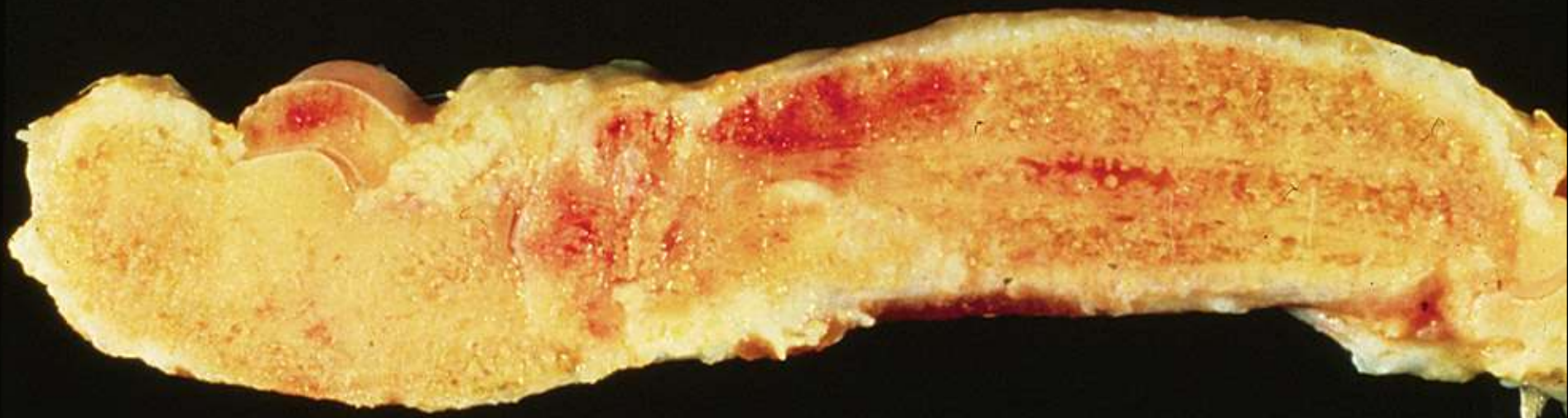


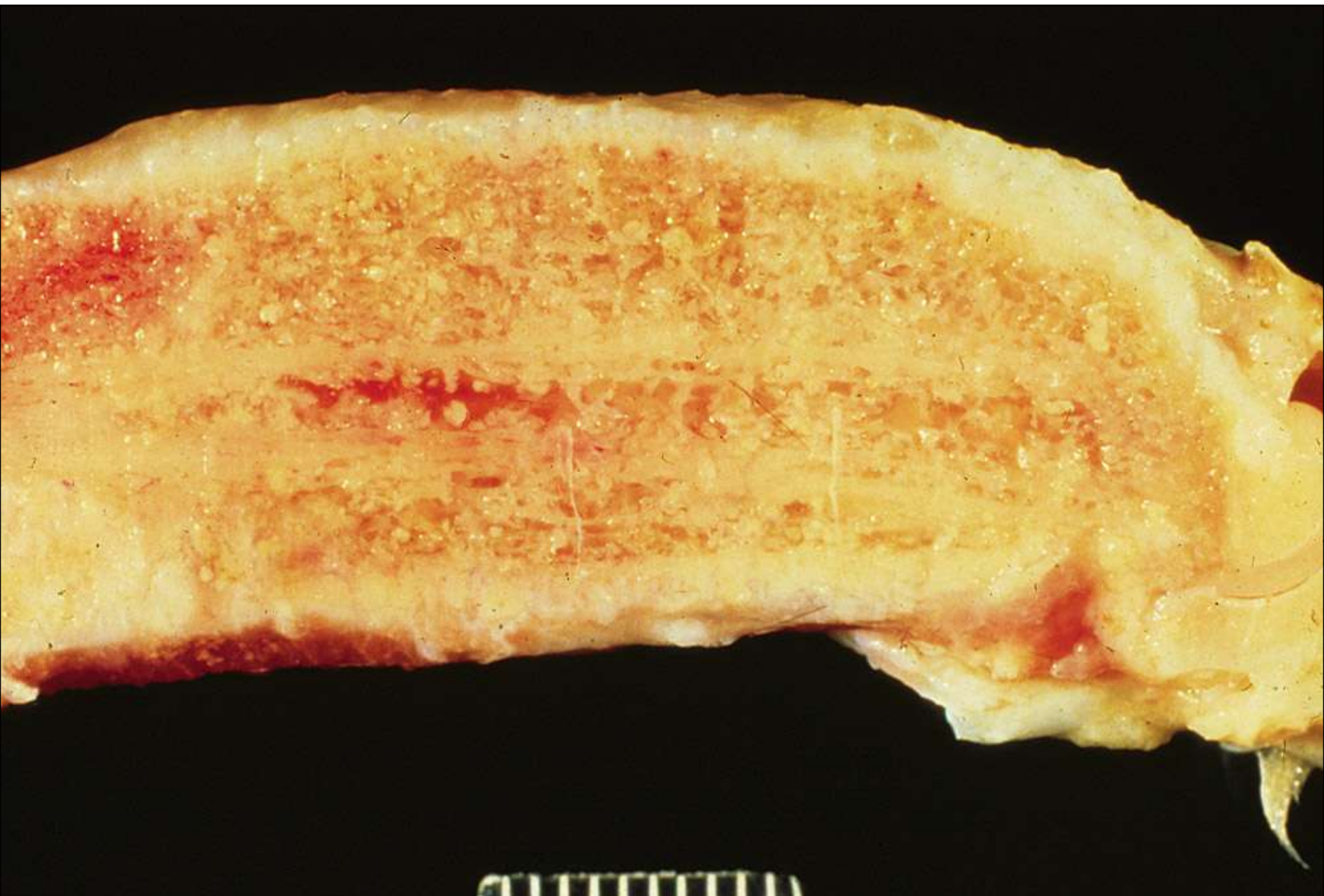
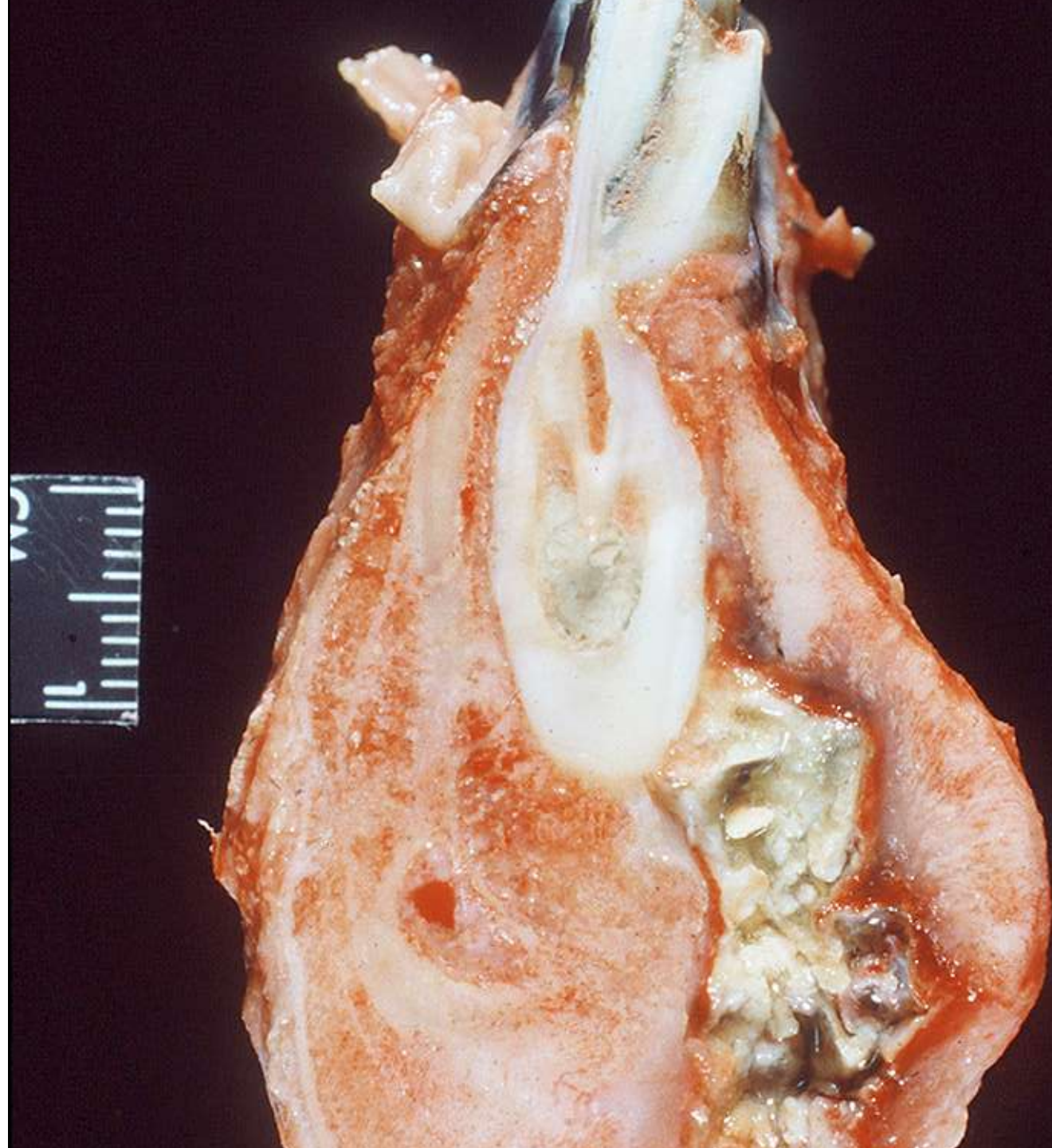


53 515
Bovine Mandible
Actinomycosis



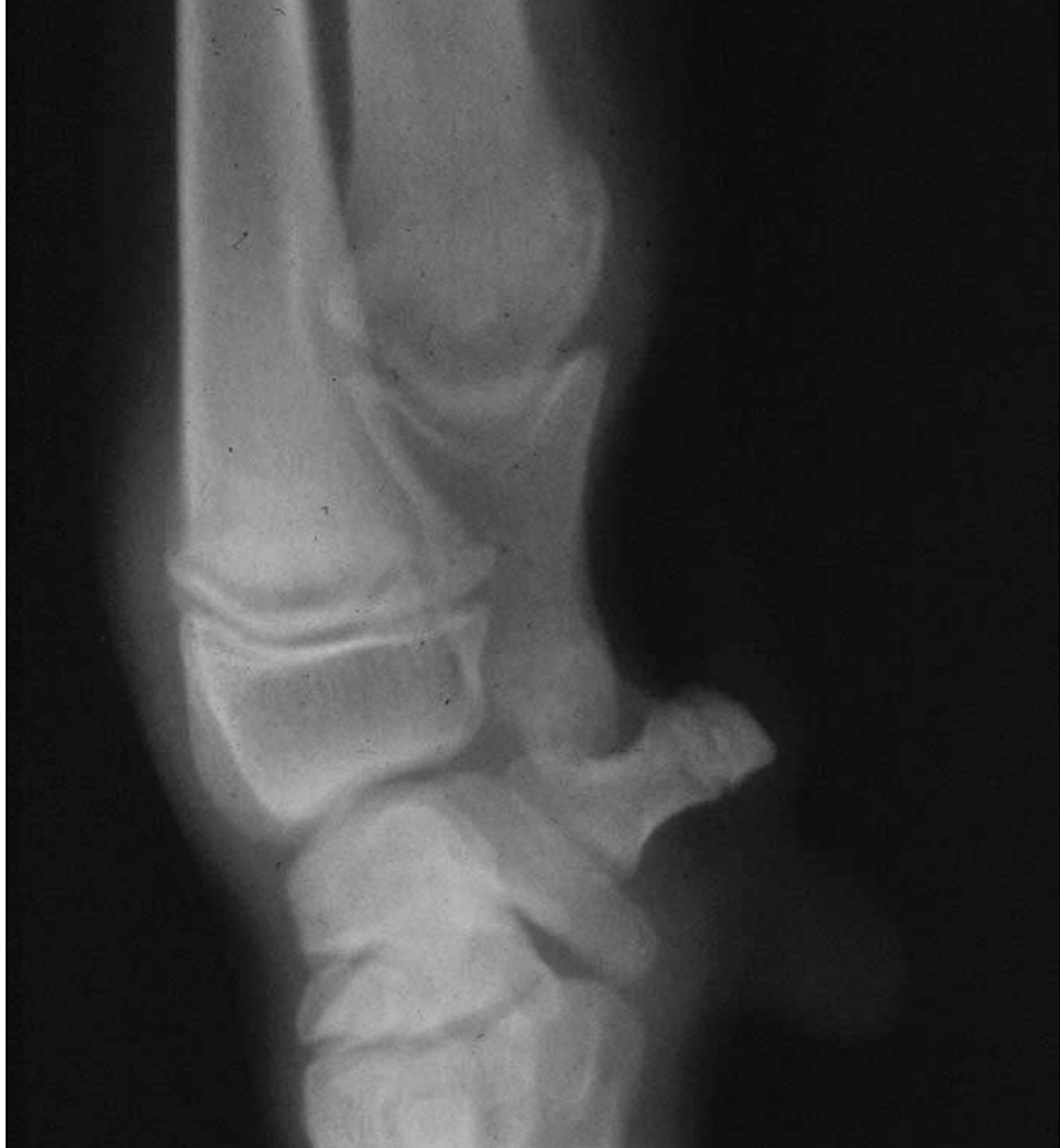


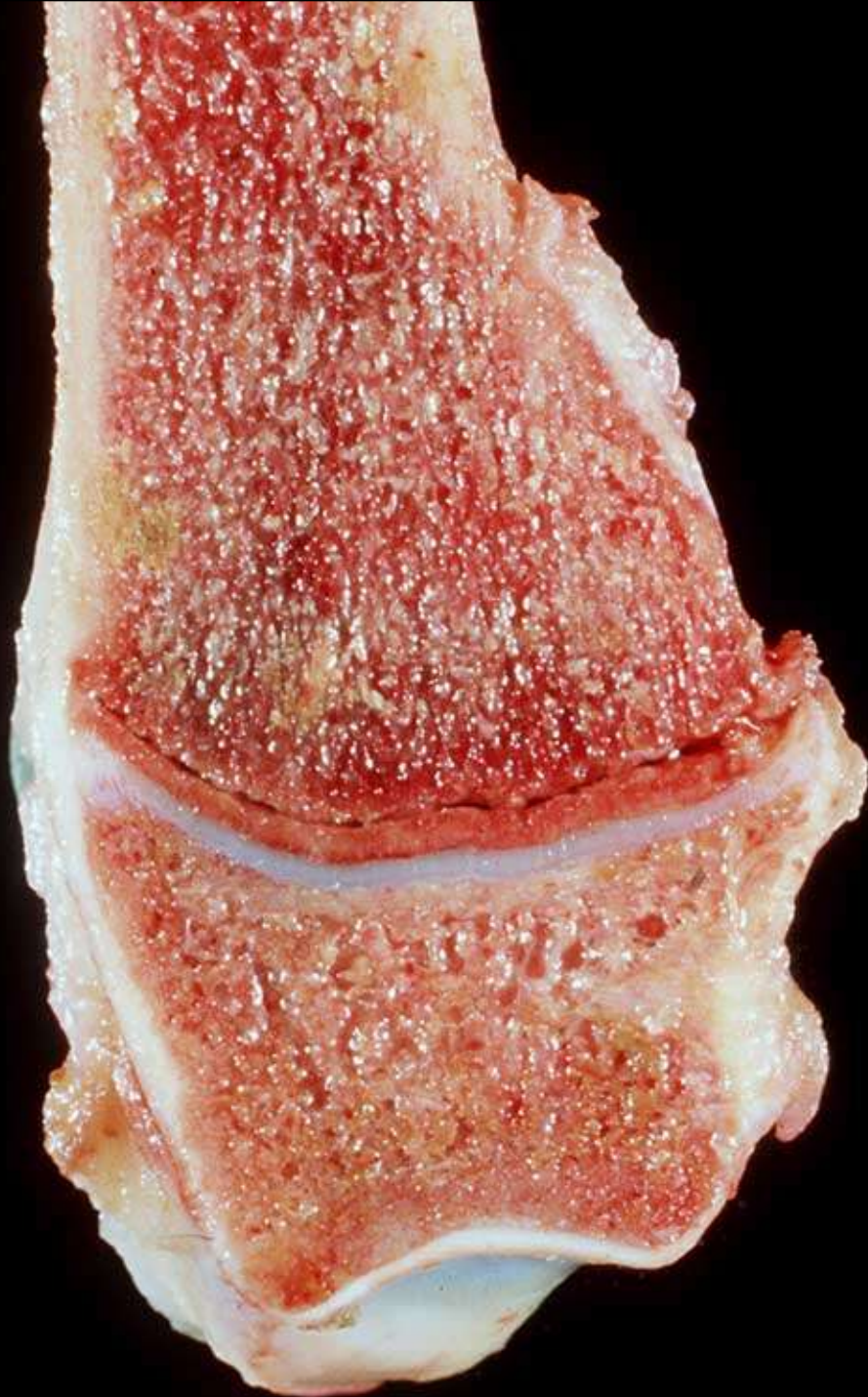


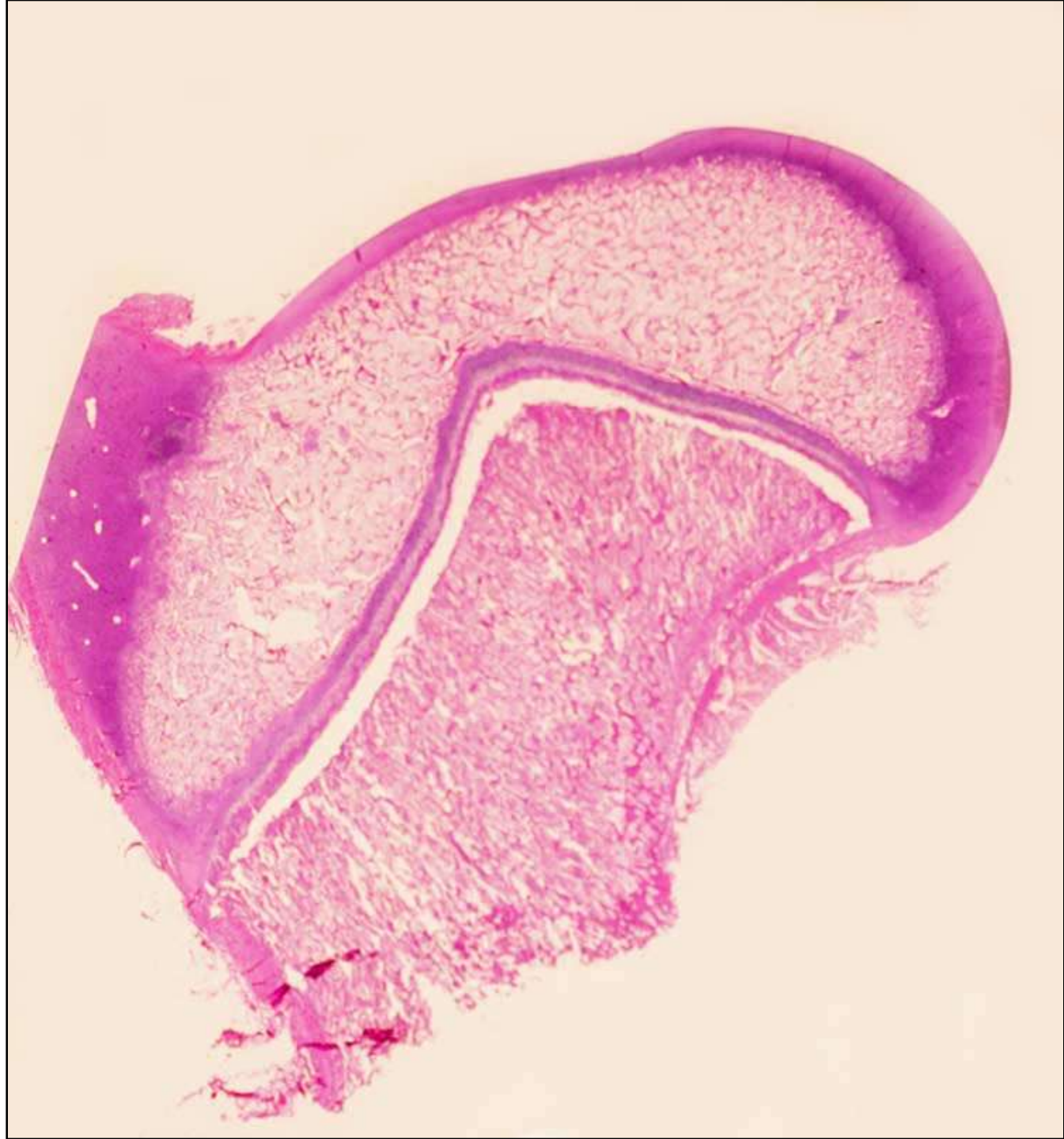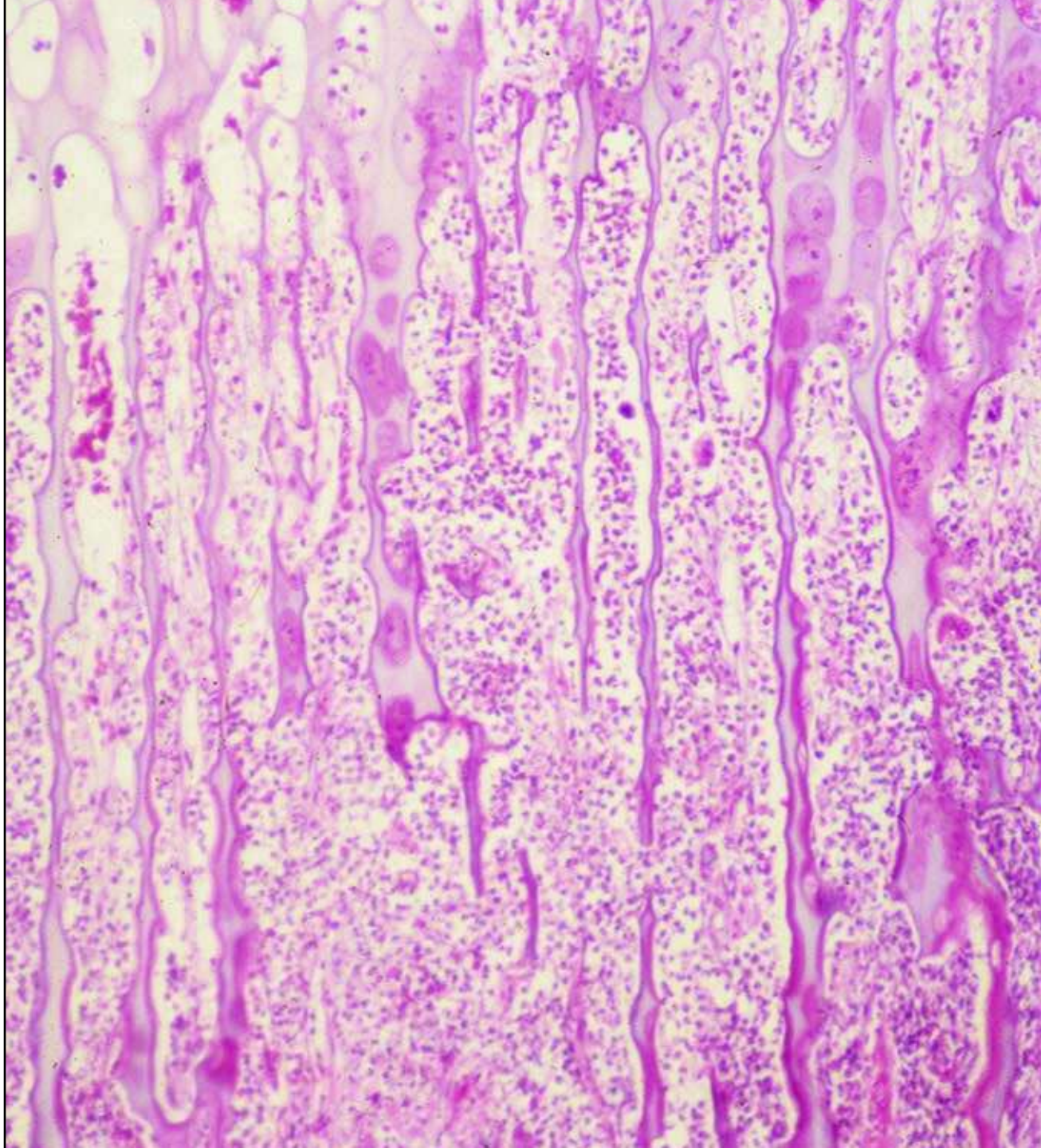
Non-infectious Osteomyelitis

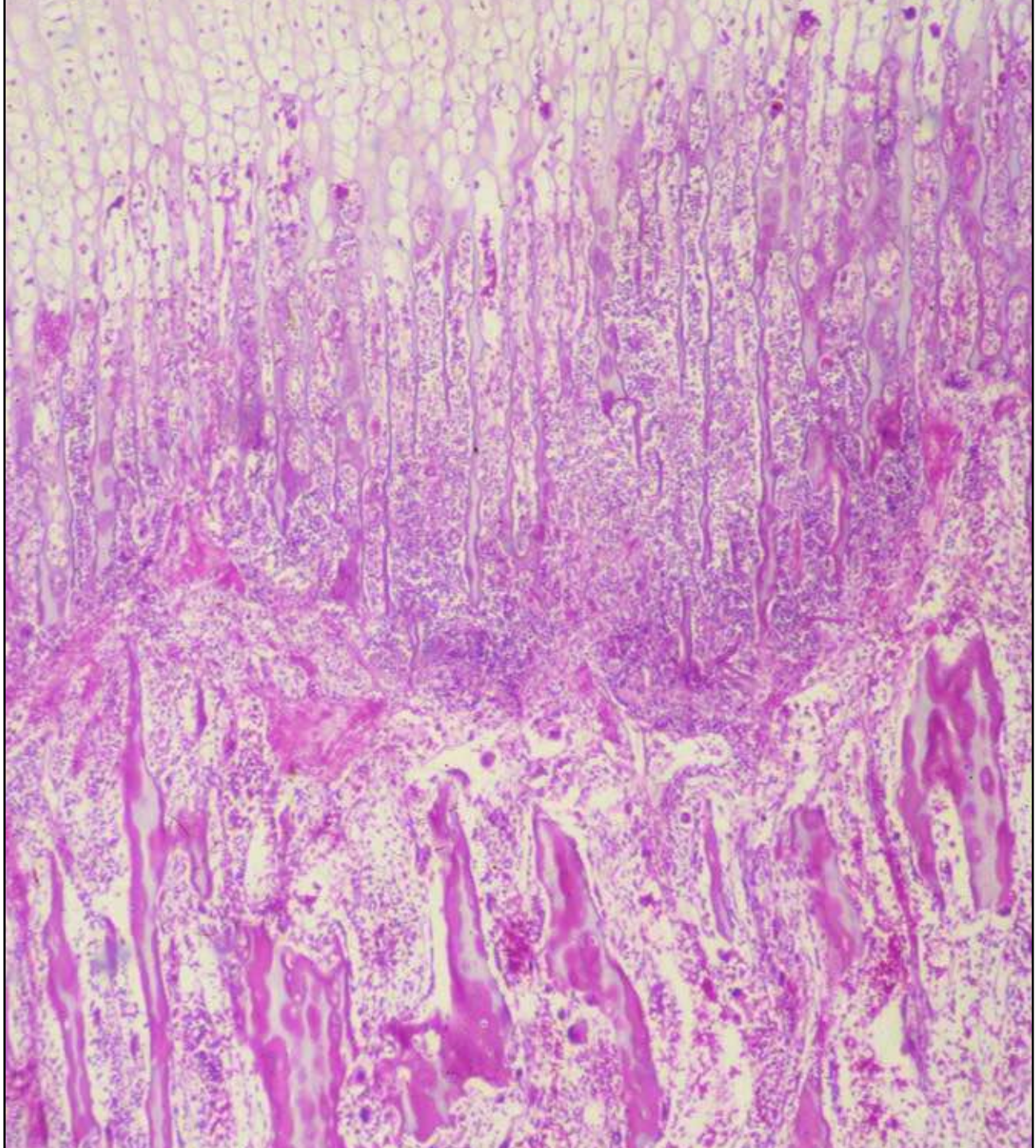
Acute Hypertrophic Osteodystrophy

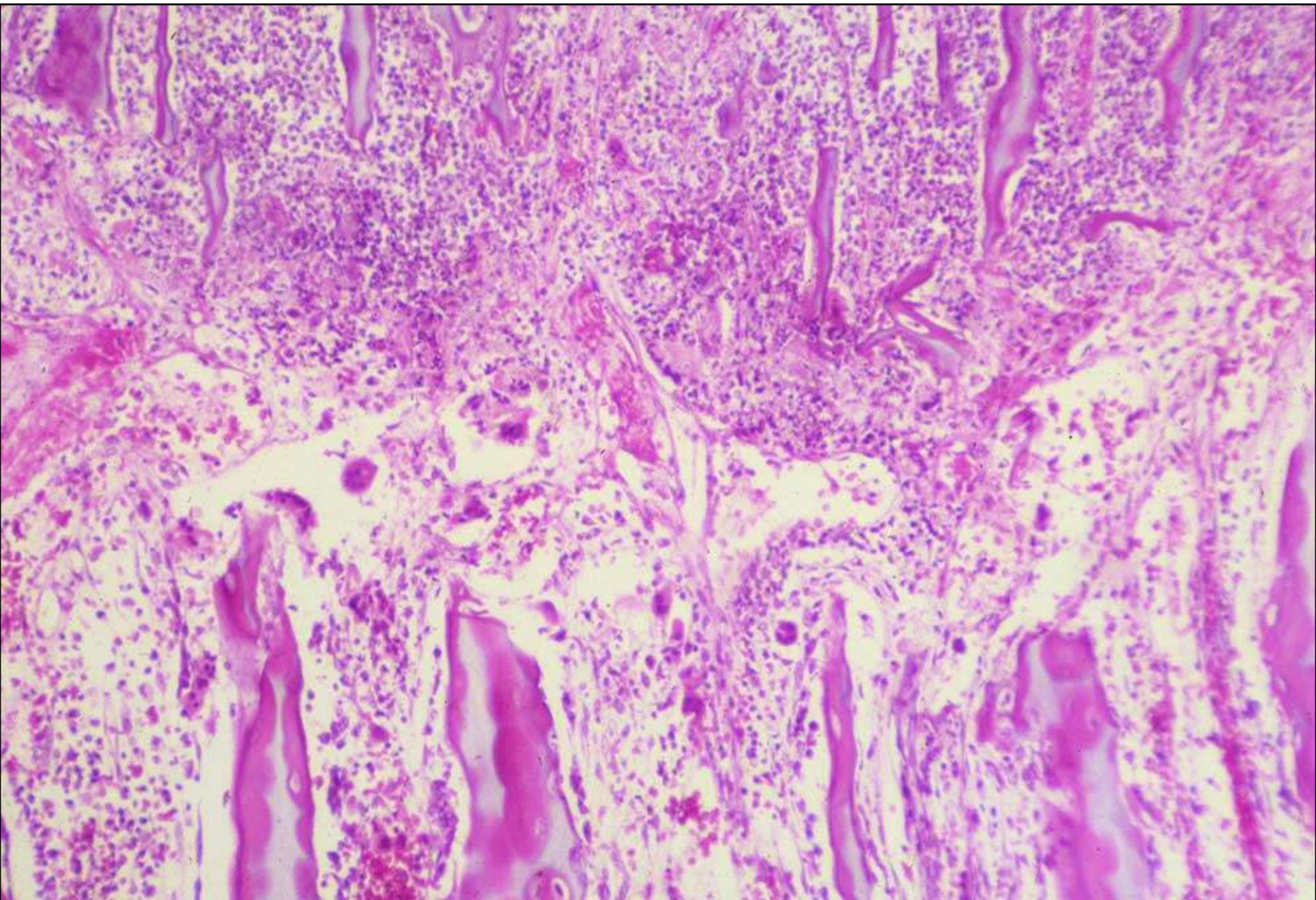












Chronic Hypertrophic Osteodystrophy

