

Pathology of Swine

**Dr. med. vet. Matti Kiupel, BS, MS, PhD,
DACVP**

**Diagnostic Center for Population and Animal Health
College of Veterinary Medicine, Michigan State University**

4125 Beaumont Road 152A, Lansing, MI 48910, USA

Tel.: ** 517 432 2670; Fax: ** 517 432 6557;

E-mail: kiupel@dcpah.msu.edu





Respiratory System

Diagnosis of Respiratory Diseases in Swine

- **Complete Necropsy on ACUTE pigs**
- **Submit both fixed and refrigerated samples:**
 - Lung, trachea, nasal turbinates
 - Brain, spleen, tonsil, liver, kidney, lymph nodes,
 - Serum
- **Serology: coincident seroconversion**

Gross Examination of the Lung

Distribution

- **Diffuse** ⇒ vascular or viral
- **Dispersed multifocal** ⇒ vascular and/or embolic
- **Lobular** ⇒ airway, segmental
- **Cranioventral** ⇒ dependent
- **Hilar** ⇒ App

Gross Examination of the Lung

Color

- **Pink** \Rightarrow blood + air = normal
- **Purple** \Rightarrow blood - air = atelectatic
- **Red** \Rightarrow blood (congestion or hemorrhage)
- **Red spots or blotches** \Rightarrow hemorrhages
- **White** \Rightarrow WBC (Pus), Fibrin, Albumin

Gross Examination of the Lung

Consistency

- **Soft, resilient** ⇒ normal
- **Fluctuant** ⇒ edematous
- **Firm, resilient** ⇒ fibrinous
- **Firm, unyielding** ⇒ cellular infiltrates
- **Hard, unyielding** ⇒ scarring
- **Crepitant** ⇒ emphysema

Gross Examination of the Lung

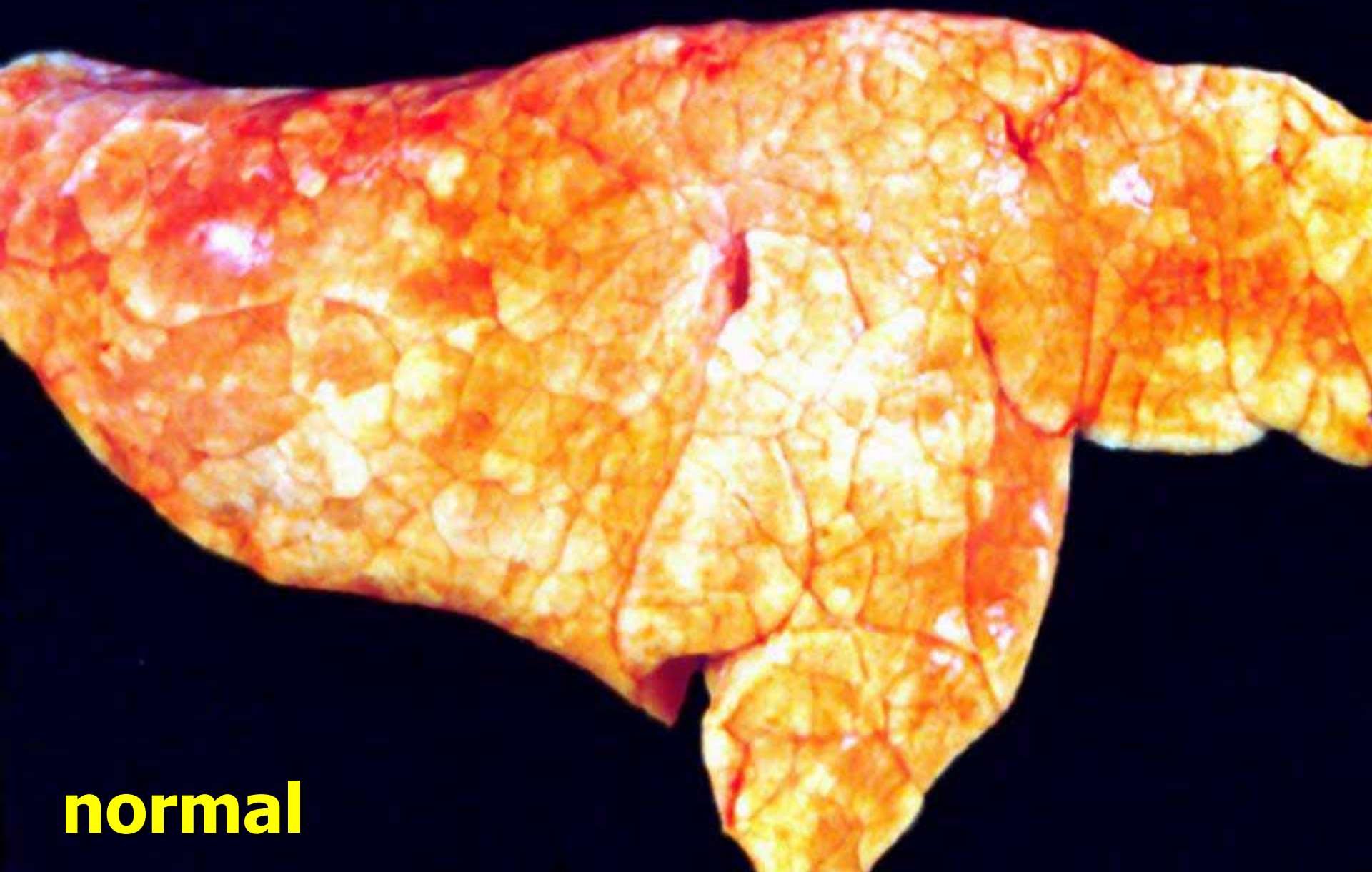
Cross-Section

- **Dry, friable** ⇒ necrosis
- **White interlobular septae** ⇒ fibrin
- **White grape-like clusters** ⇒ pus in alveoli
- **Red blotches (interlobular septae)** ⇒ hemorrhage
- **Glistening stringy clear or white material in airways** ⇒ mucous +/- WBC

Gross Examination of the Lung

Integration

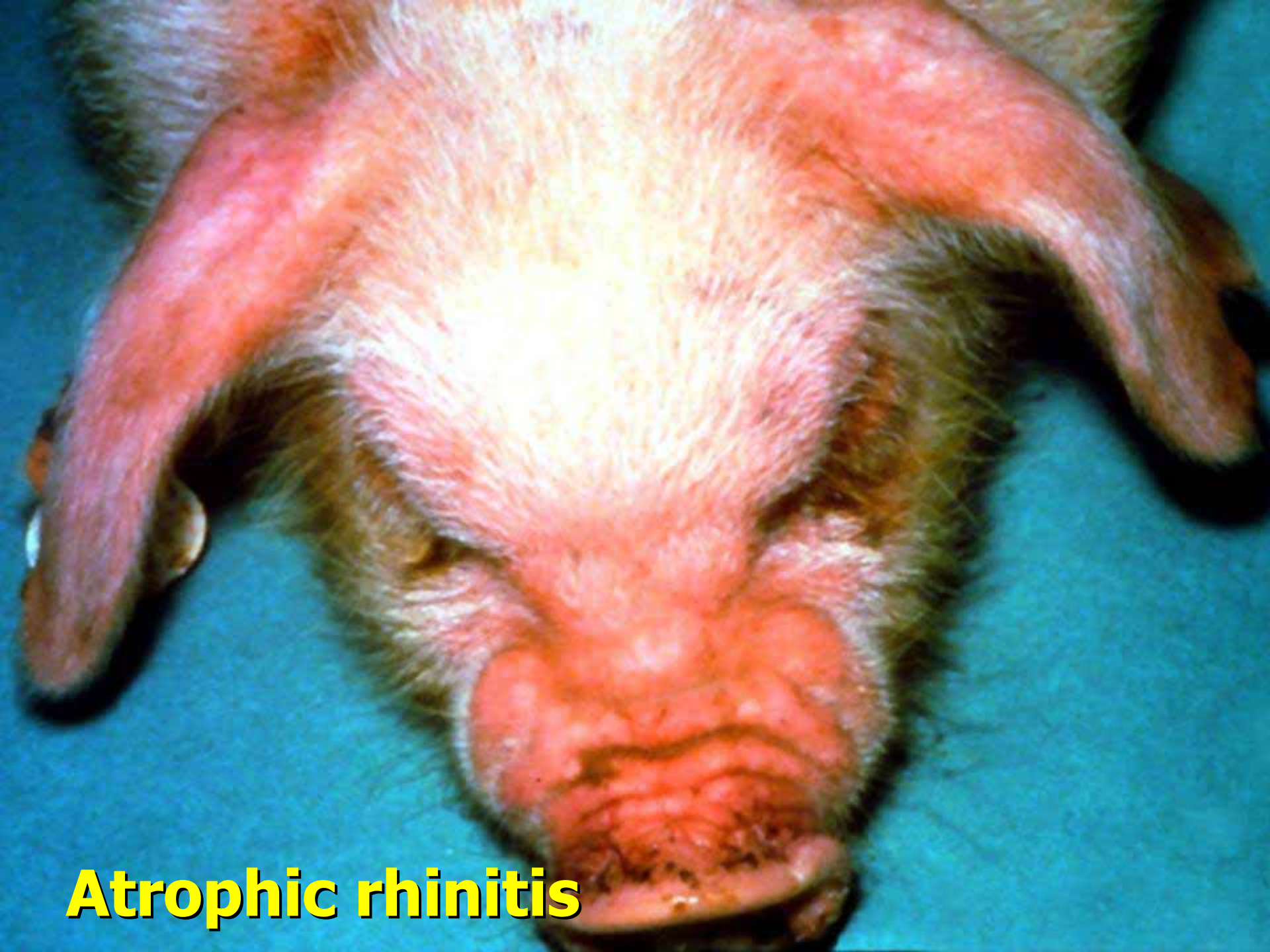- Lesions in lungs \Rightarrow differentials
- Lesions in other organs \Rightarrow differentials
- One disease? Systemic disease?
- Multiple diseases?
- Adequate samples?



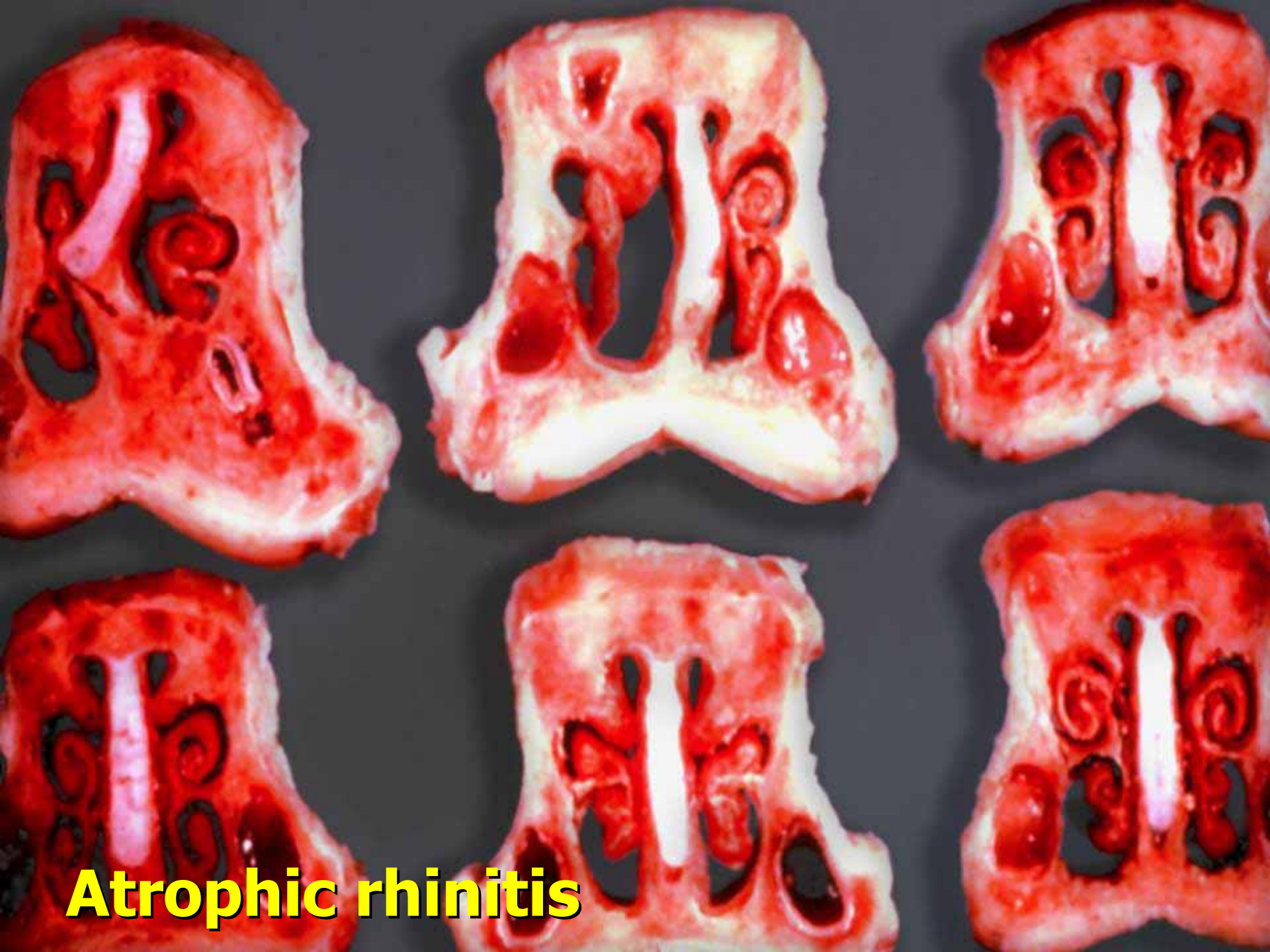normal

Progressive atrophic rhinitis

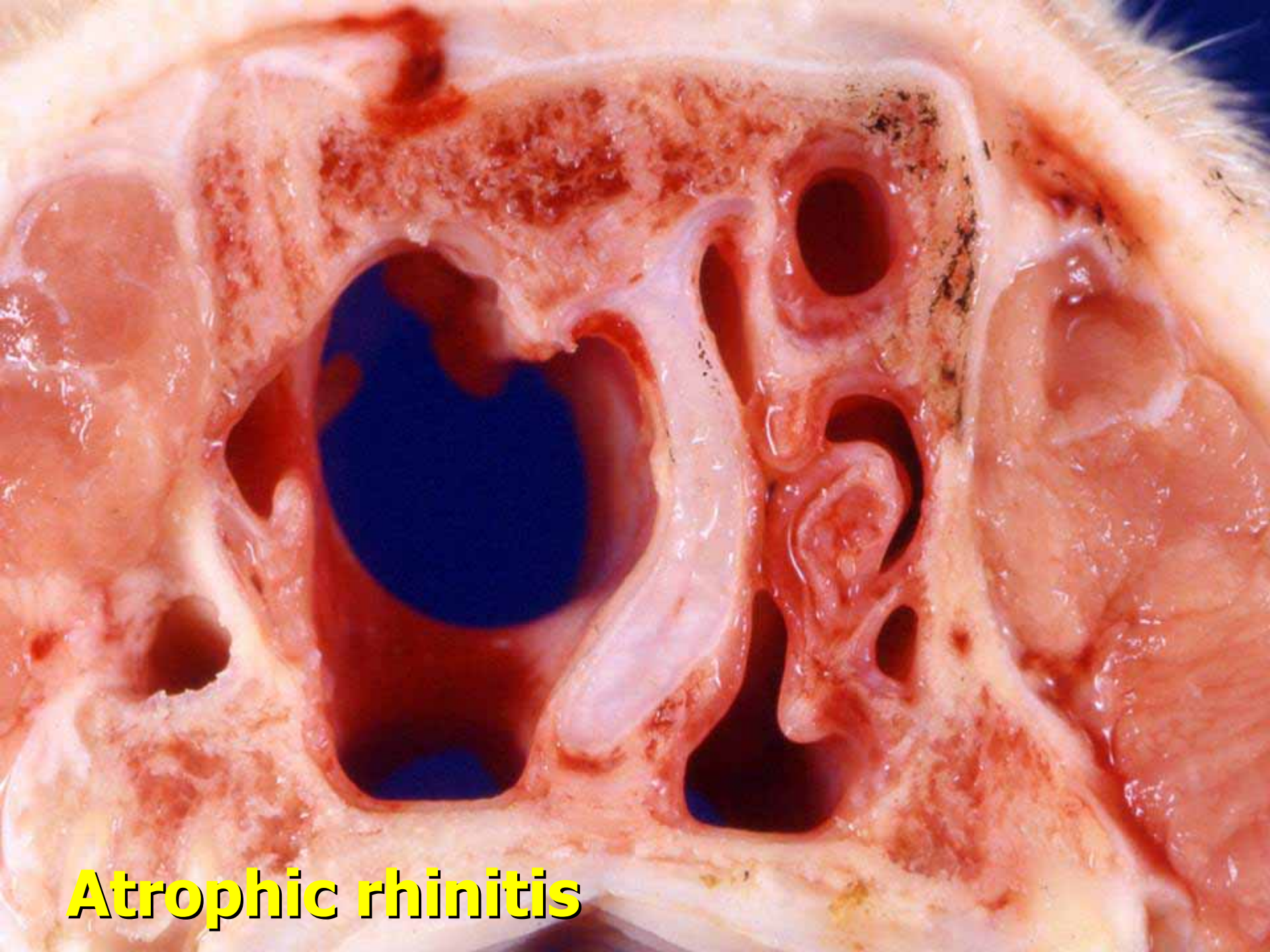
- Toxigenic *P. multocida* (usually type D)
+/- co-infection with *B. bronchiseptica*
- *P. multocida* produces dermonecrotxin > demise of osteoblasts > enhanced osteoclast activity > turbinate atrophy > distortion of nasal septum > possibly shortening and twisting of upper jaw
- Clinical signs: Sneezing (1-8 weeks of age)
+/- epistaxis, blockage of lachrymal ducts with tear staining, mucopurulent nasal discharge, shortening of upper jaw and corrugation of the skin of snout
- Pathology: Rhinitis, turbinate atrophy and nasal distortion
- Diagnosis: Clinical signs confirmed by culture of nasal swab for toxigenic *P. multocida*



Atrophic rhinitis



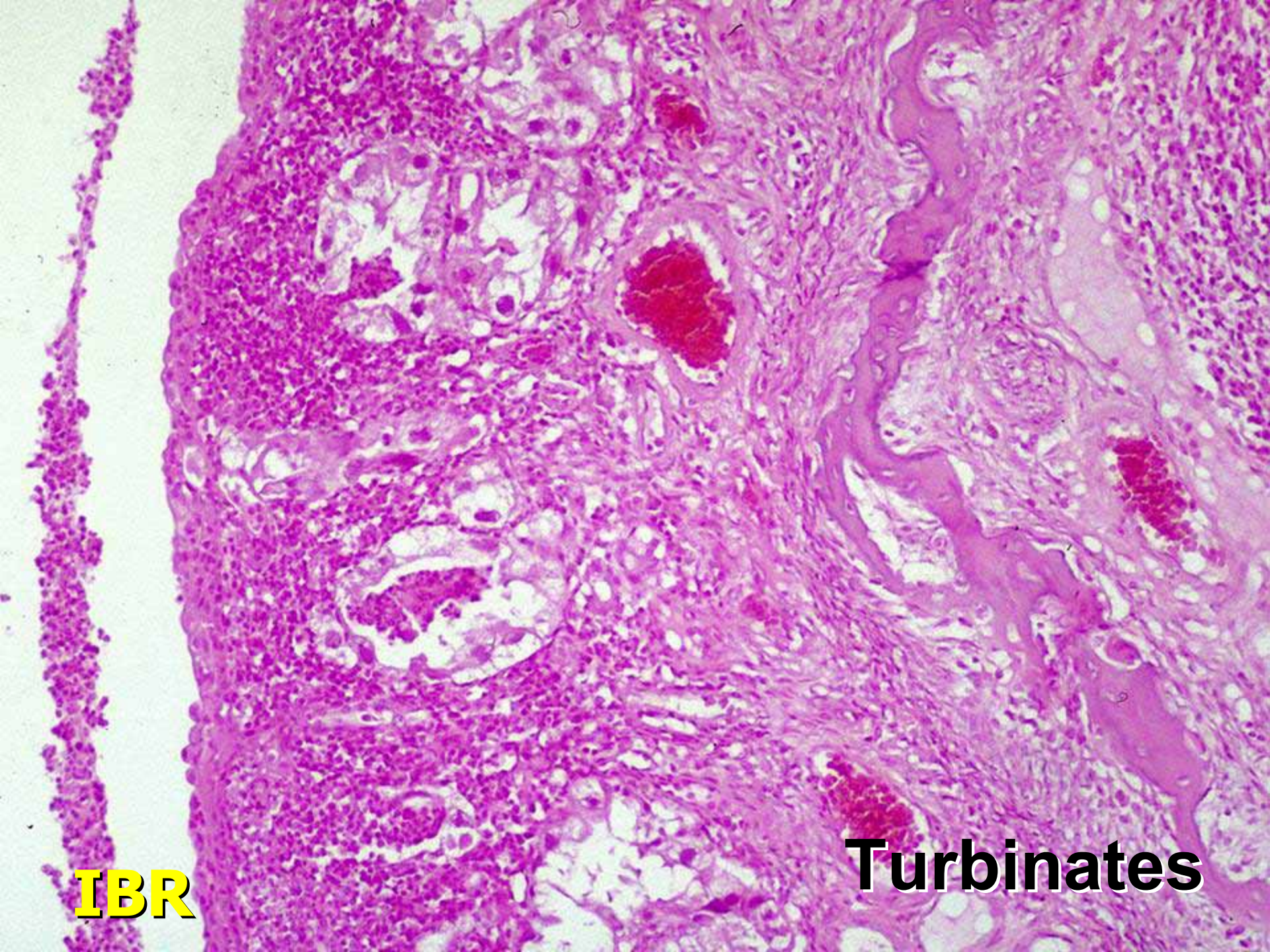
Atrophic rhinitis



Atrophic rhinitis

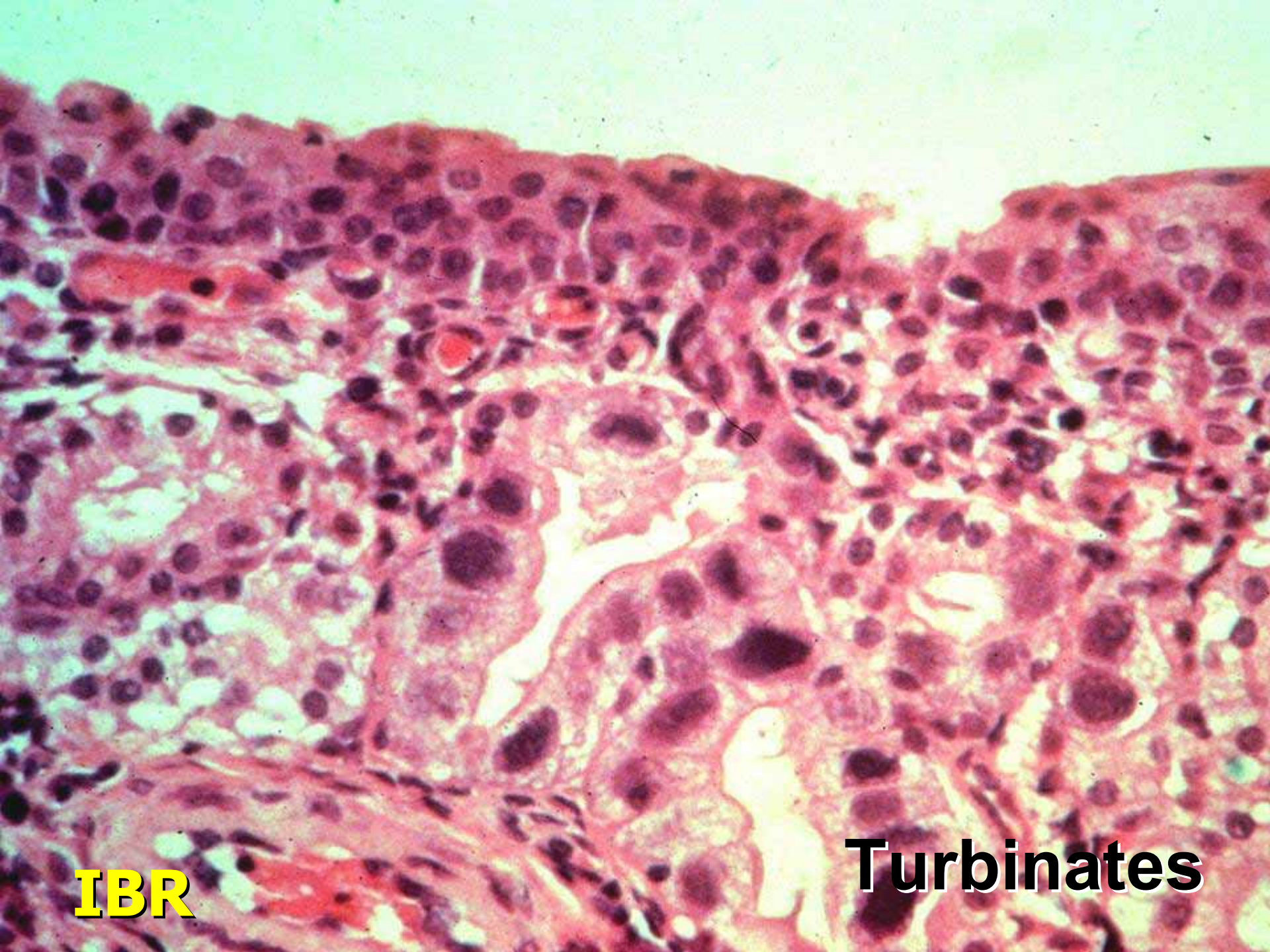
Inclusion body rhinitis

- **Etiology: Porcine cytomegalovirus**
- **Clinical signs: Sneezing in pigs <3 weeks of age, nasal discharge and epiphora. If chronic, may lead to otitis media**
- **Pathology: Rhinitis and conjunctivitis**
- **Diagnosis: Turbinates plugged with mucus/debris, basophilic intranuclear inclusion bodies in nasal mucosa**
- **If herd is naïve, (eg. a new herd) any age can be affected and 25% mortality in affected litters may be seen**



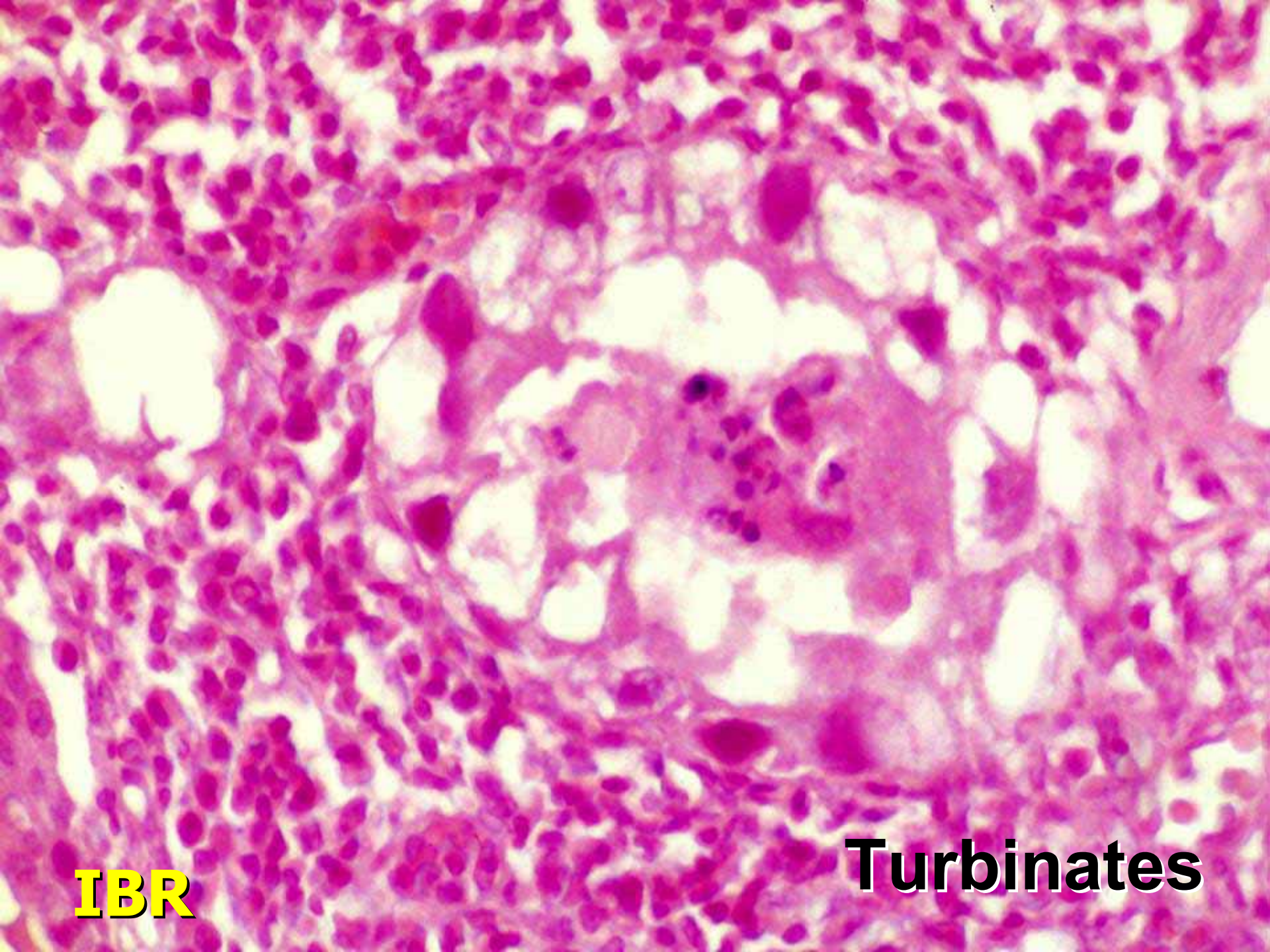
IBR

Turbinates




IBR

Turbinates

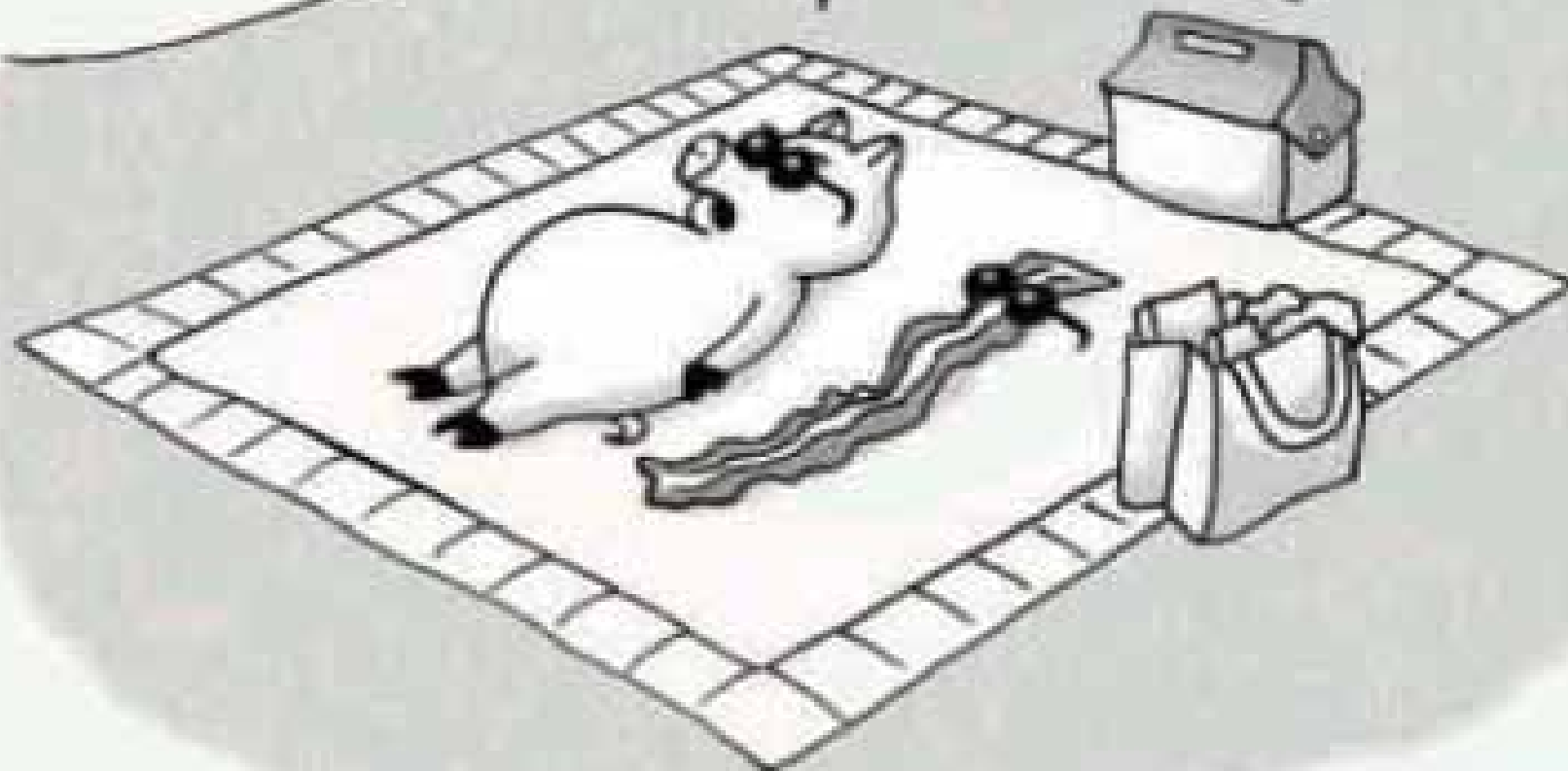


IBR

Turbinates



MAYBE NEXT TIME YOU'LL
TRY A LITTLE SUNSCREEN...



Interstitial Pneumonia in Swine

- **Viral**

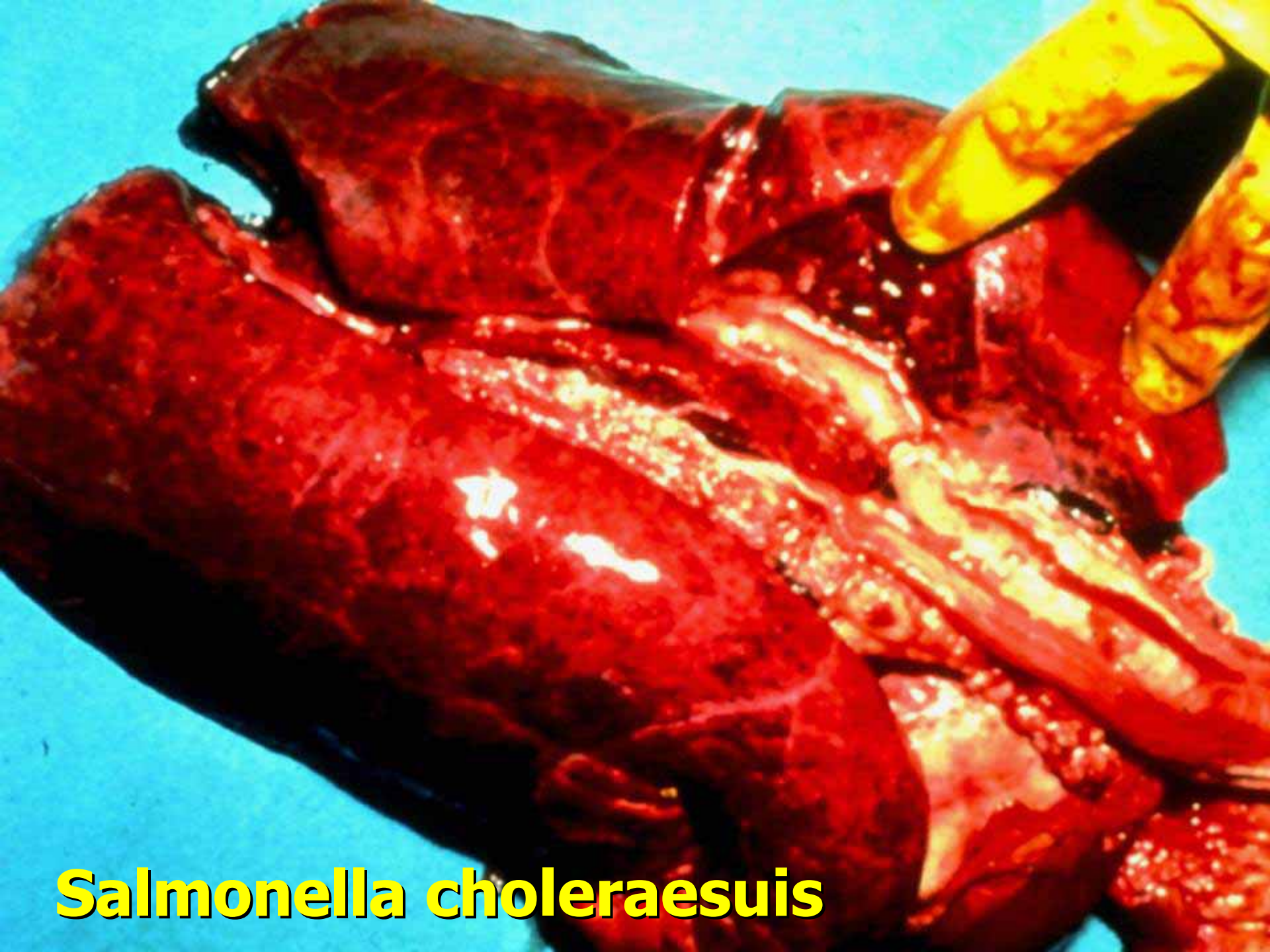
- Swine influenza
- Pseudorabies
- PRRSV
- PRCV
- Porcine
Circovirus

- **Septicemia**

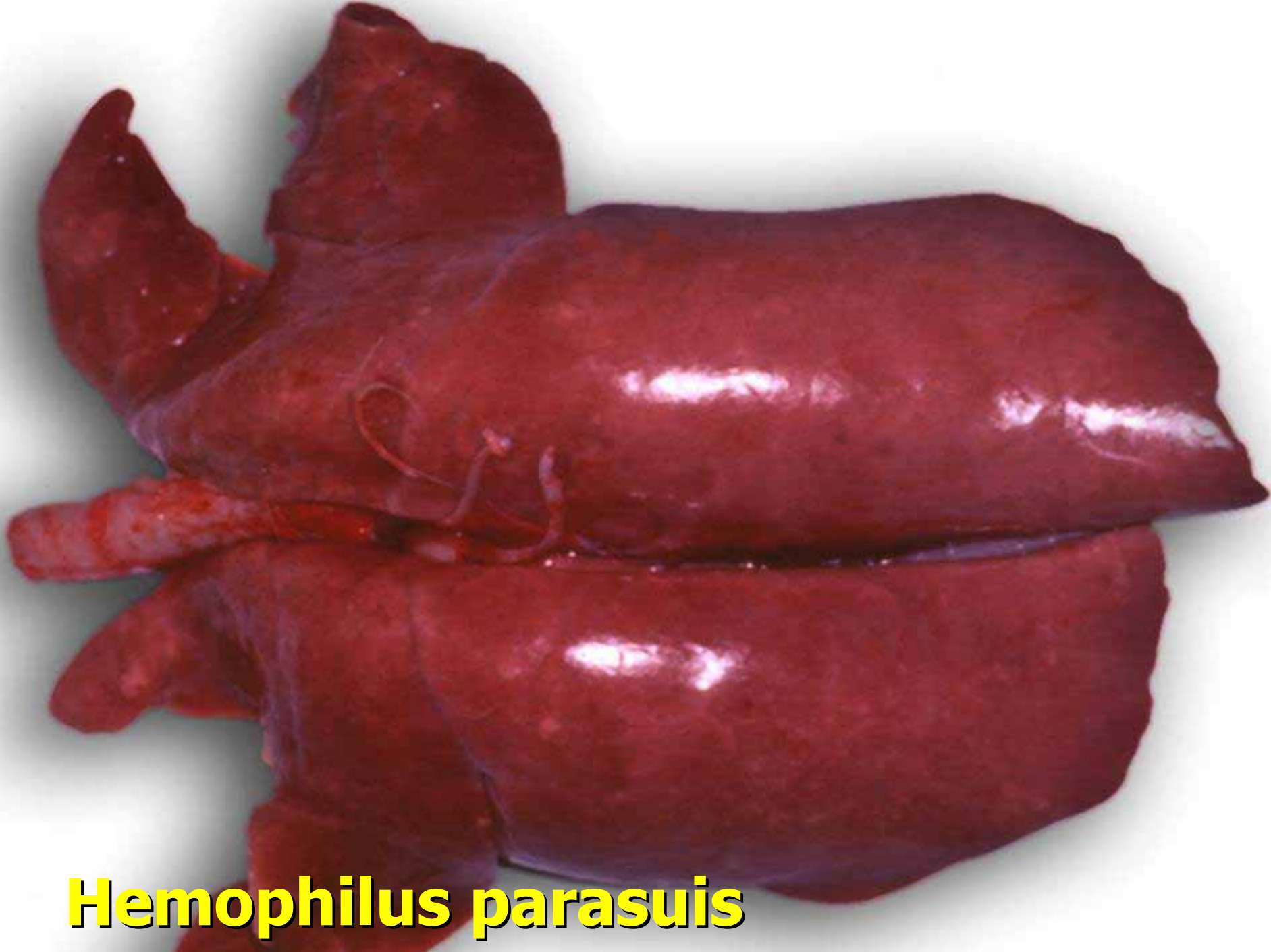
- *S. cholerasuis*
- *H. parasuis*
- *S. suis*
- Other

- **Allergic**

- Ascarid larval
migration



Salmonella choleraesuis



Hemophilus parasuis

Influenza A

- **Enveloped, negative sense RNA viruses that encode 10 major viral proteins on 8 independent segments of RNA**
- **Two major structural proteins (determine A, B, C):**
 - Nucleoprotein
 - M1 matrix protein
- **Envelope glucoproteins:**
 - Hemagglutinin (H) – 15 subtypes
 - Neuraminidase (N) – 9 subtypes
- **Historically only limited number of subtypes in mammals**
- **Subclinical infection of waterfowl with all subtypes**

Swine Influenza

- Epizootic and endemic form
- Replicates in:
 - Epithelium of small airways within 2 h
 - Epithelium of nasal cavity, trachea, alveoli by 24 h > alveolar macrophages
- Small bronchi blocked by neutrophil-rich exudate
- Alveolar necrosis/bronchial epithelial hyperplasia causes clinical signs
- Type A
 - H1N1 later H3N2
 - also H1N2, H4N6

SIV Induced Disease

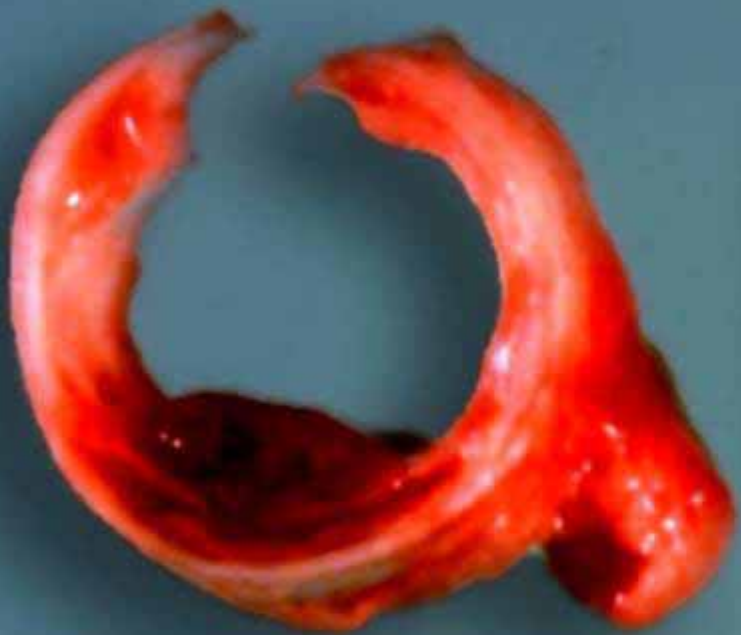
- **Rapid course**
 - incubation: 12-24 hours, almost 100% of animals
 - shed in nasal secretions for 4-5 days
 - recovery, if uncomplicated, in 7 days
- **Symptoms**
 - coughing
 - apathetic, prostrate, erythema of skin, anorexia
 - dyspnea, sneezing, pyrexia, “drop-off”
 - reddened eyes and conjunctival discharge
 - abortions

SIV Lesions

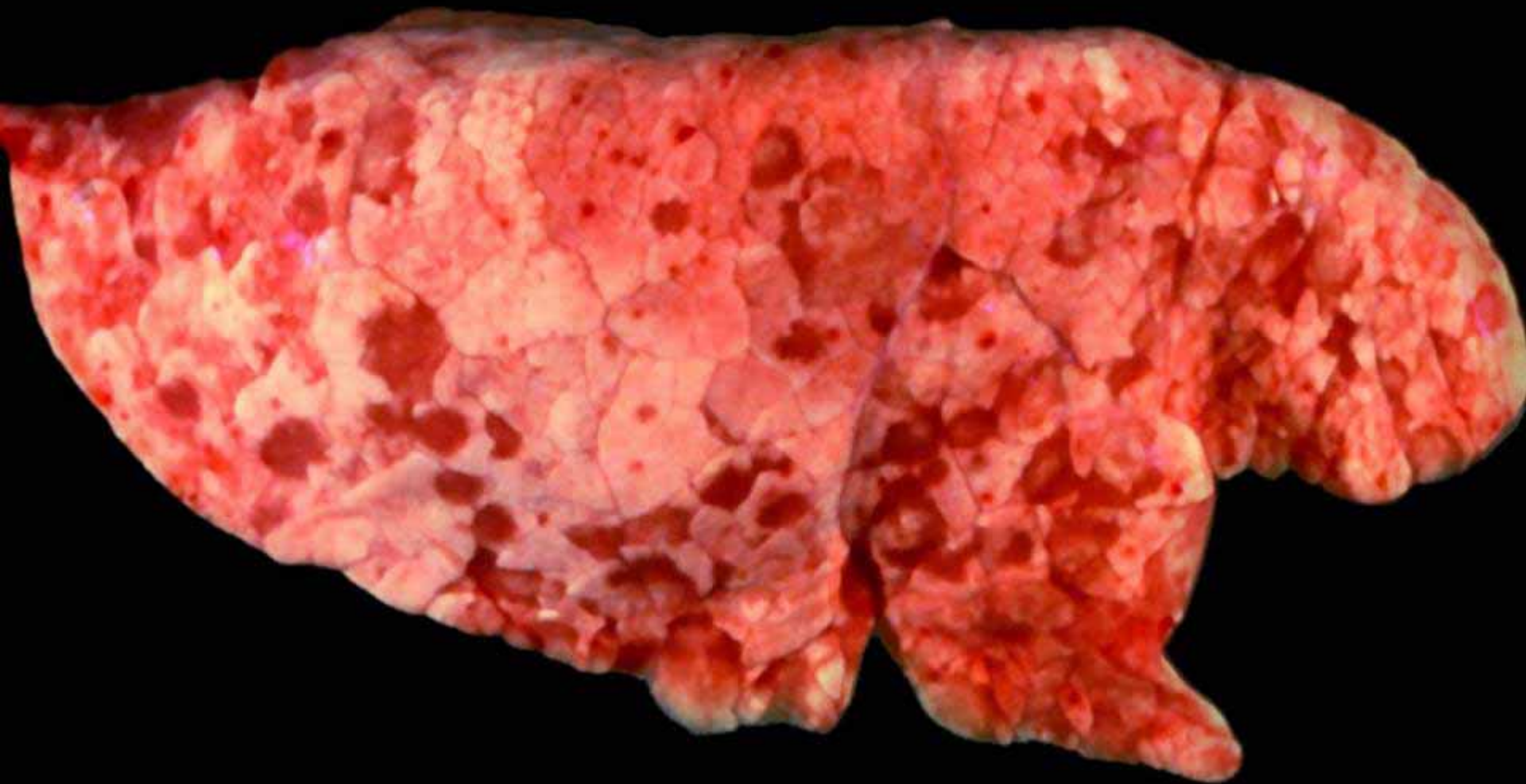- **Gross**
 - “checkerboard” cranioventral pattern
 - diffuse interstitial pattern
 - firm (proliferative) cranioventral pattern
- **Microscopic**
 - necrotizing bronchiolitis
 - proliferation of type II pneumocytes
 - peribronchial and perivascular cuffing

Diagnosis of SIV

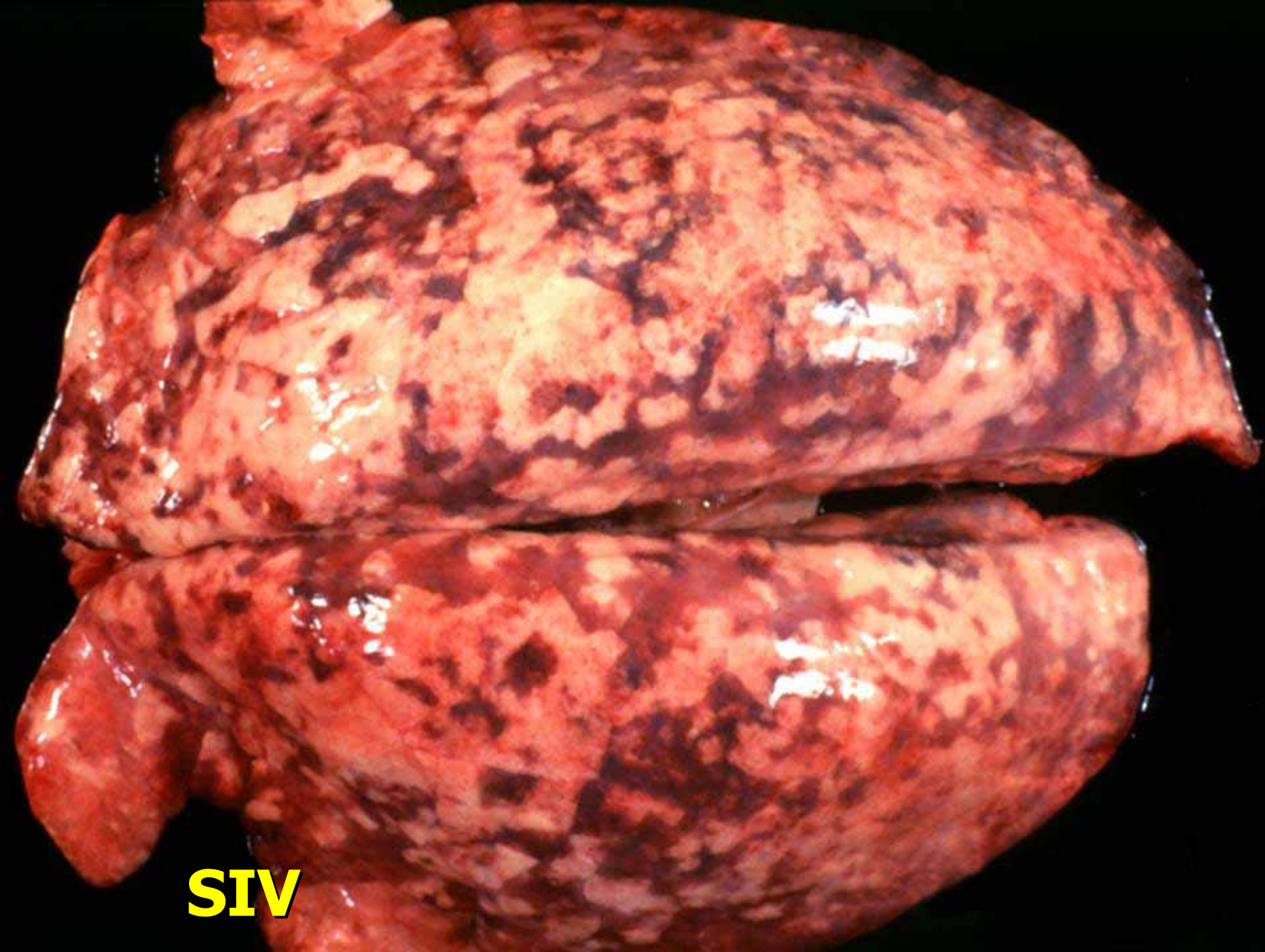- Typical lesions
- Demonstration of SIV or antigens
 - FA/IFA lung
 - VI lung, nasal swabs
 - IHC fixed lung
 - ELISA nasal swabs, bronchial swabs
- Serology: paired samples
 - HI



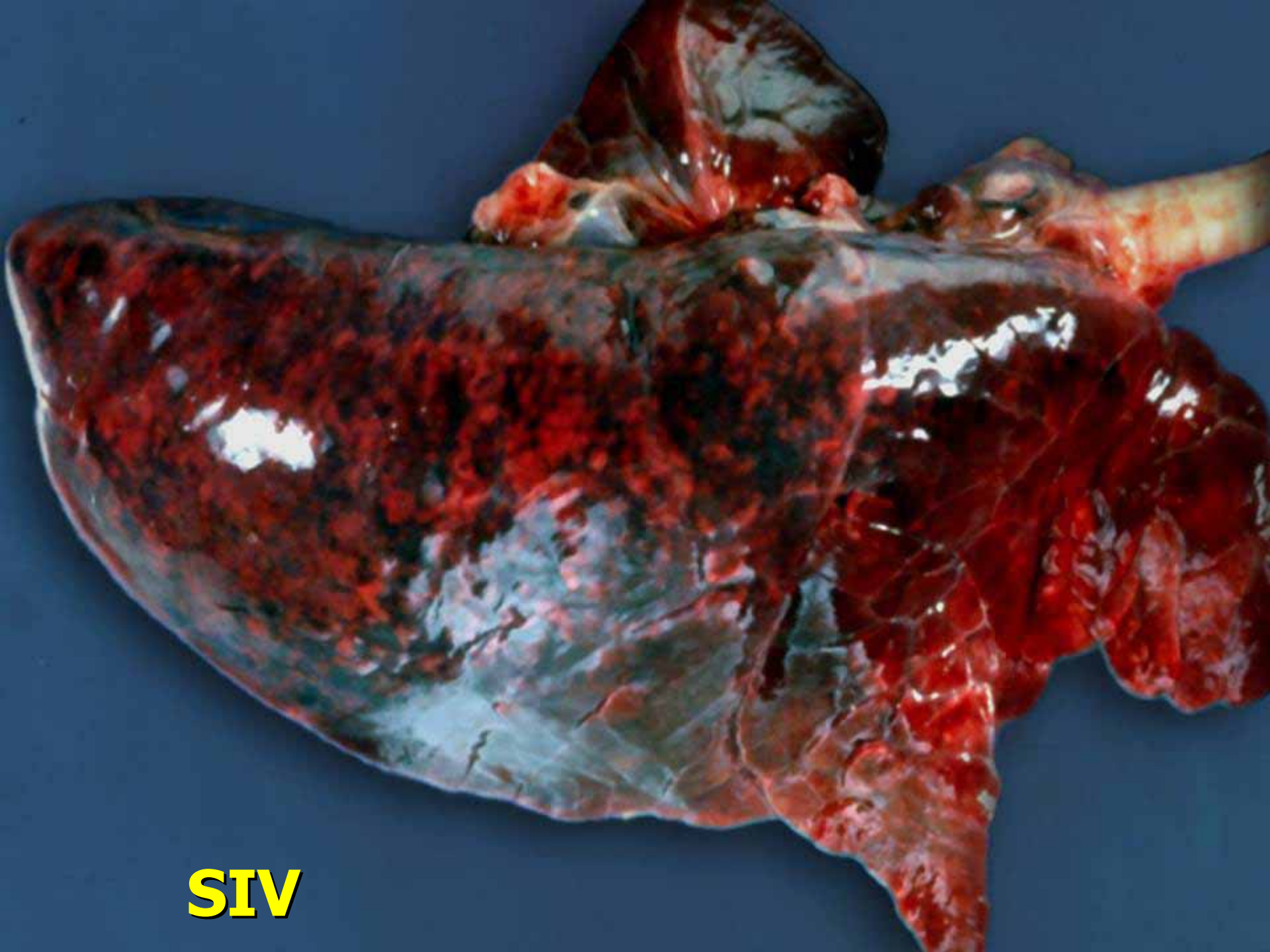SIV



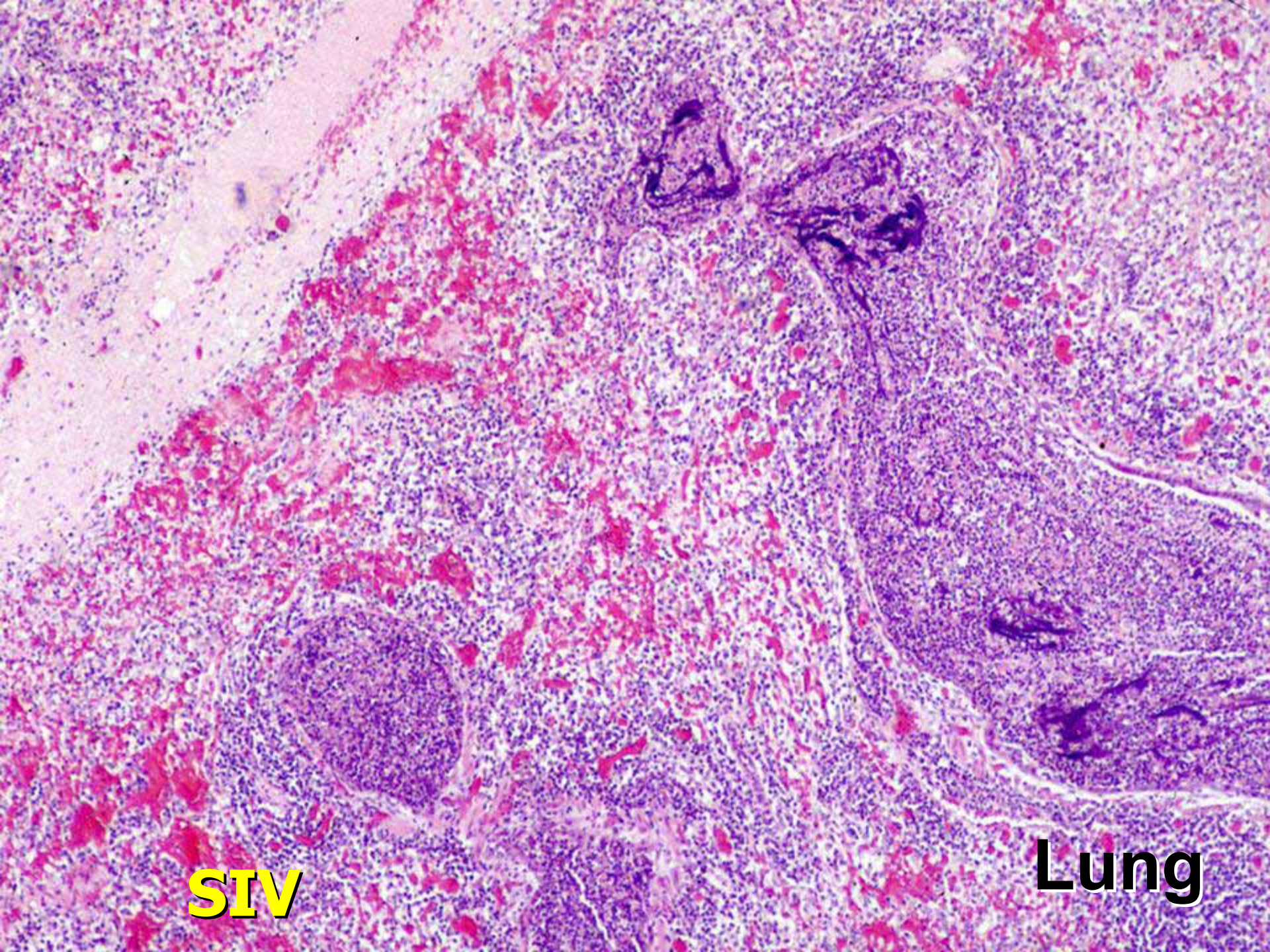
SIV



SIV

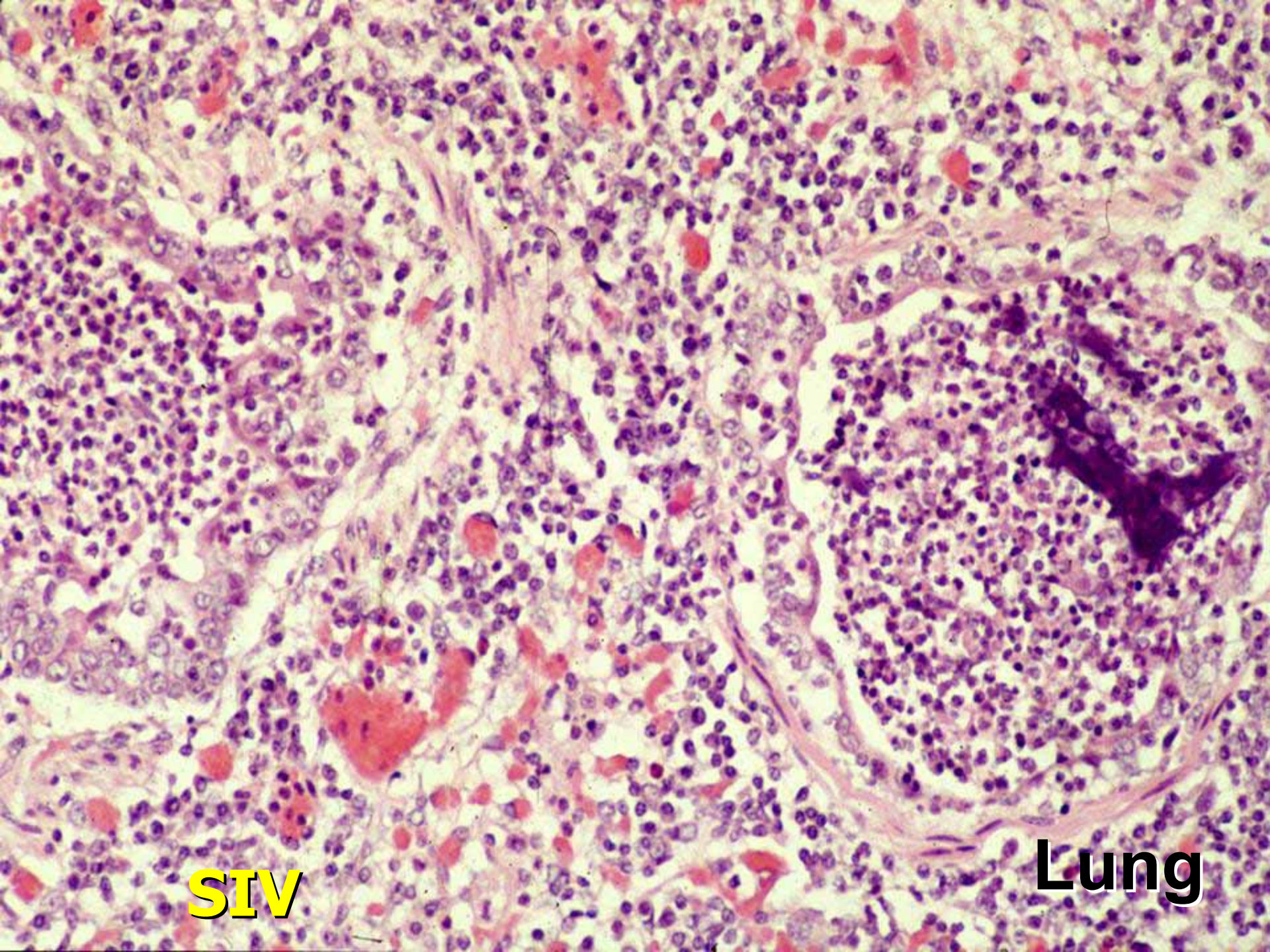


SIV



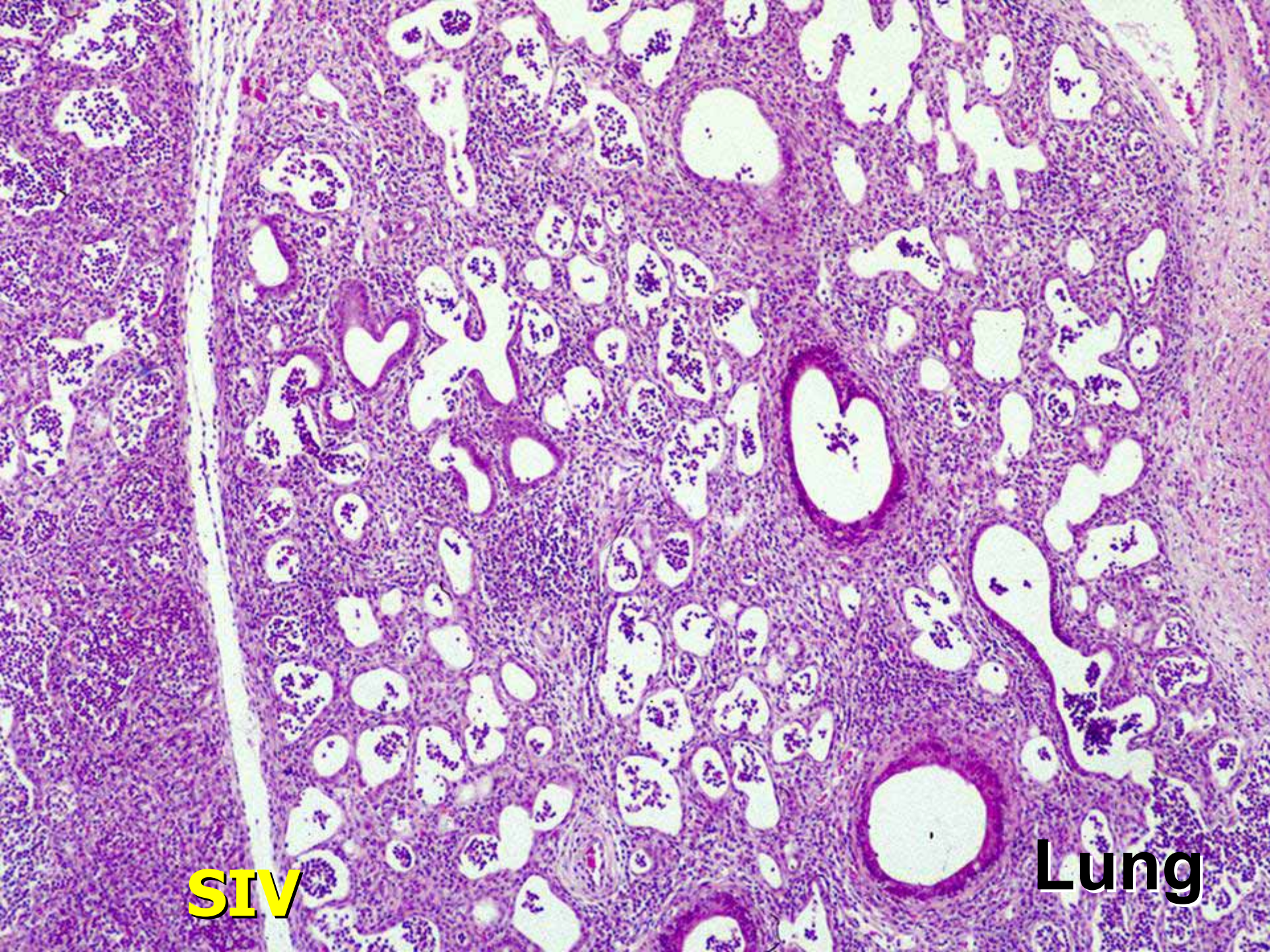
SIV

Lung



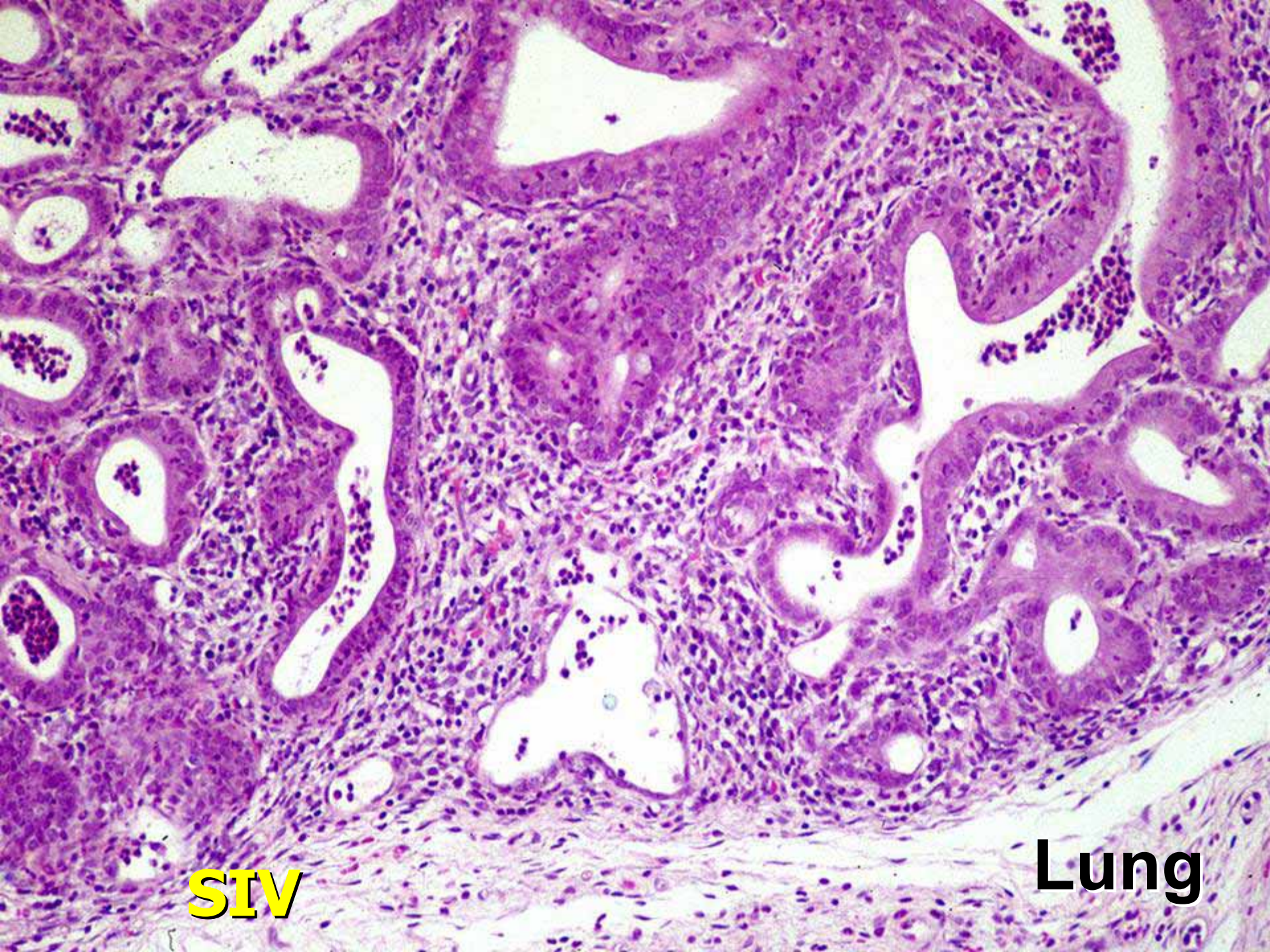
SIV

Lung



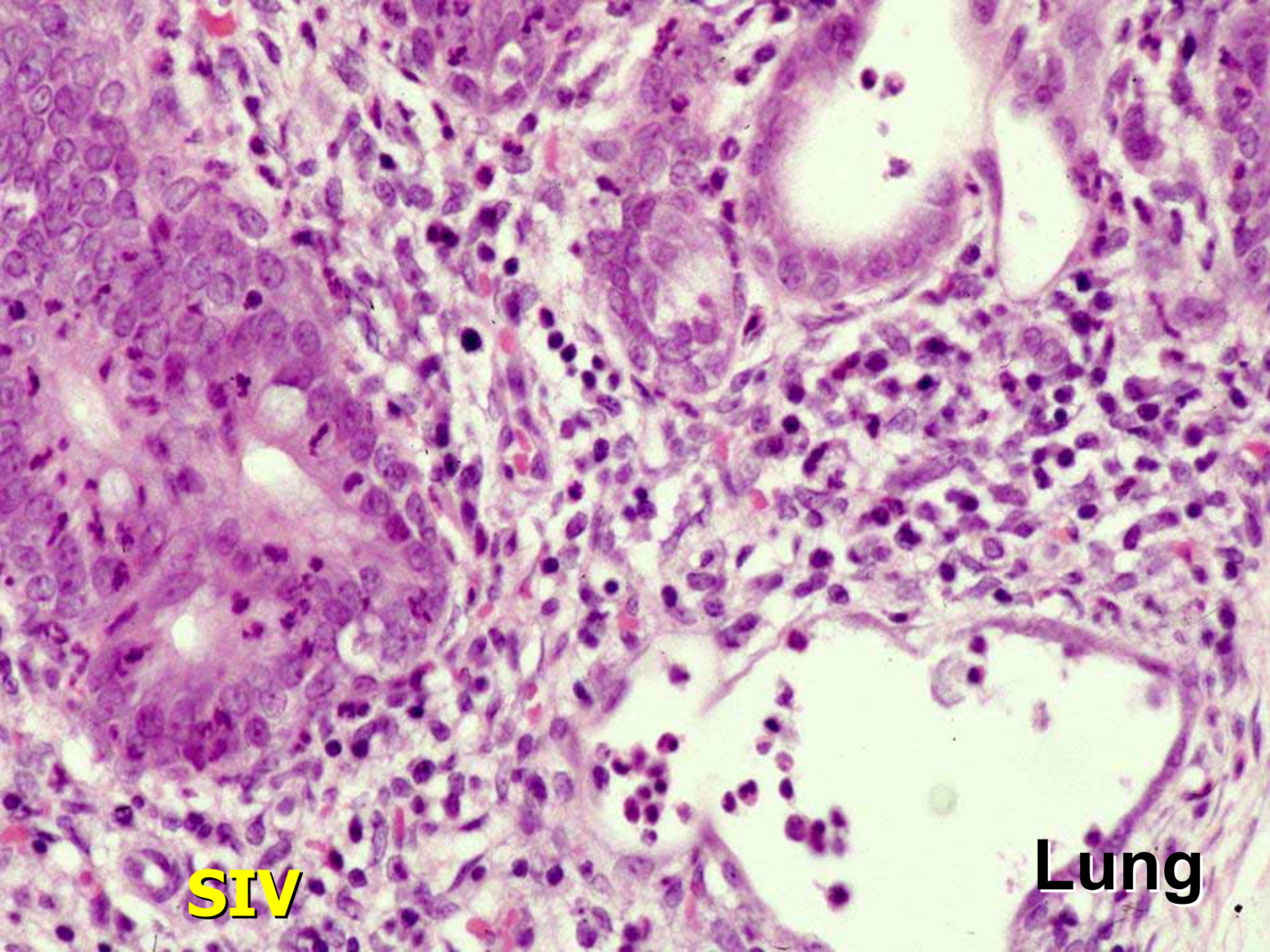
SIV

Lung



SIV

Lung

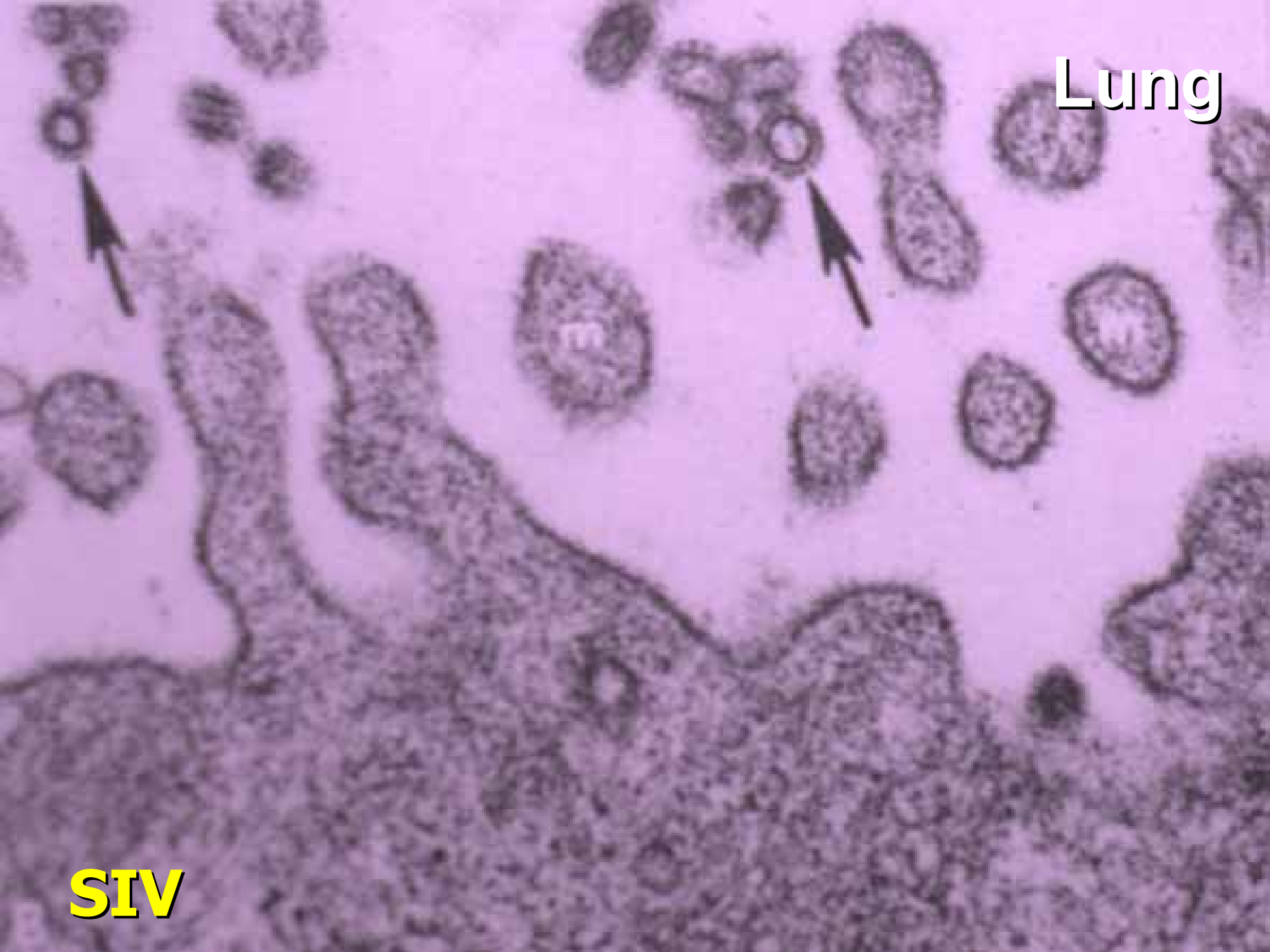

SIV

Lung

Lung

SIV



As the two friends wandered through the snow on their way home, Piglet grinned to himself, thinking how lucky he was to have a best friend like Pooh.



Pooh thought to himself:
“If the pig sneezes,
he’s fucken dead.”

Swine Influenza in Humans

- Pigs are important role in inter-species transmission, because they have receptors to both avian and human influenza virus strains: “mixing vessel”
- Outbreaks and sporadic human infection with swine influenza have been occasionally reported
- Influenza outbreak caused by swine H1N1 virus in Fort Dix, New Jersey in 1974
- Outbreak in Wisconsin in 1988 resulted in multiple human to human infections
- People in contact with swine have higher antibody levels
- Swine influenza viruses have been isolated from turkeys, indicating transmission between pigs and avian species
- Pigs can be infected with the highly pathogenic avian influenza (HPAI) H5N1 virus





Porcine Respiratory Coronavirus

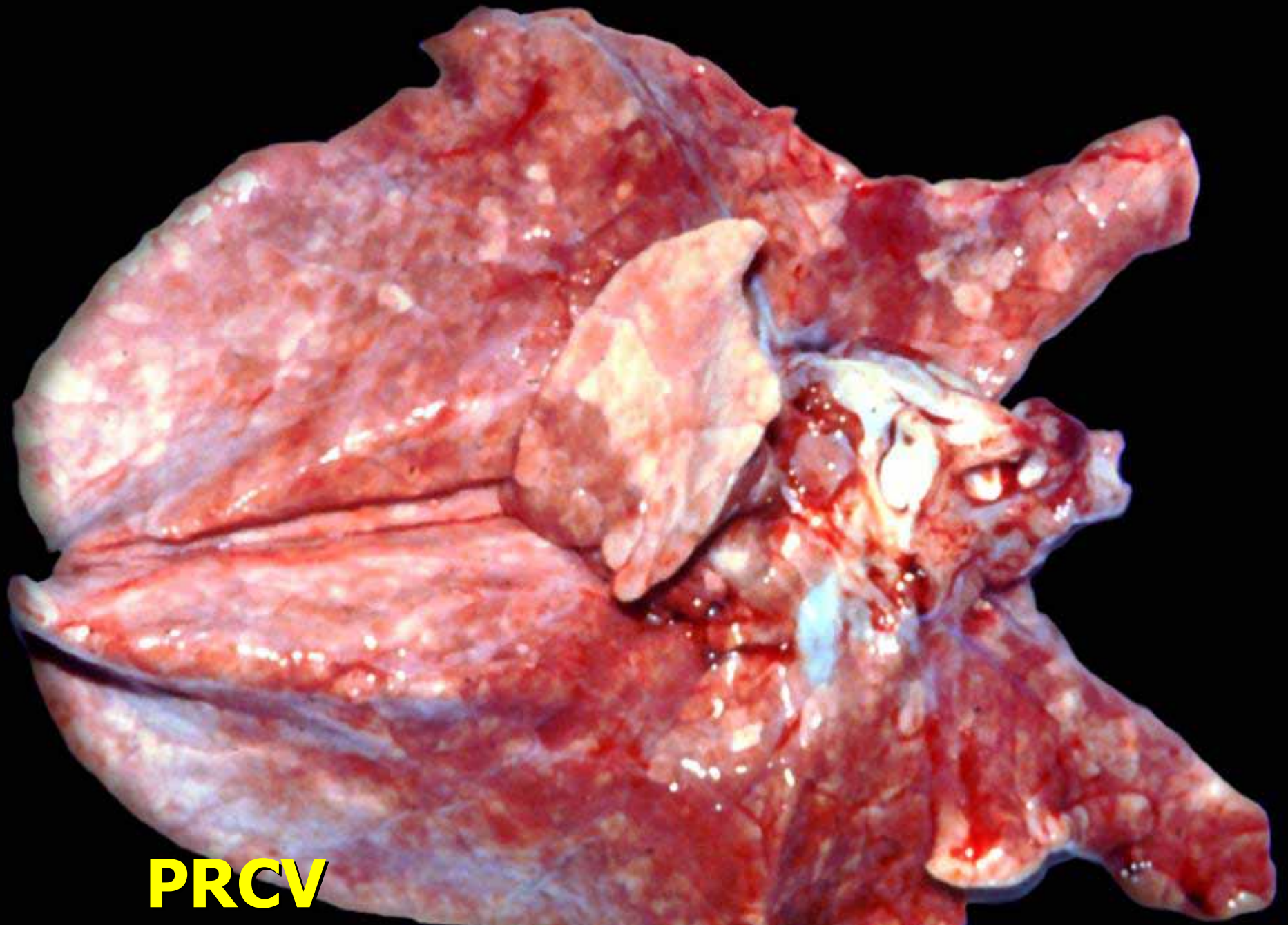- **Deletion mutant of TGE virus**
- **Replicates in epithelium of nasal cavity and airways**
- **Shed in nasal secretions for up to 10 days**
- **Virus is transient in lungs**

Symptoms and Lesions of PRCV

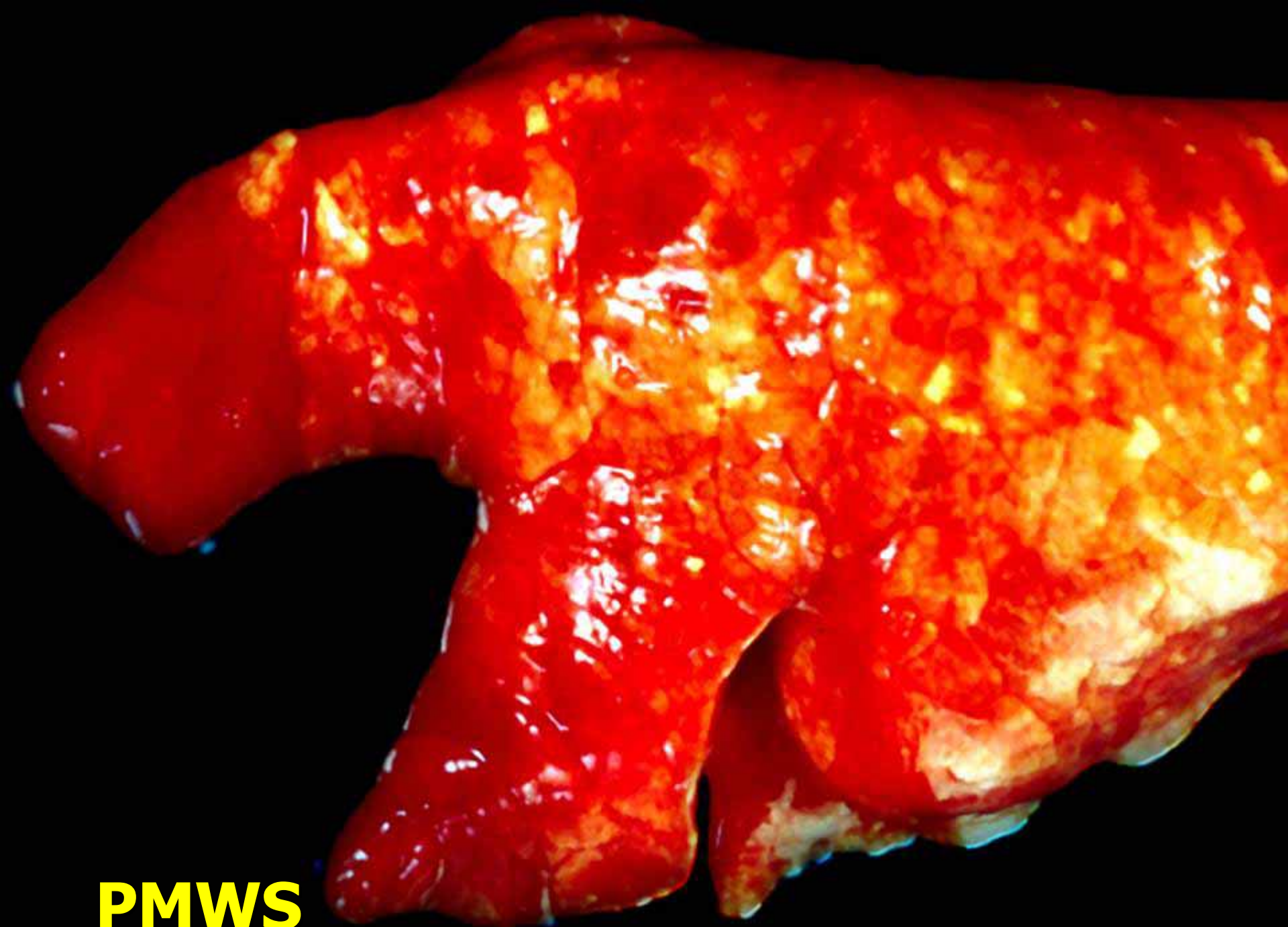- Symptoms
 - usually none ****seroconversion to TGE****
 - mild dyspnea, pyrexia, coughing
- Lesions
 - slight increased firmness of apical, cardiac lobes
 - mild interstitial pneumonia with necrosis of epithelium of terminal airways

Diagnosis of PRCV

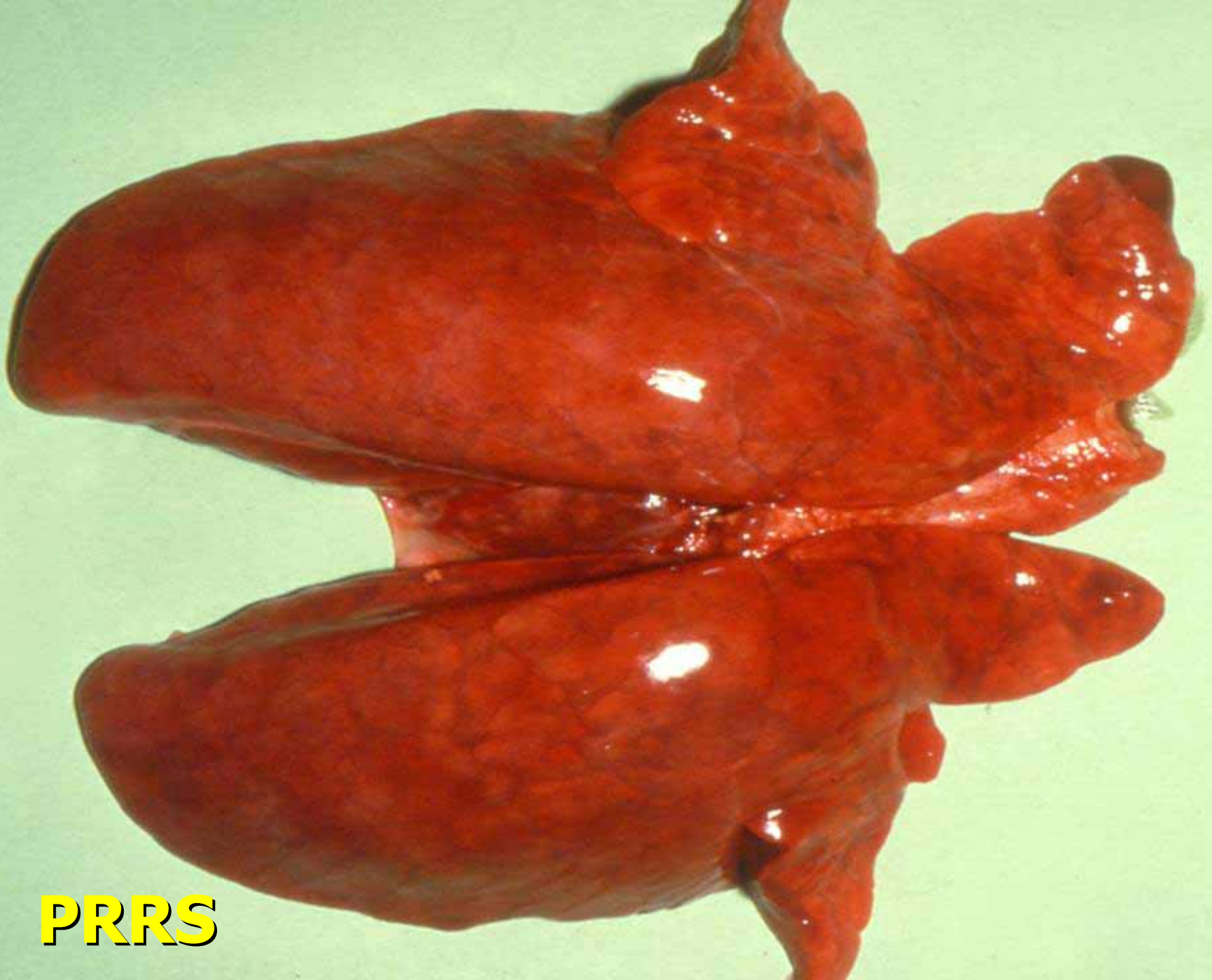
- Typical lesions
- Demonstration of PRCV or antigen
 - FA lung
 - VI nasal swabs, lung
 - Differentiate from TGE: cDNA probe
 - PCR followed by cDNA probe
- Serology
 - SN for TGE and on sera $>$ or $=$ 1:64
 - Competitive ELISA



PRCV



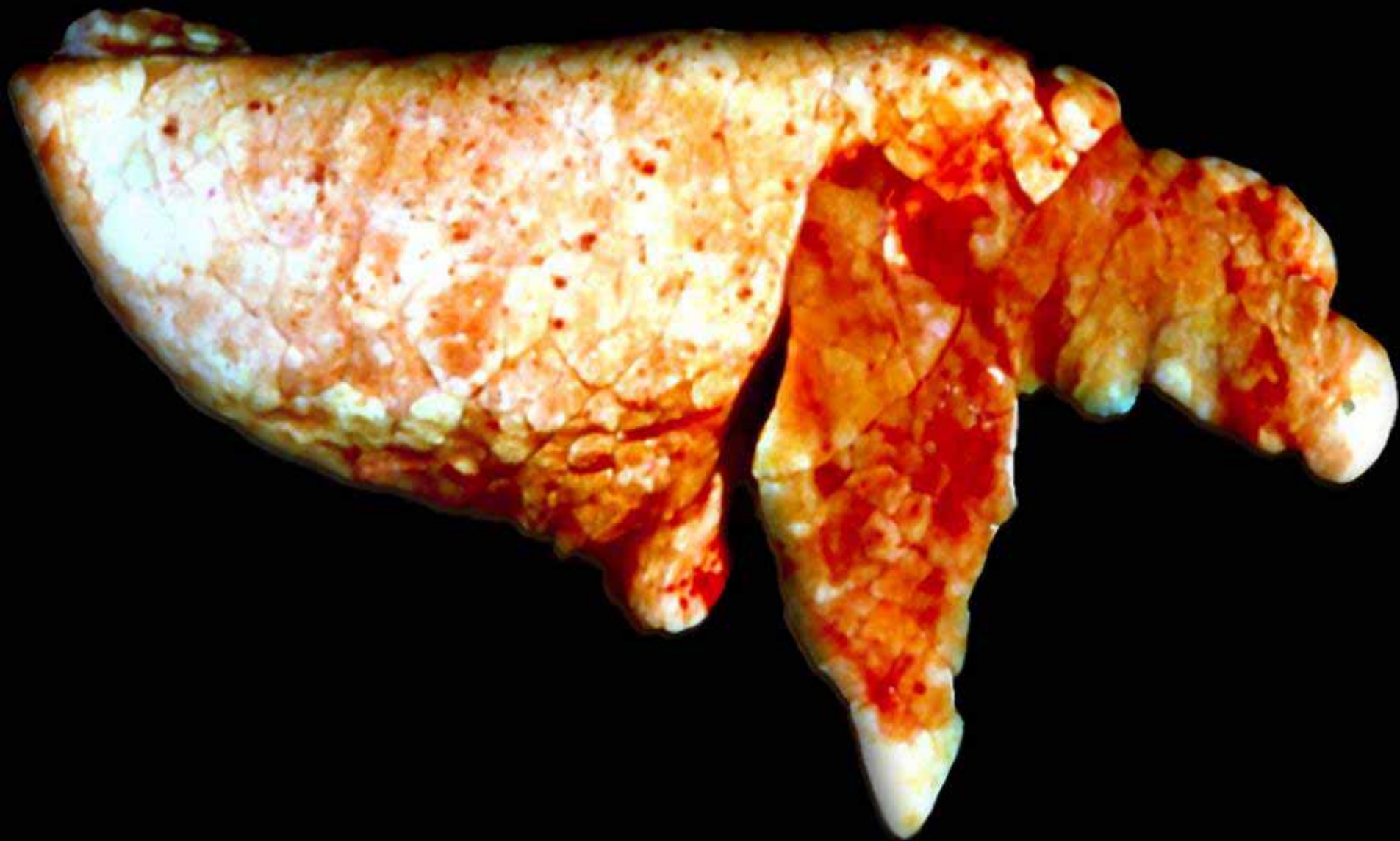PMWS



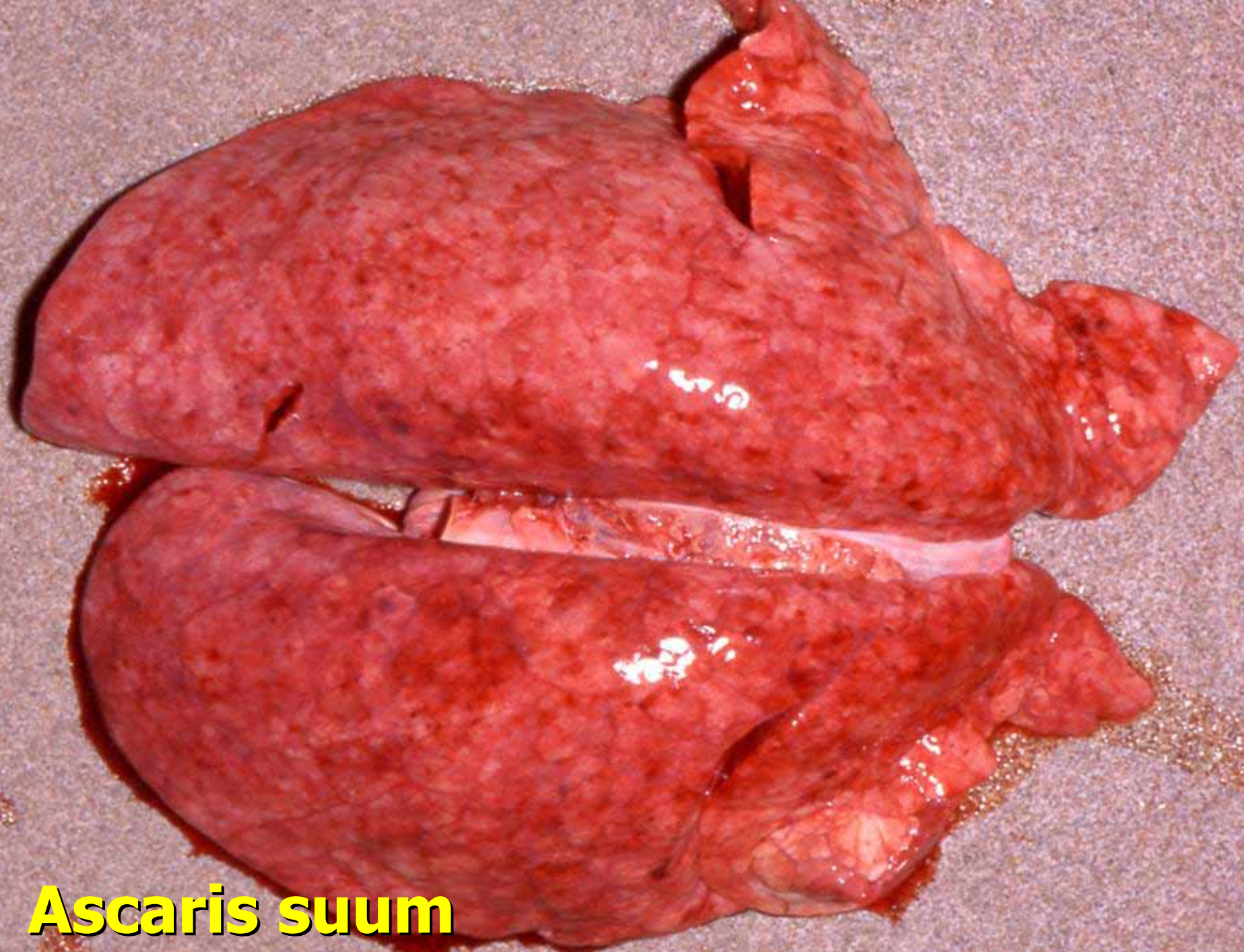
PRRS



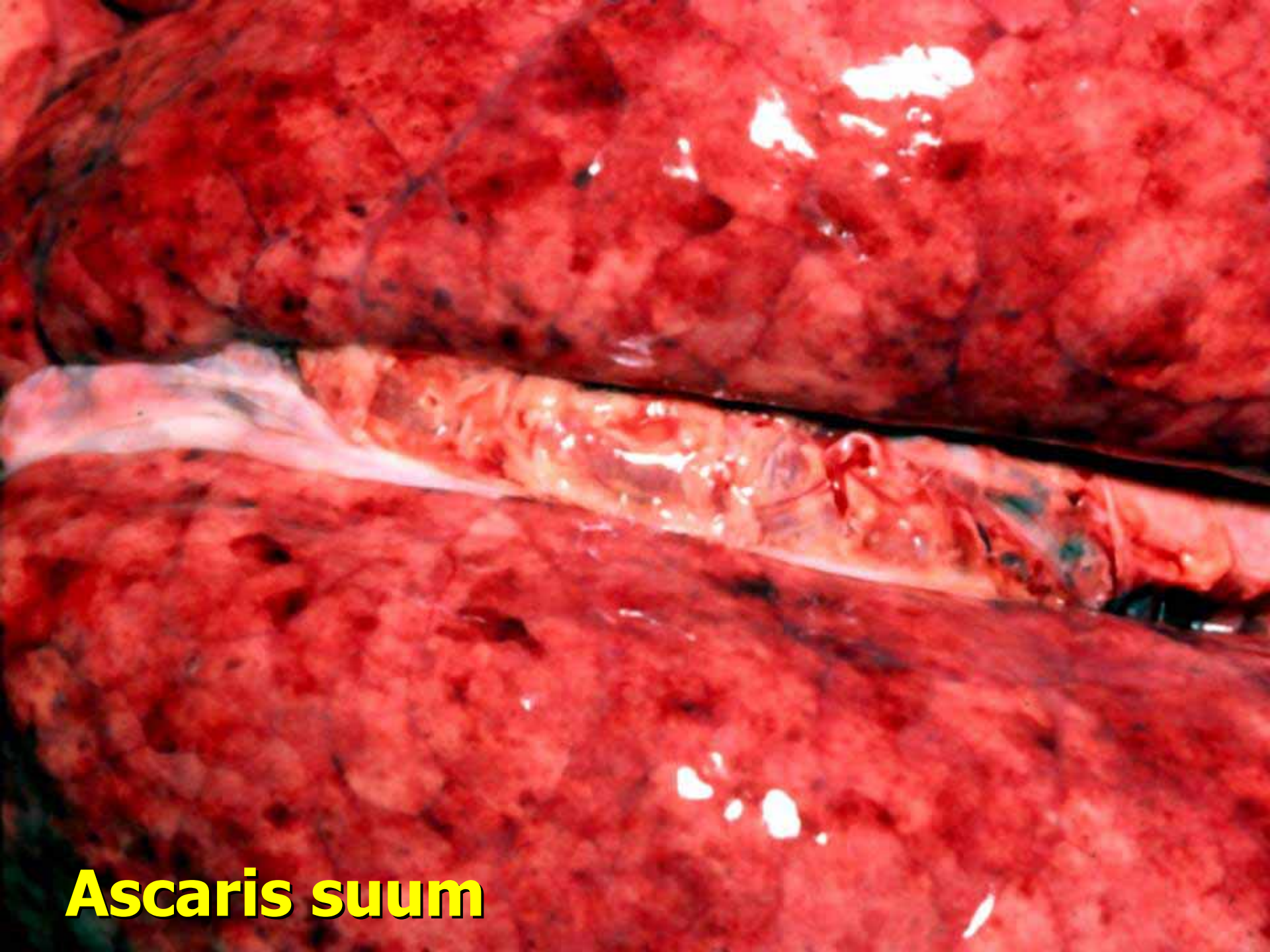
Pseudorabies



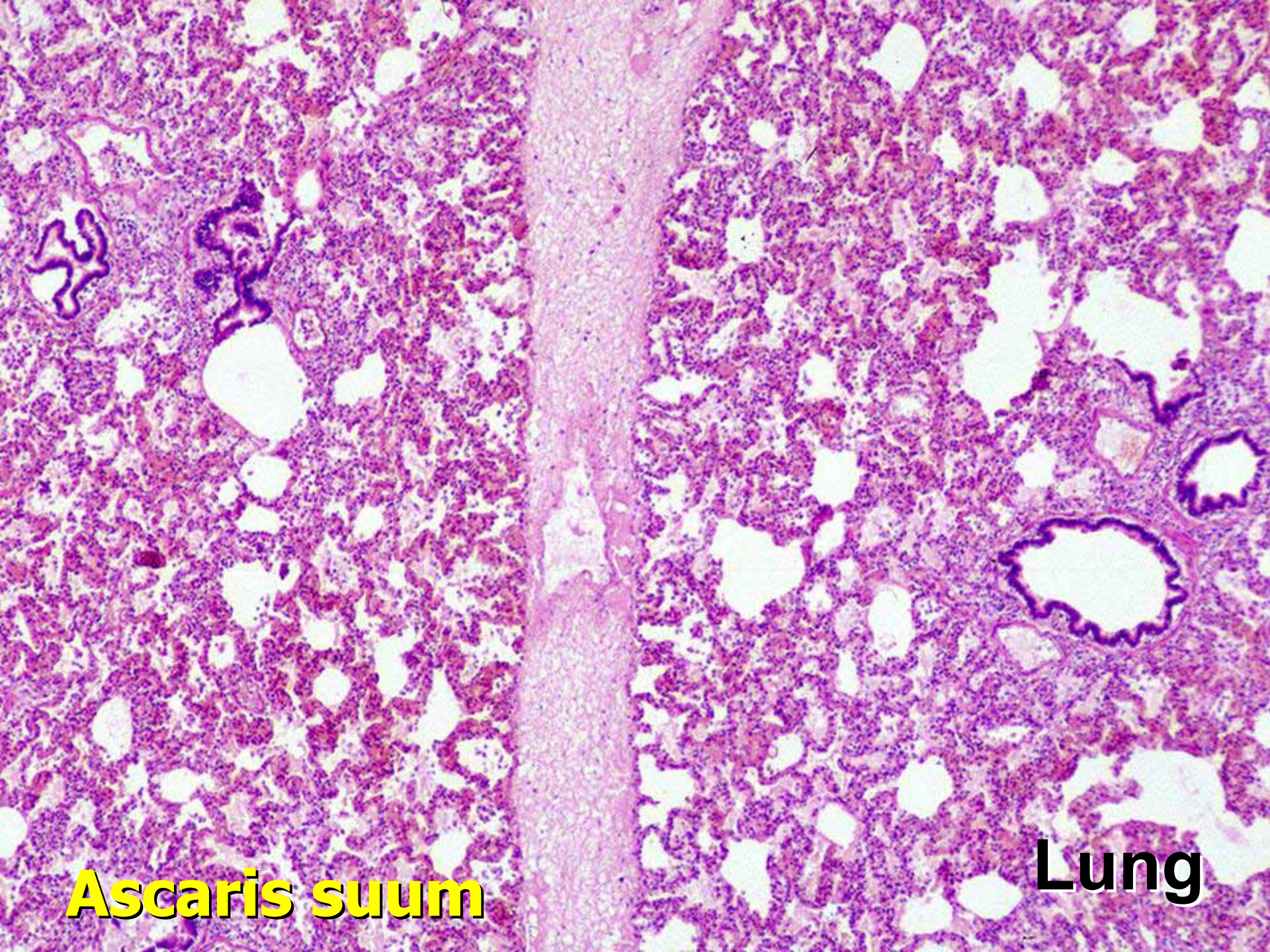
SIV + PRRSV



Ascaris suum

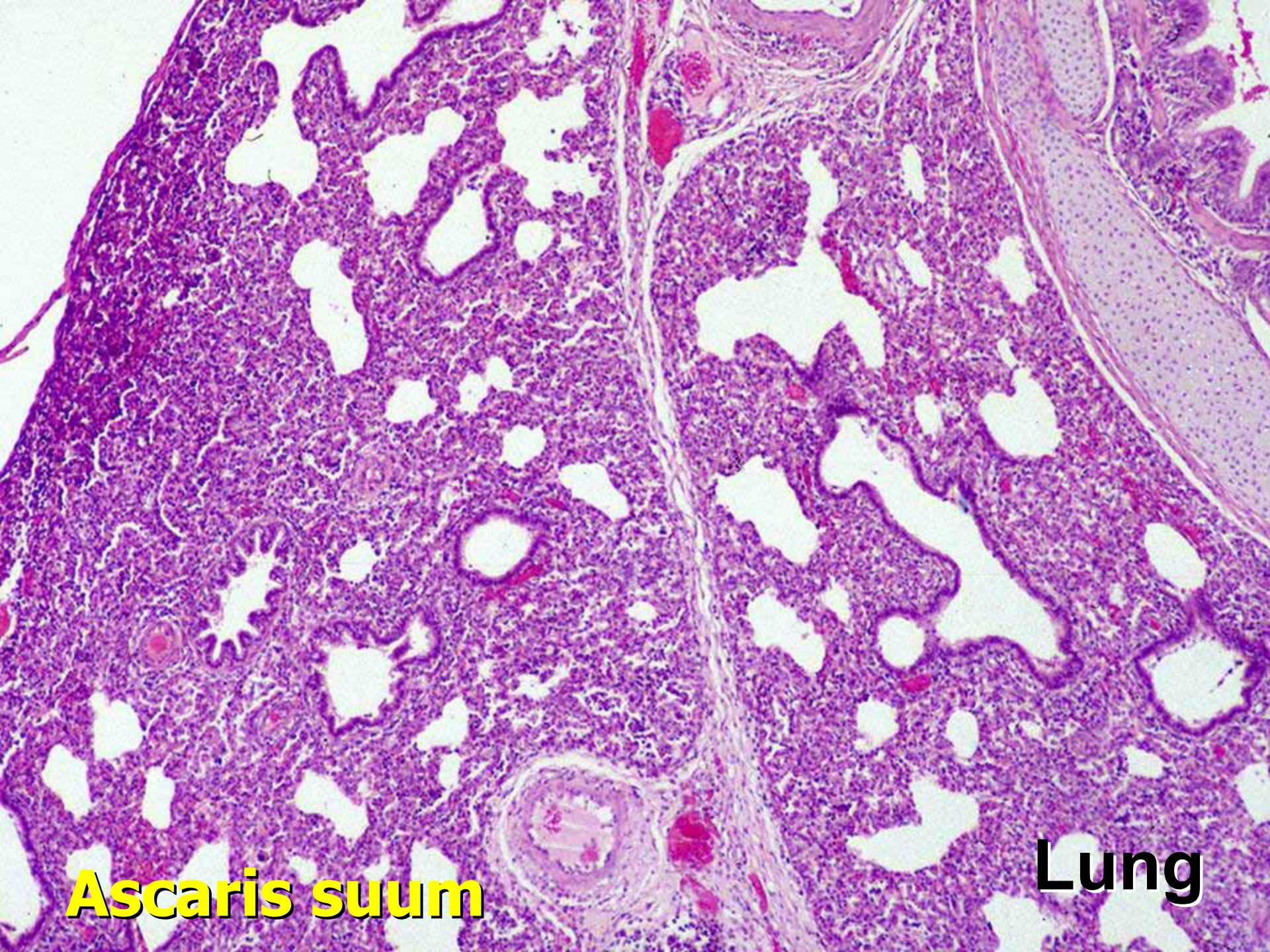


Ascaris suum



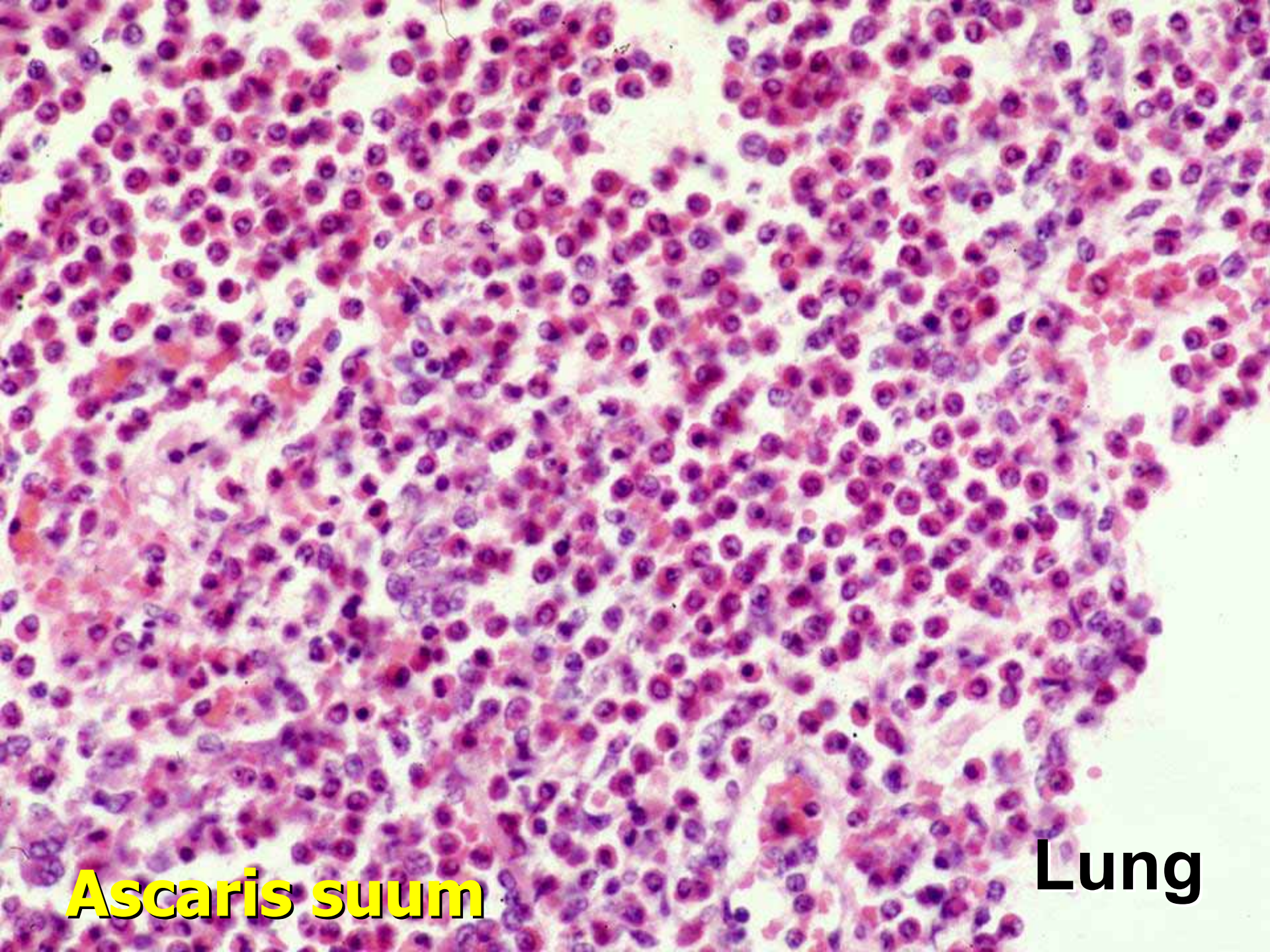
Ascaris suum

Lung



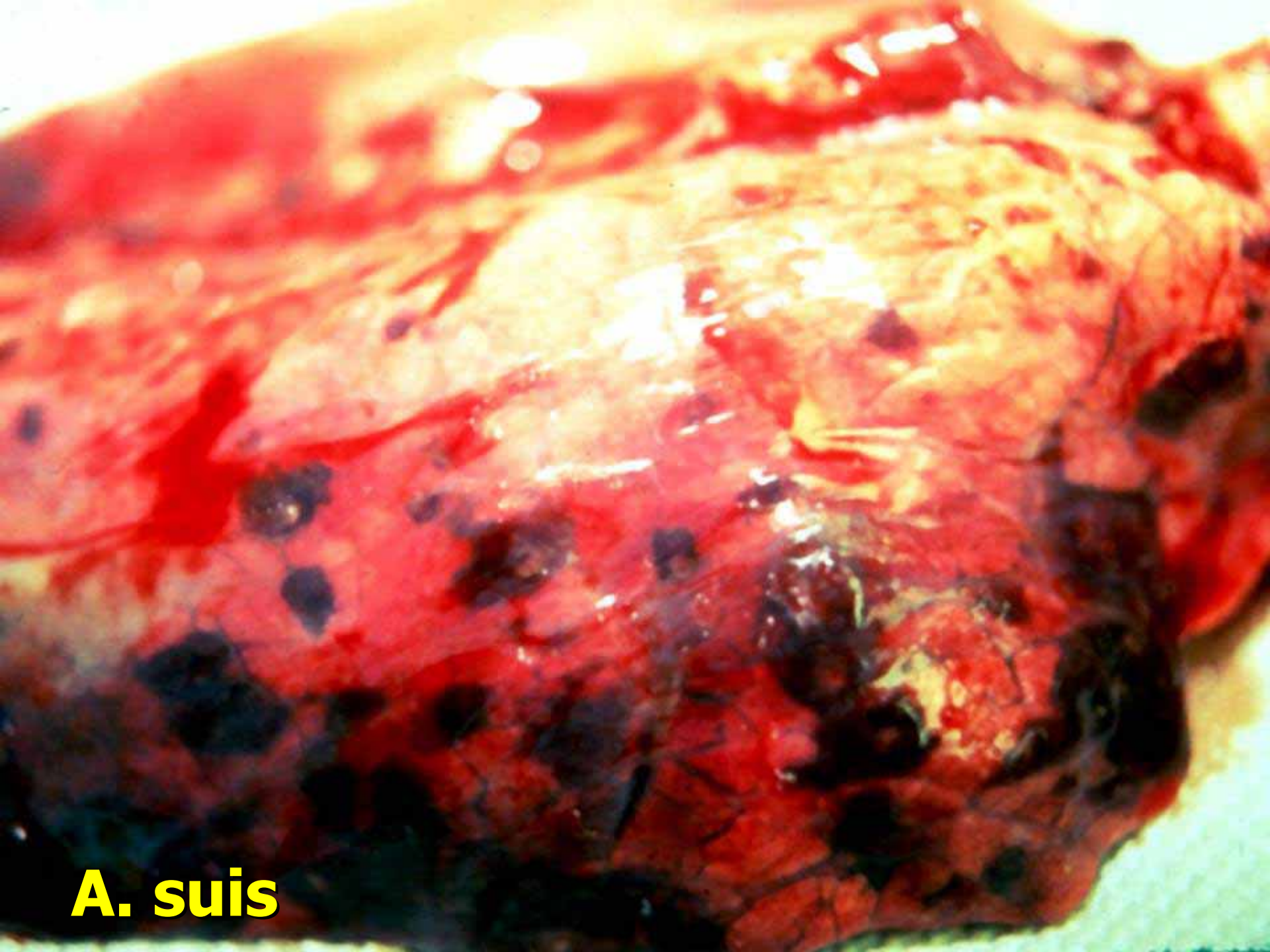Ascaris suum

Lung

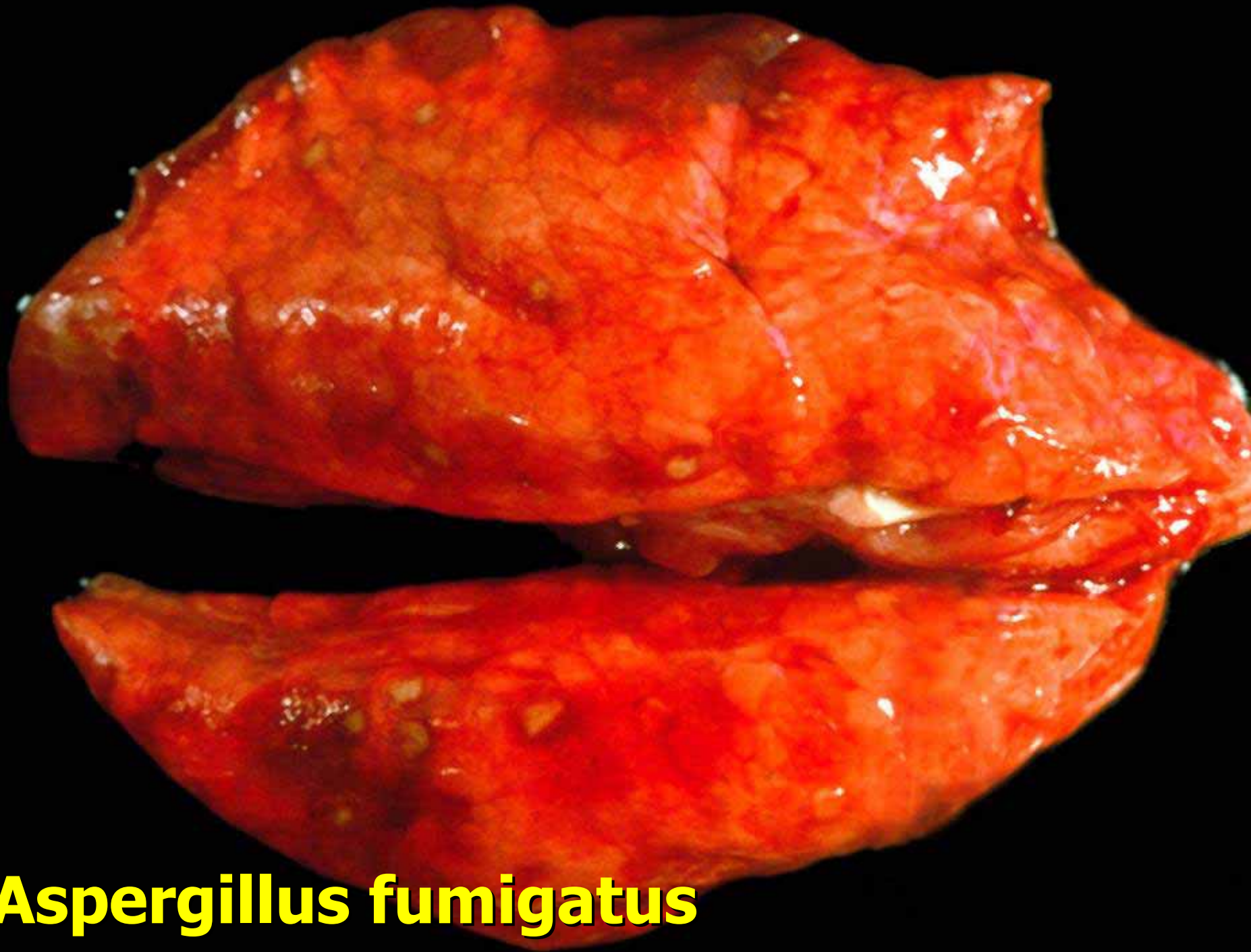


Ascaris suum

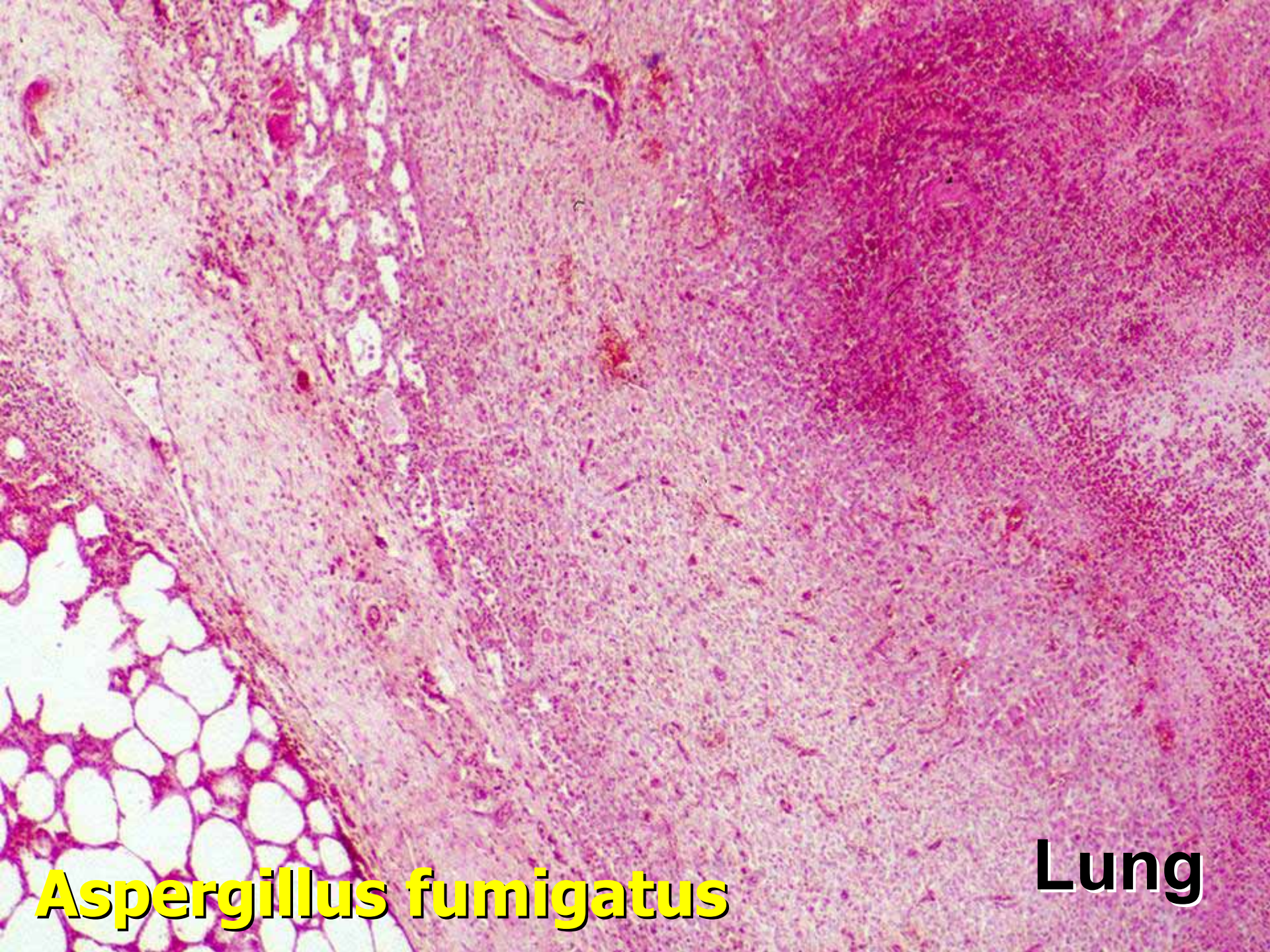Lung



A. suis

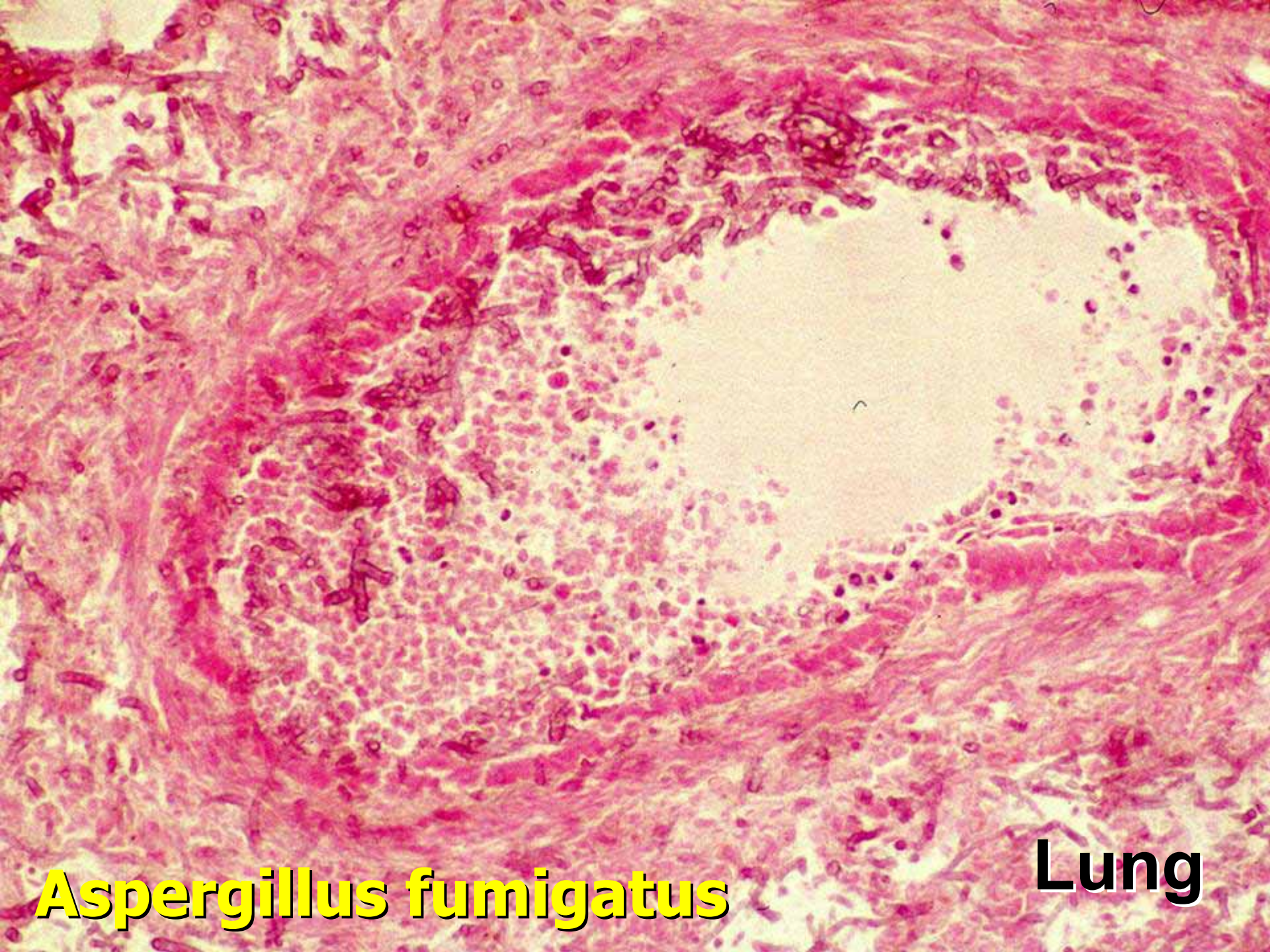


Aspergillus fumigatus



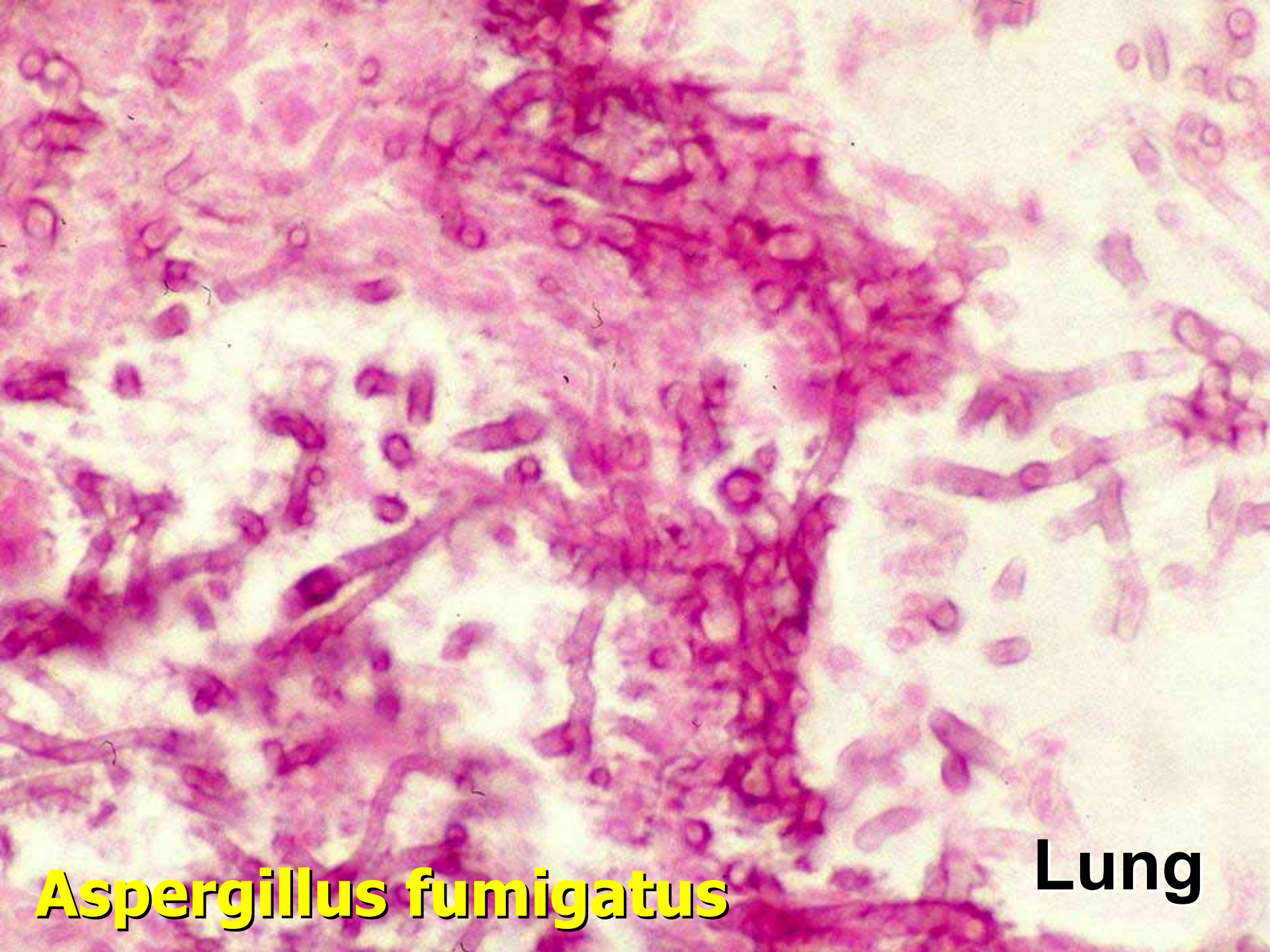
Aspergillus fumigatus

Lung



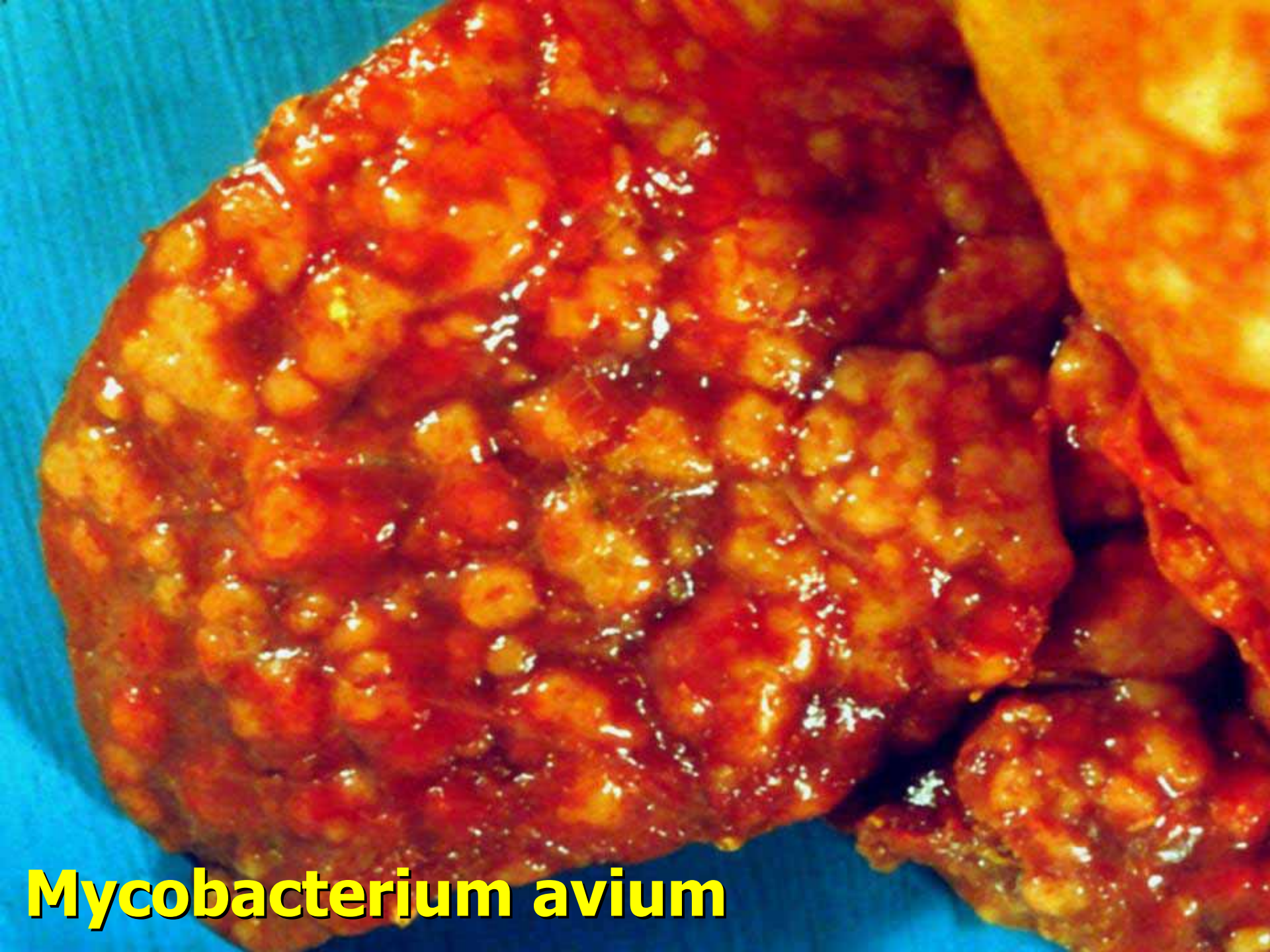Aspergillus fumigatus

Lung



Aspergillus fumigatus

Lung



Mycobacterium avium



Mycobacterium avium




Bacterial Pneumonia in Swine

Infection versus Disease

- subclinical upper respiratory bacterial infection \neq pneumonia
- risk factors for bacterial pneumonia
 - impaired lung defenses
 - level of challenge
 - virulence of bacterial organism

Bacterial Initiators of Porcine Respiratory Disease Complex

Nursery Grower



“17-18 Week Wall”
increased morbidity
increased mortality

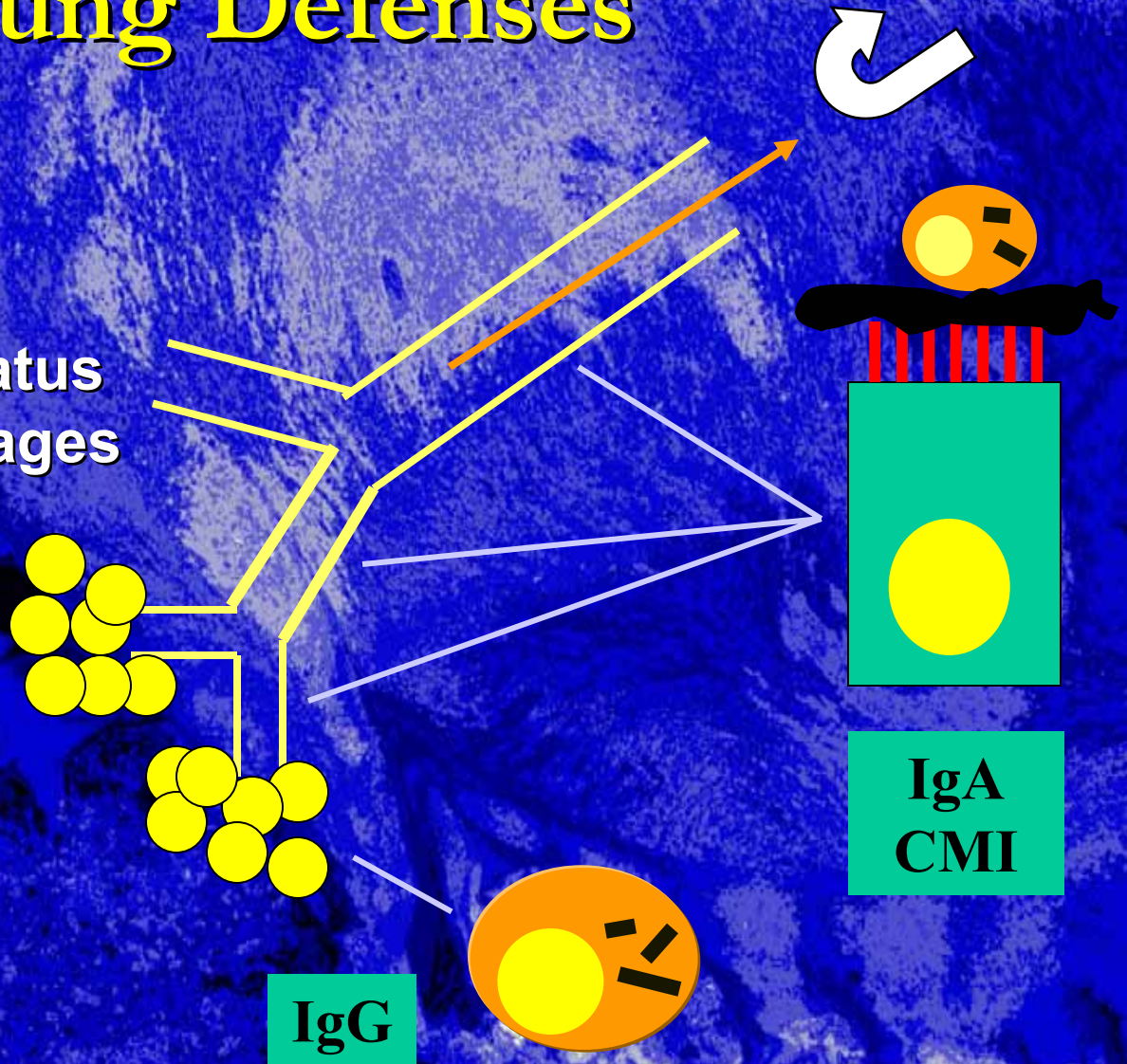
Lung Defenses

Native

Mucociliary Apparatus
Alveolar macrophages
Inflammation

Acquired

IgA
CMI
IgG



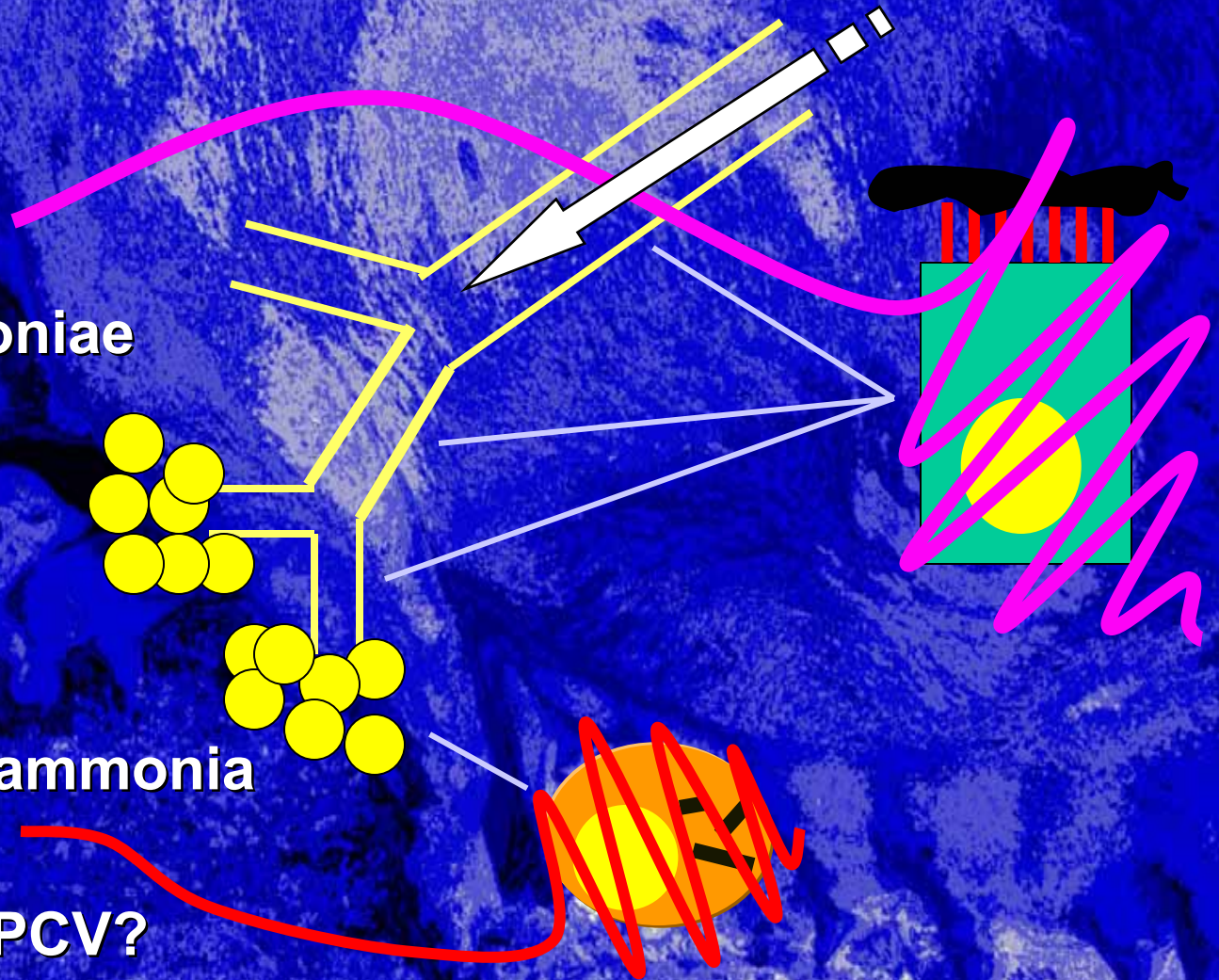
Damage to Lung Defenses

Mucociliary Apparatus

M. hyopneumoniae
SIV
PRV
PRCV
PCV?
Chilling
high levels of ammonia

Macrophages

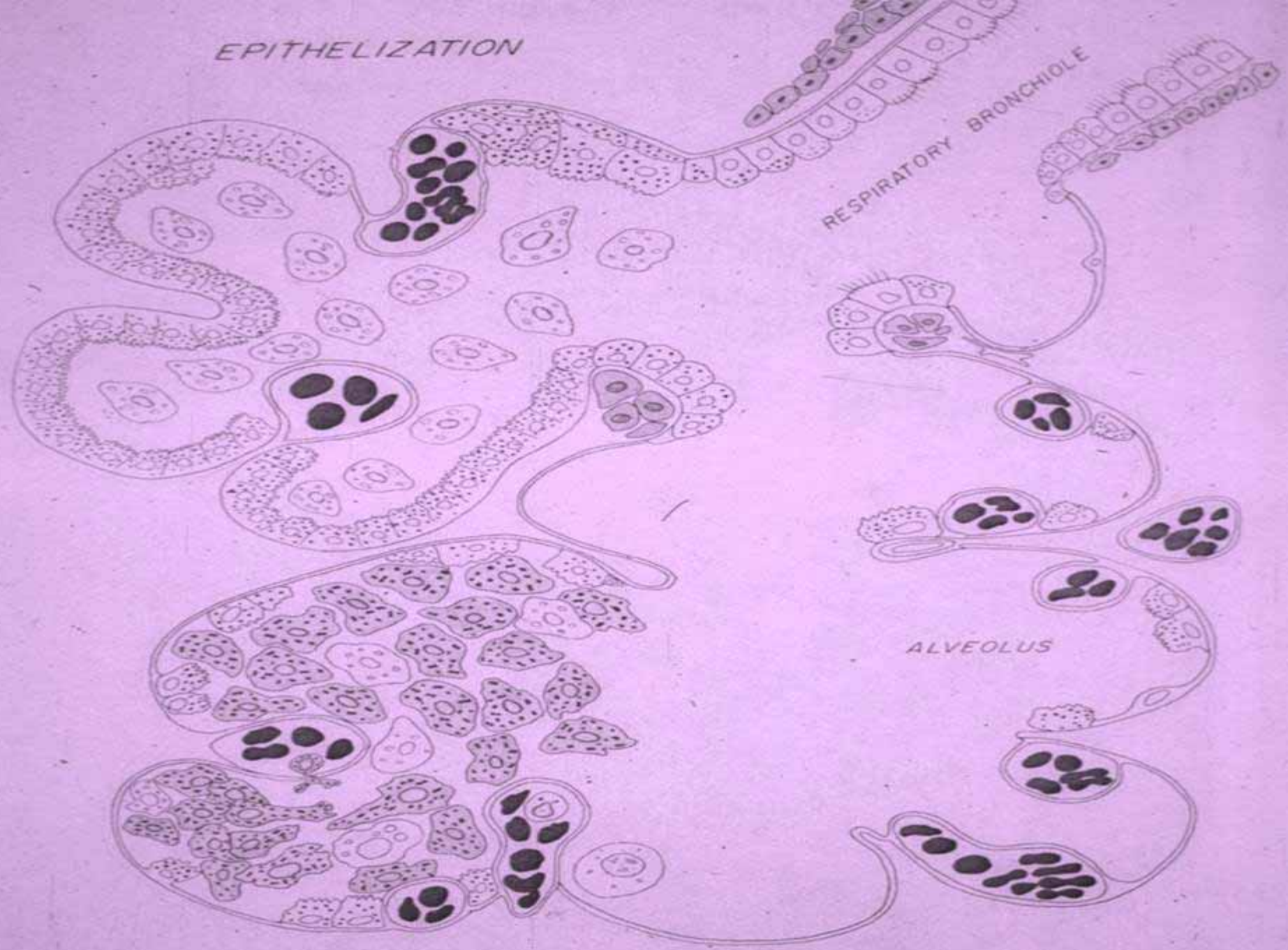
PRRSV, APP, PCV?
Stress, endogenous steroids



PRDC is a “Complex”

- **Primary pathogens (Initiators)**
 - *M. hyopneumoniae*
 - *A. pleuropneumoniae*
 - SIV
 - PRRSV
 - PRV
 - PRCV
 - PCV
- **Secondary pathogens (Followers)**
 - *P. multocida*
 - *S. suis*
 - *H. parasuis*
 - *B. bronchiseptica*
 - *A. pyogenes*
 - *****A. pleuropneumoniae***

EPIITHELIALIZATION



RESPIRATORY BRONCHIOLE

ALVEOLUS

PNEUMONIA

NORMAL

Risk Factors for PRDC

Primary Pathogens

Exposure Dose

Immunity

Prevention and Control of PRDC

- **focus on Initiators**
- **farm or system specific**
 - **identify initiators**
 - **evaluate shedding and immunity**
 - **evaluate management practices, exposure**
 - **develop plan**
 - **work plan**
 - **monitor and re-evaluate**

Increased Bacterial Challenge

- High stocking density
- Frequent mixing of pigs
- Large variation in age in pens or rooms
- ☹️ 200 pigs per air space
- Low ventilation rates
- Non-solid partitions between pens
- Breaches in biosecurity

Virulence of Organisms

- **Primary Inhaled**
 - *M. hyopneumoniae*
 - *A. pleuropneumoniae*
 - *B. bronchiseptica*
- **Primary Blood-borne**
 - *S. choleraesuis*
 - *A. suis*
 - *A. pyogenes*
- **Secondary Inhaled**
 - *P. multocida*
 - *S. suis*
 - *H. parasuis*
 - *M. hyorhinis**
 - *A. pyogenes**

Mycoplasma hyopneumoniae

- fastidious pleomorphic bacterium
- infects only pigs
- colonizes respiratory epithelium - cilia
 - catarrhal bronchopneumonia - resolves \approx 75d
 - secondary purulent bacterial bronchopneumonia
 - “Enzootic pneumonia”
 - protracted disease
 - marked reduction in rate-of-gain

Mycoplasma hyopneumoniae

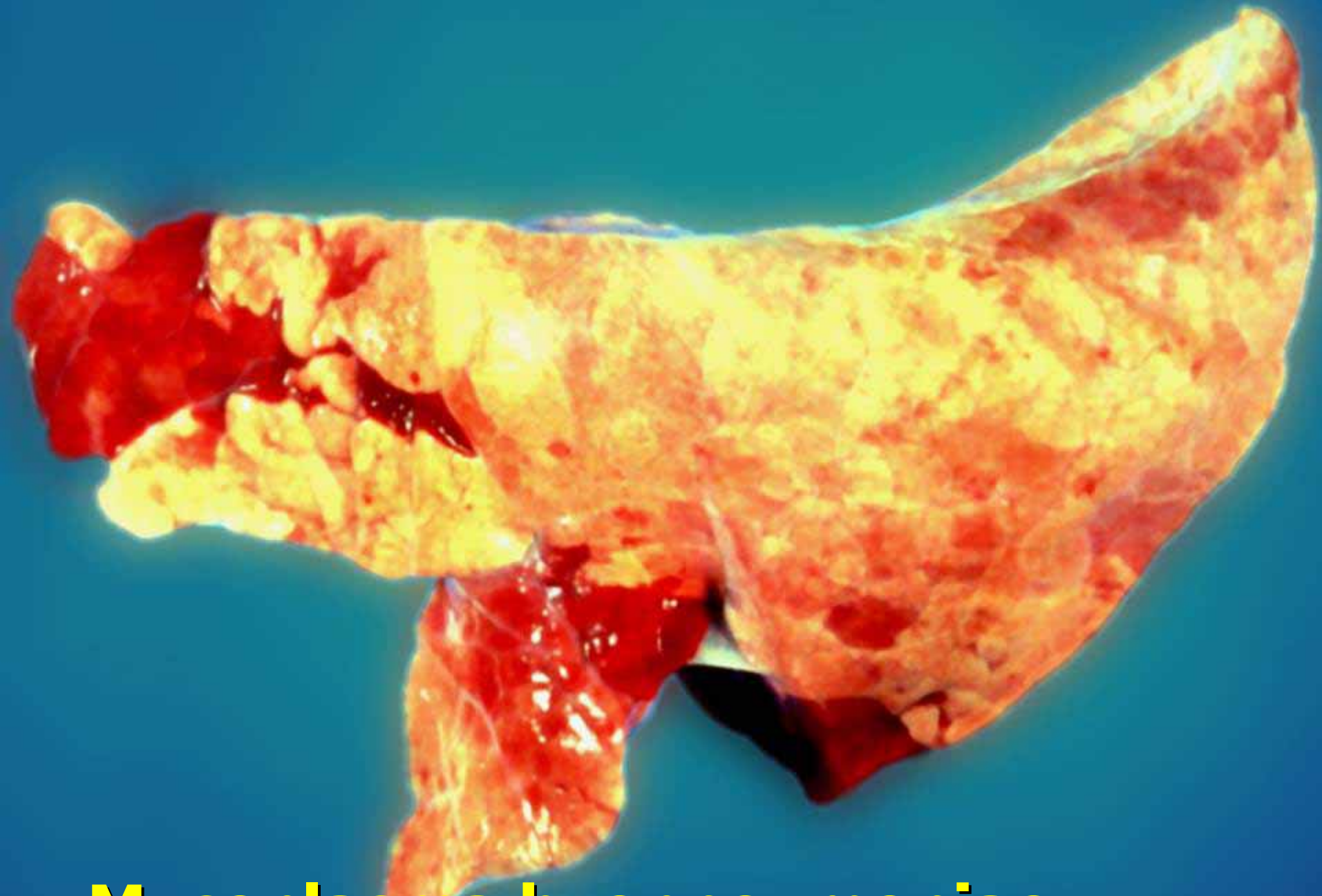Epidemiology

- **Transmission is inefficient**
 - **Nose-to-nose**
 - **Clinical disease** ☹️ **Subclinical disease**
 - **Older animals** ☹️ **Young animals**
 - **Aerosol**
- **Disease is dose-dependent**
 - **Subclinical infection vs. clinical disease**
 - **Incubation period: 11 days to 6 weeks**

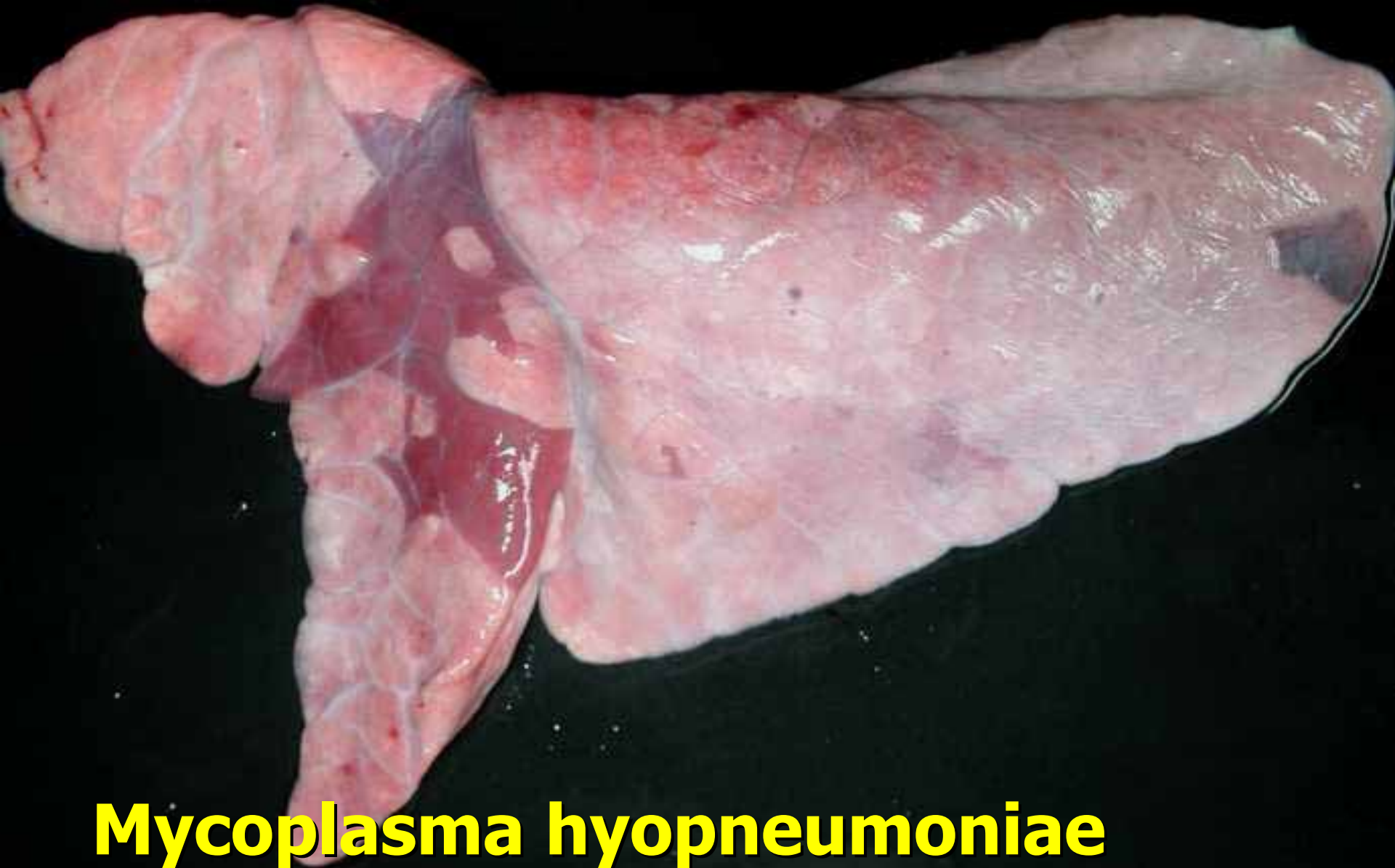Mycoplasma hyopneumoniae

Diagnosis

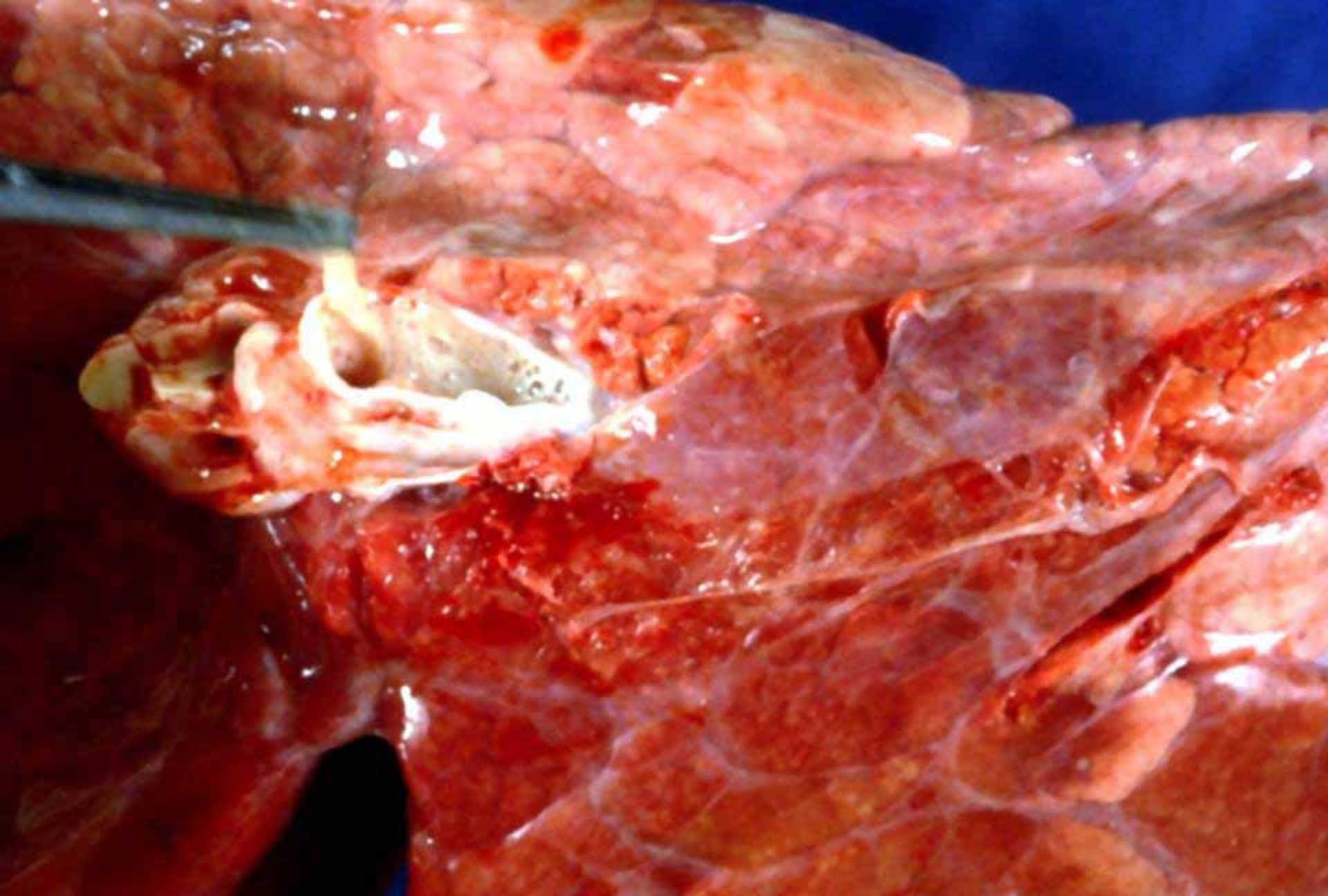
- **Clinical signs**
 - **Slowly spreading nonproductive cough**
 - **Depression in growth rate**
 - **Dyspnea, anorexia, death**
- **Lesions: Catarrhal bronchopneumonia**
- **Confirmation:**
 - **Antigen: Tissue FA, IHC**
 - **Nucleic Acid: PCR**
 - ***Antibodies: CF, ELISA**



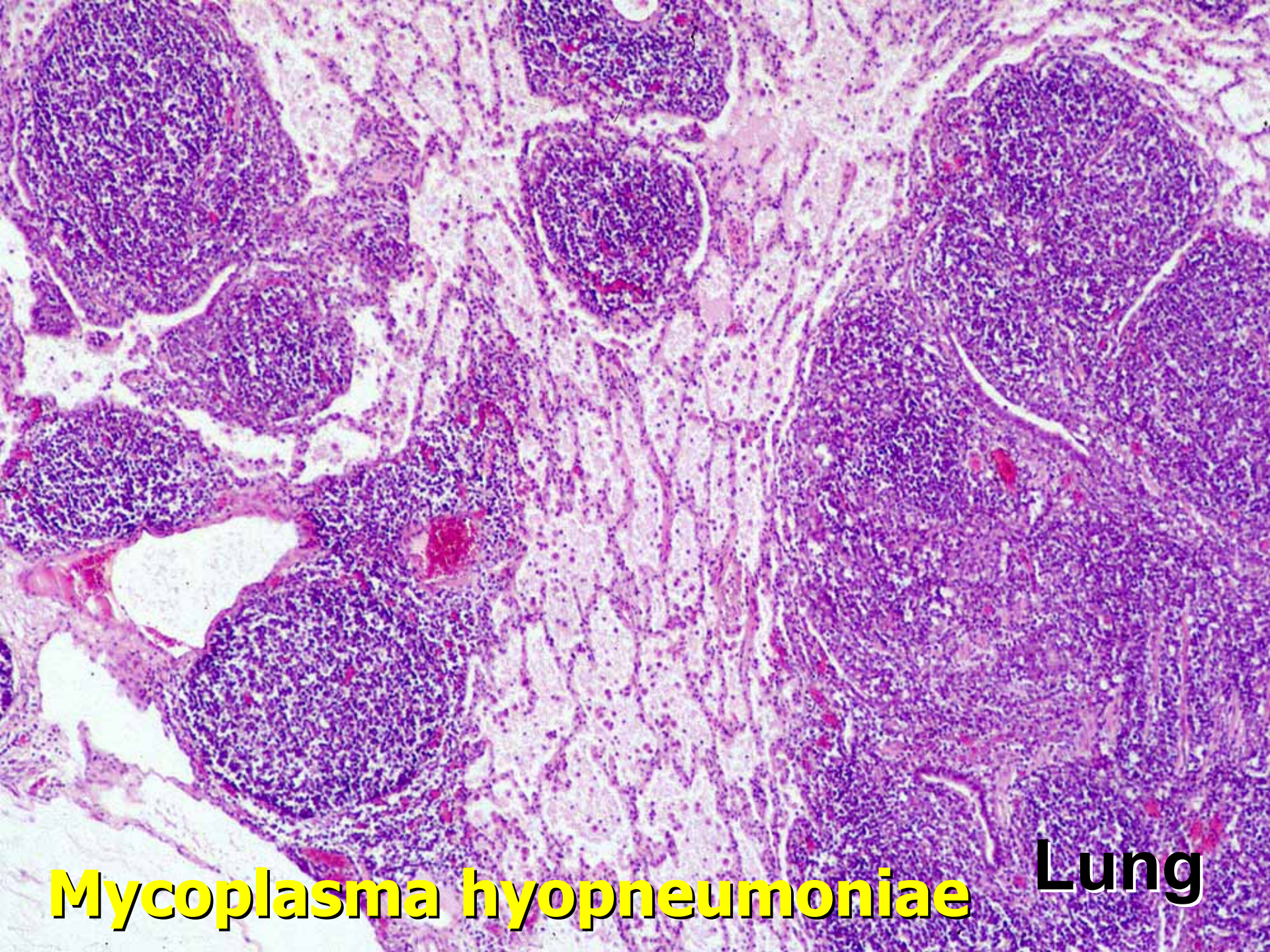
Mycoplasma hyopneumoniae



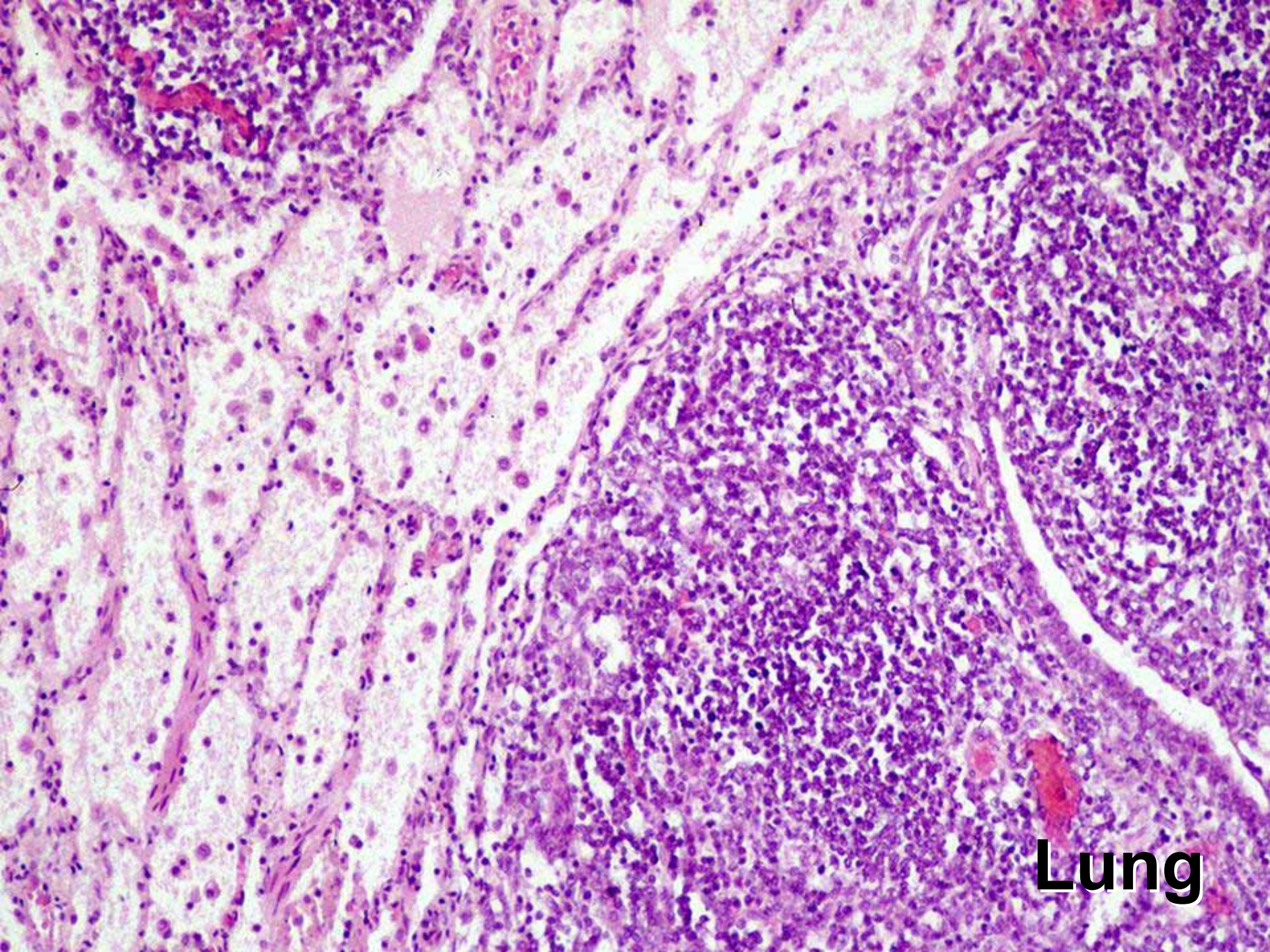
Mycoplasma hyopneumoniae



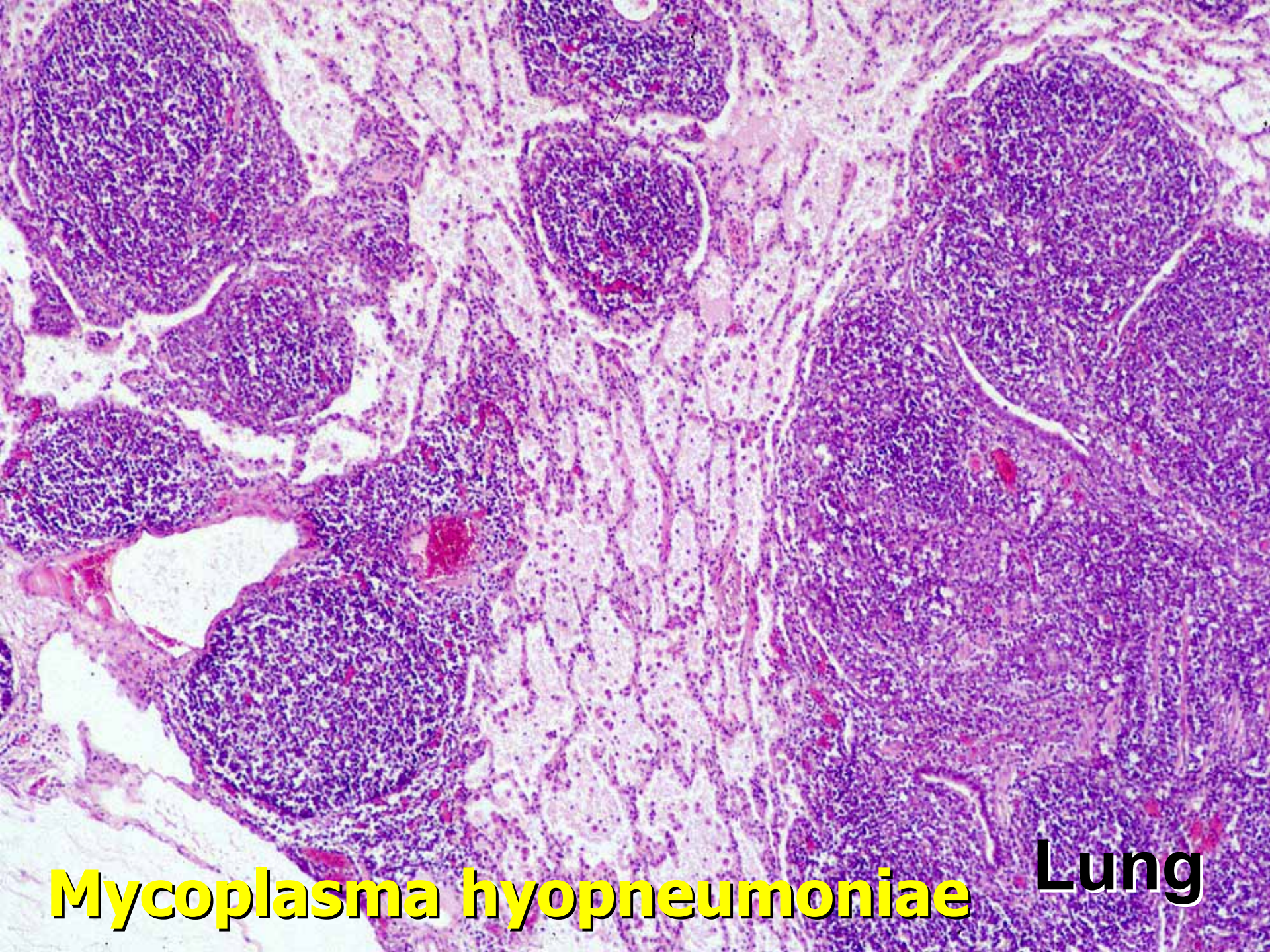
Mycoplasma hyopneumoniae




Mycoplasma hyopneumoniae Lung



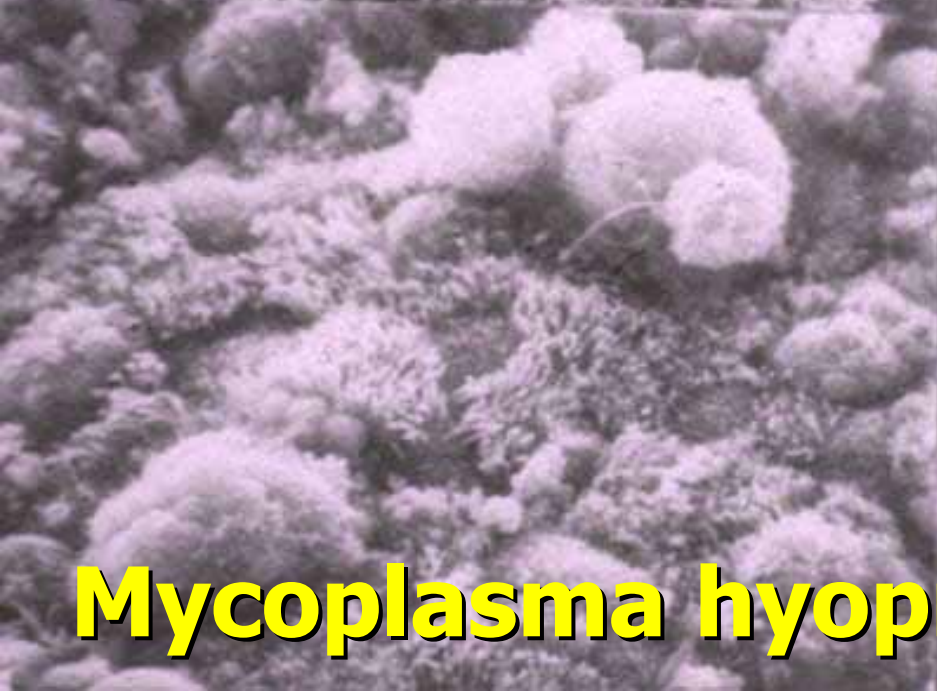Lung



Mycoplasma hyopneumoniae Lung



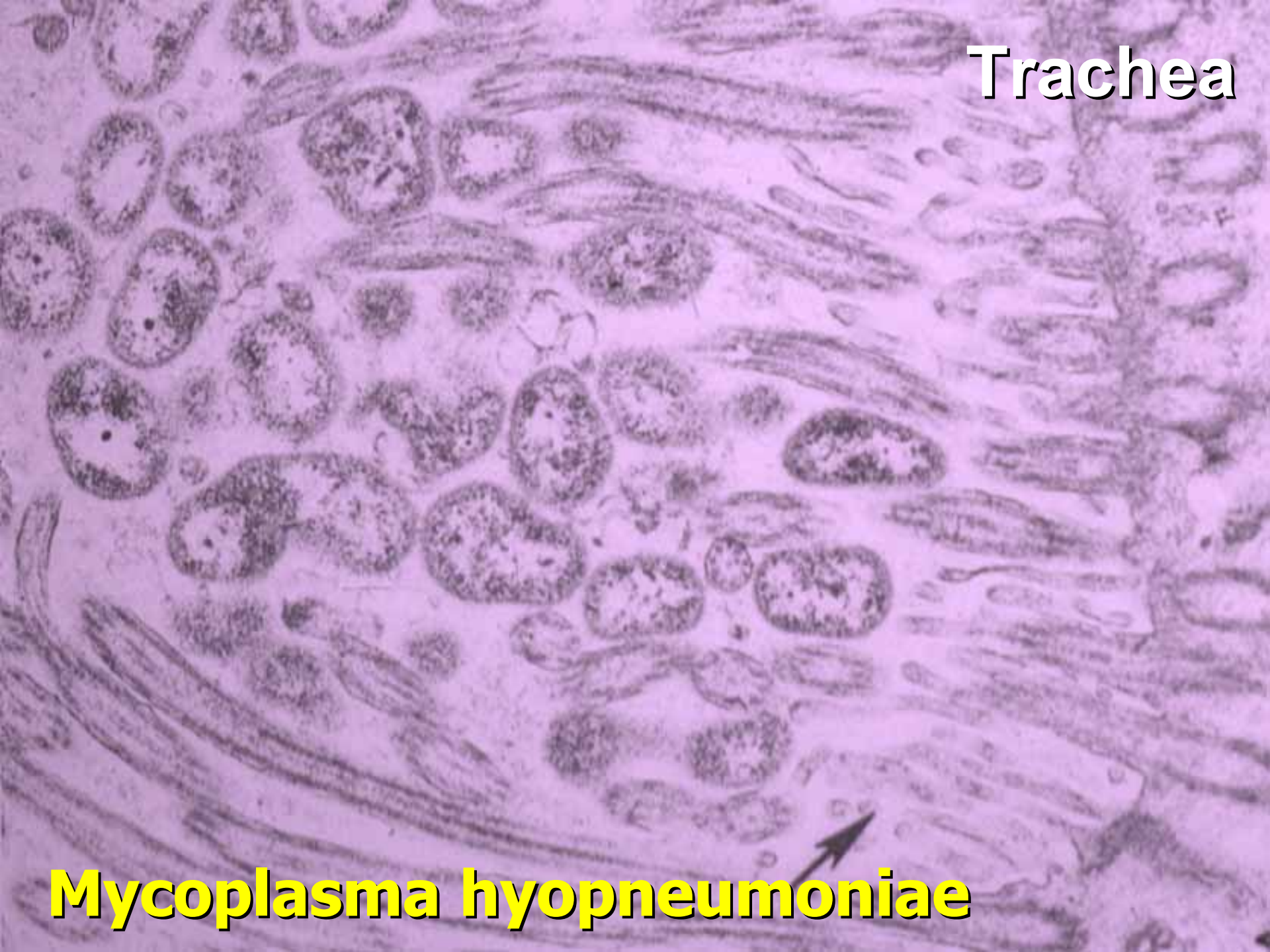Trachea



Mycoplasma hyopneumoniae

Trachea

Mycoplasma hyopneumoniae



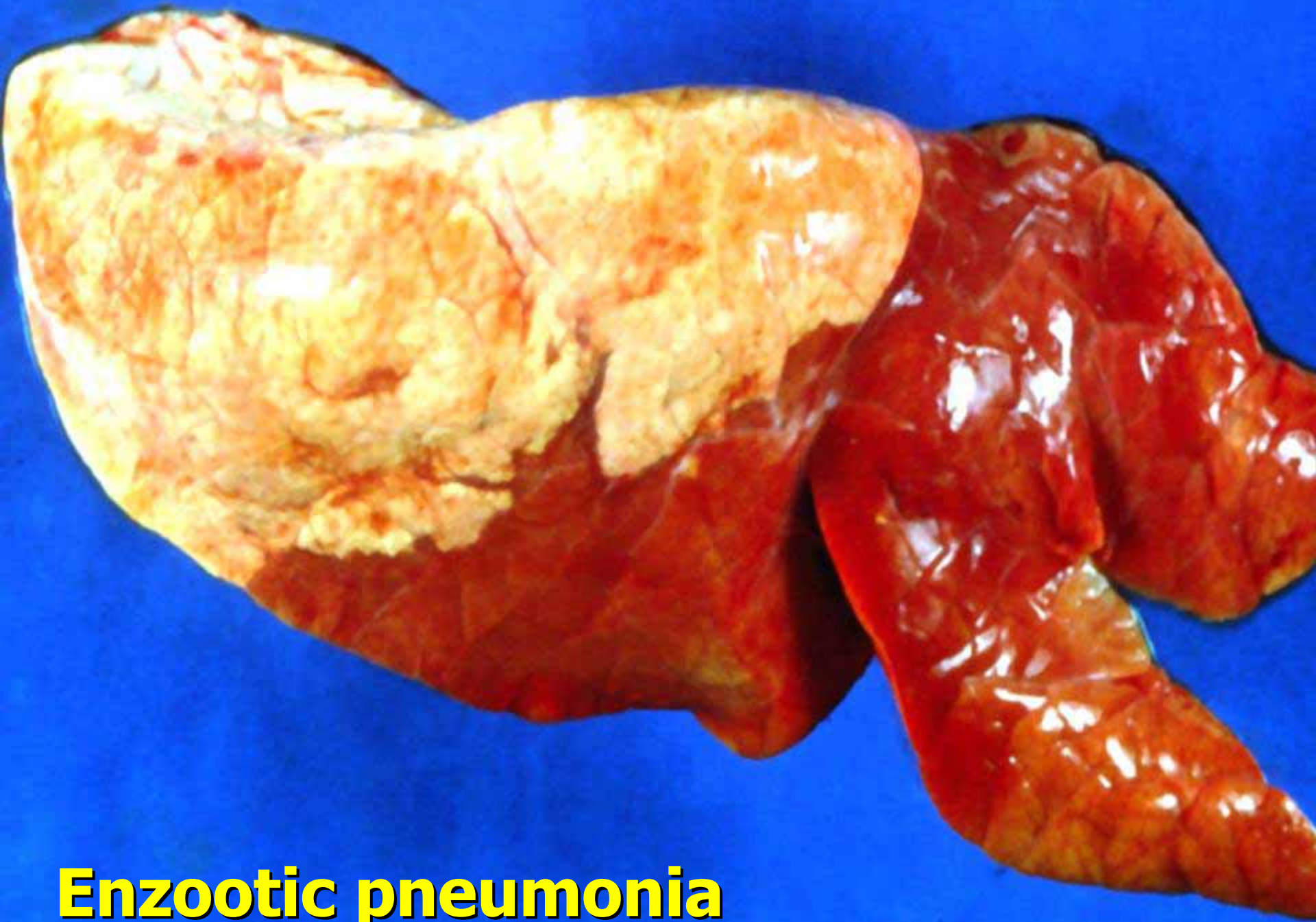Secondary Inhaled Pathogens

Purulent Bronchopneumonia

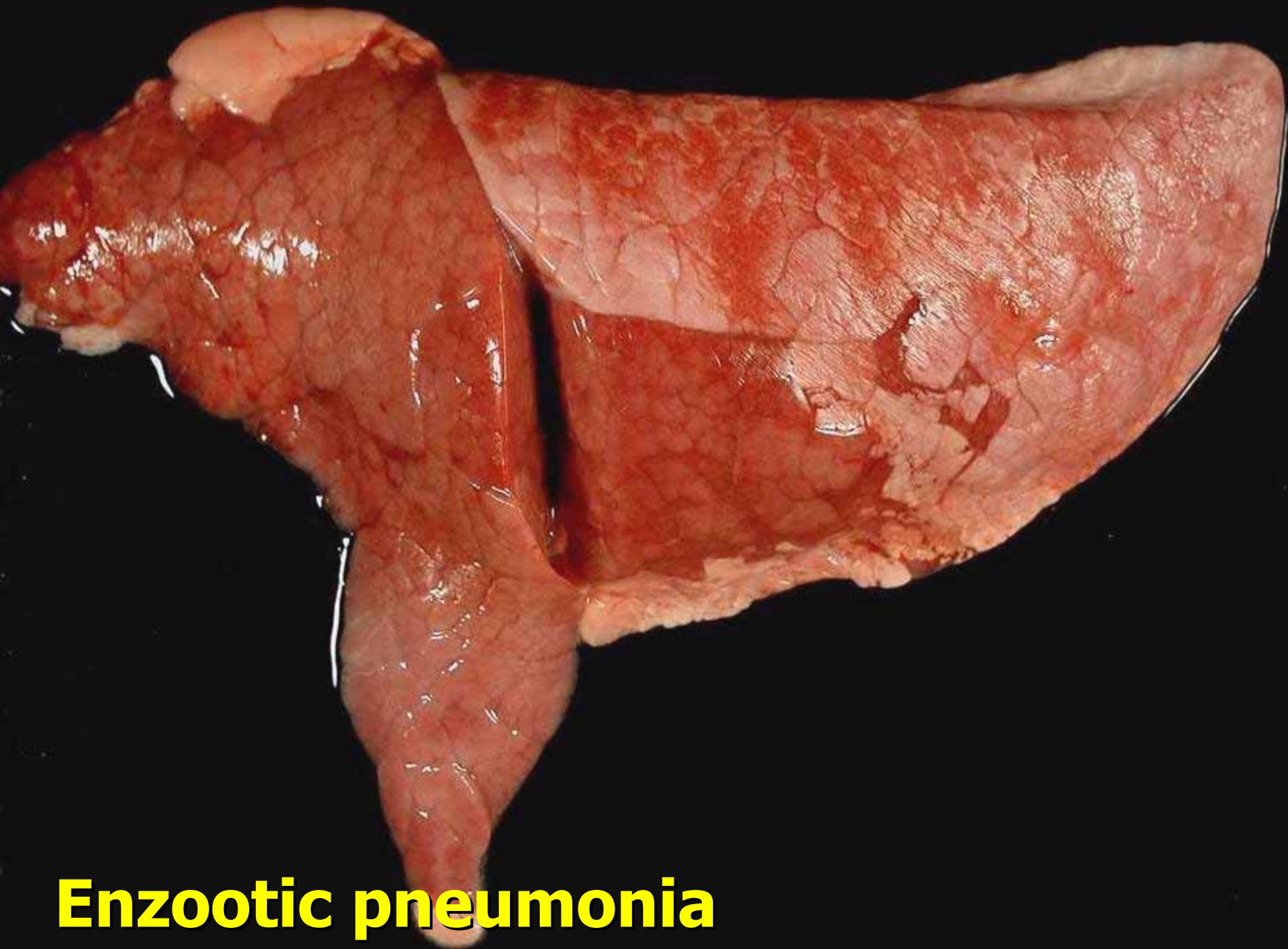
- upper respiratory commensals
- follow Mycoplasma or viral infections
- “Enzootic Pneumonia” - may not be!
- most common:
 - *P. multocida*
 - *S. suis*
 - *H. parasuis*
 - *M. hyorhinis*
 - *A. pyogenes*
 - *B. bronchiseptica*
- diagnosis: culture

Pasteurella multocida

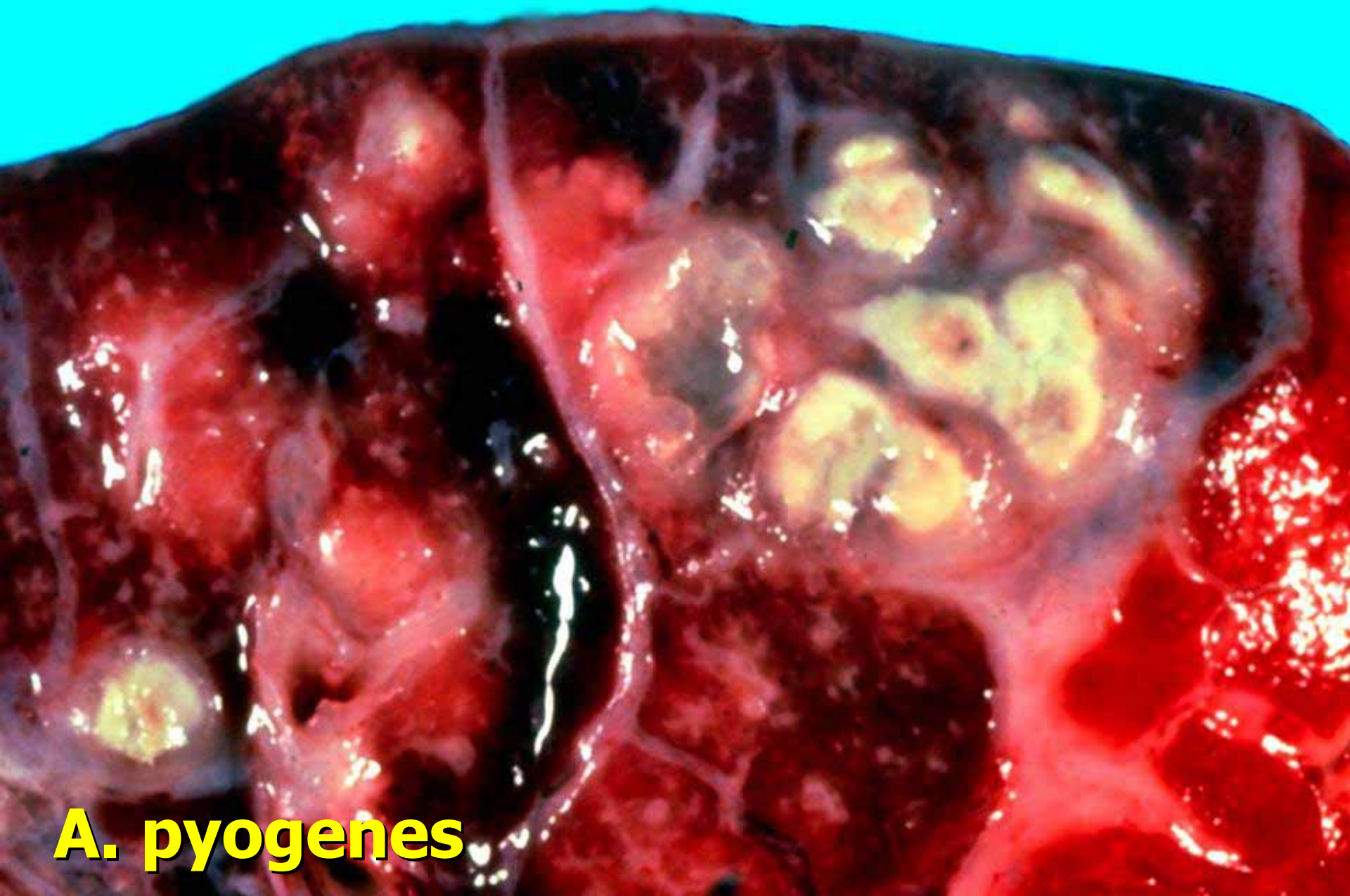
- **common in nearly all swine herds**
- **non-toxigenic and toxigenic strains**
- **most common bacterial isolate from pneumonic lungs in slaughter swine**
- **lung isolates**
 - **most are capsular type A**
 - **most are serotypes 3 or 5 (of 16 total)**
 - **toxin as a virulence factor??**
 - **some strains: pleuritis, abscessation**



Enzootic pneumonia



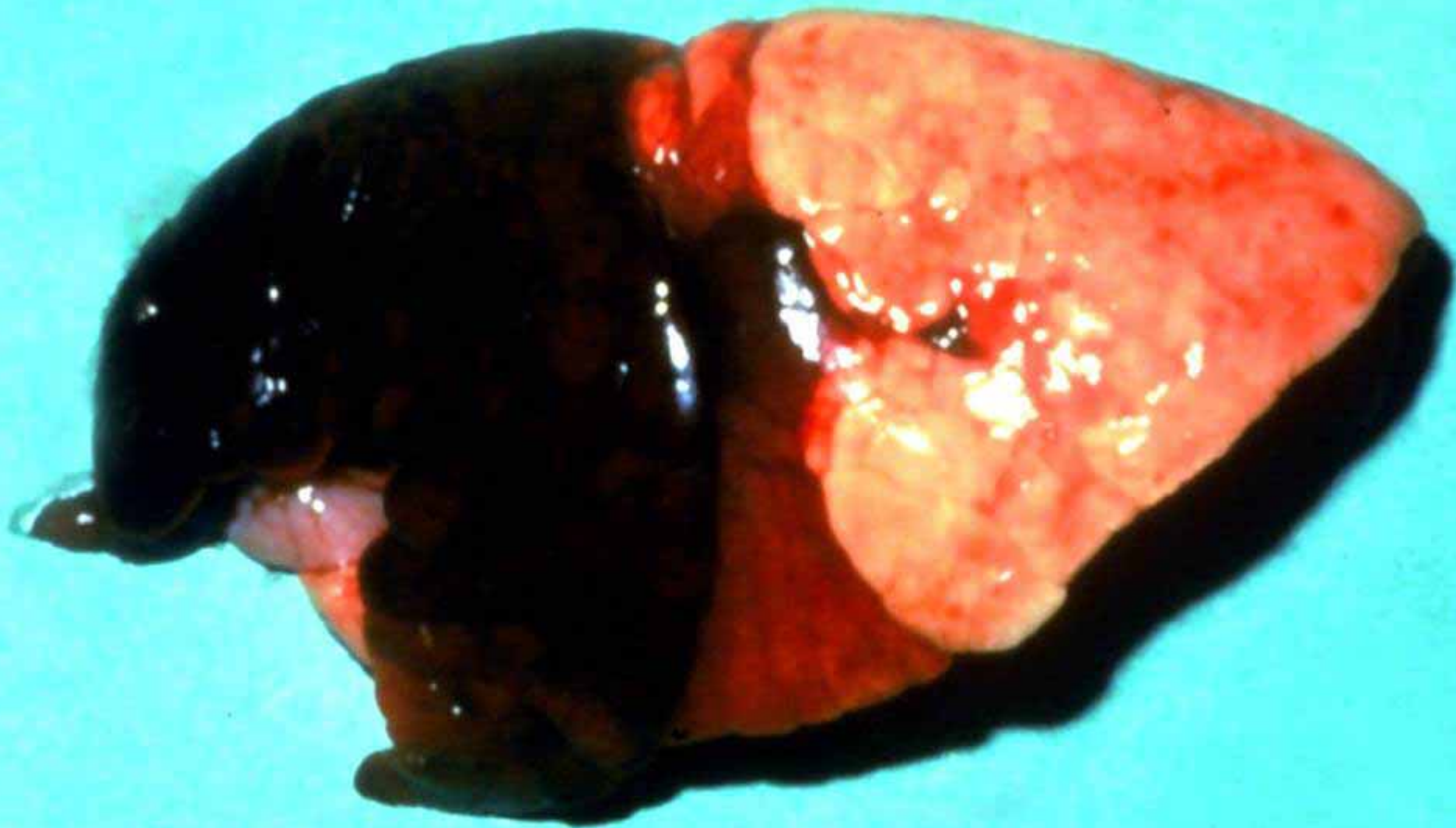
Enzootic pneumonia



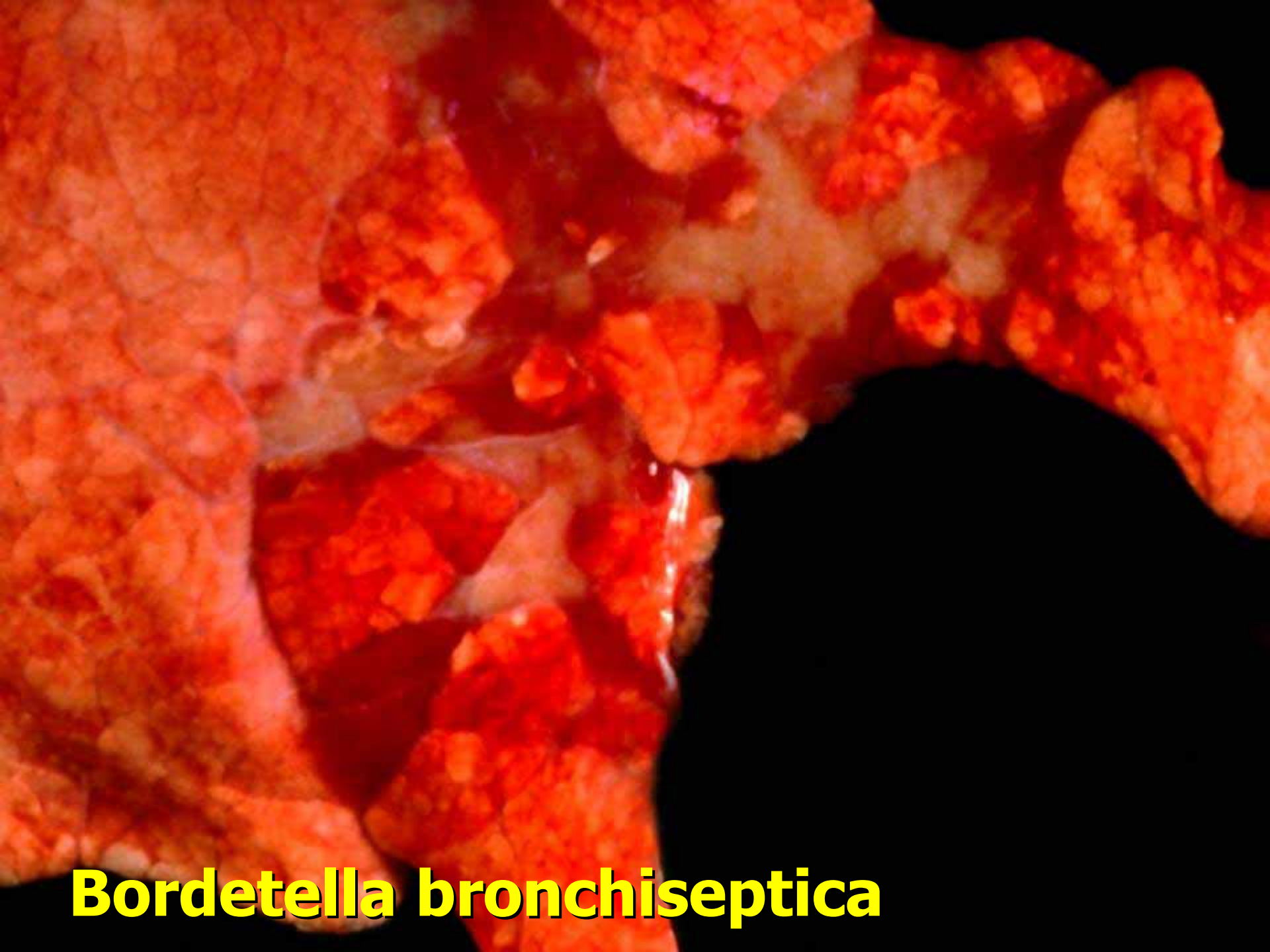A. pyogenes

Bordetella bronchiseptica

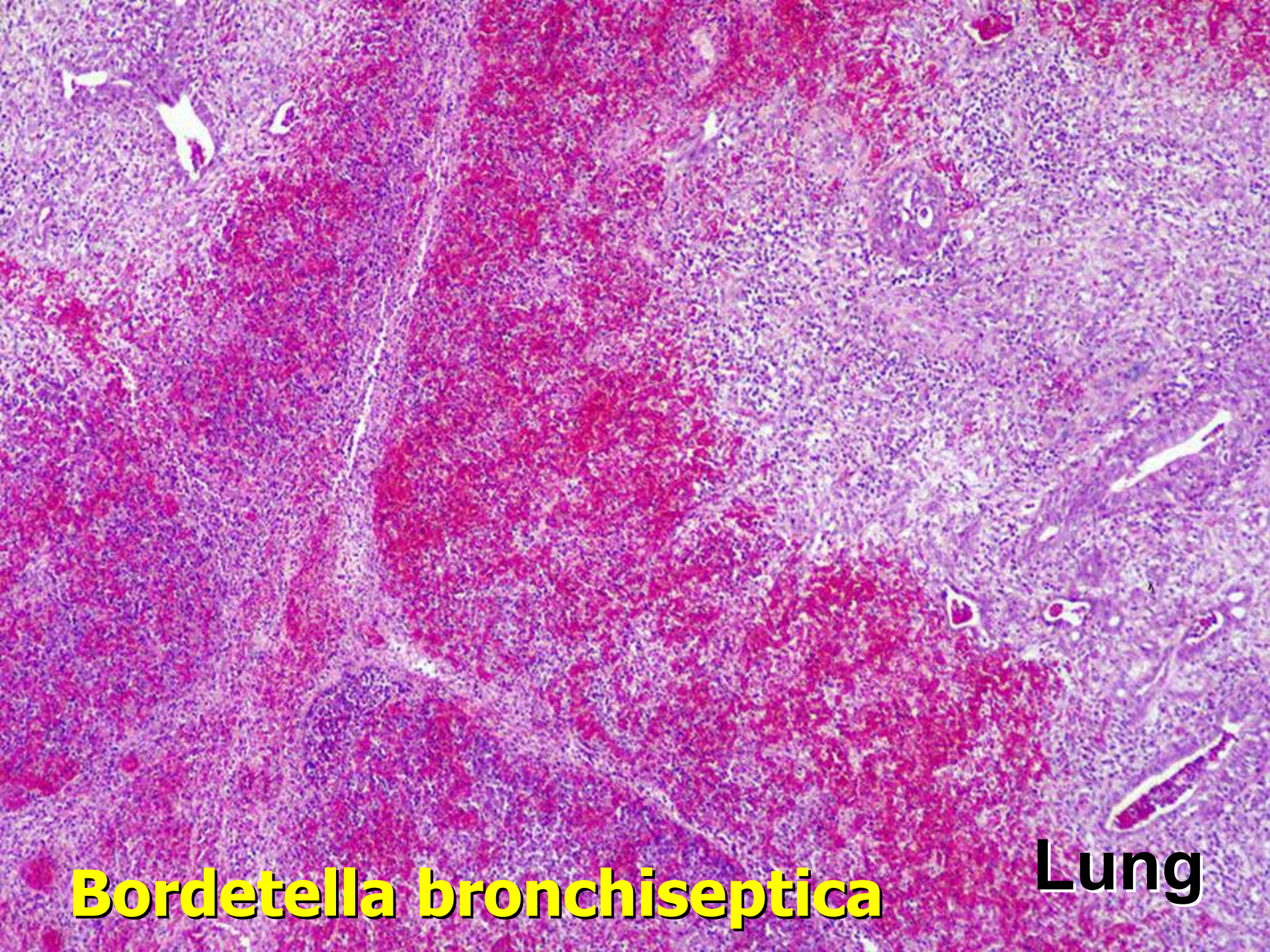
- **primary or secondary inhaled pathogen**
- **Pathogenesis: Colonisation and destruction of cilia in upper respiratory tract, may colonize lung causing broncho-pneumonia (cranial and middle lobes)**
- **primary pathogen: first few weeks of life**
- **lobular necrohemorrhagic bronchopneumonia**
 - **Coughing, sneezing +/- epistaxis and mucopurulent nasal discharge, mild (reversible) turbinate atrophy (regressive atrophic rhinitis), death**
- **chronic progressive bronchopneumonia**
 - **Coughing and poor growth**



Bordetella bronchiseptica

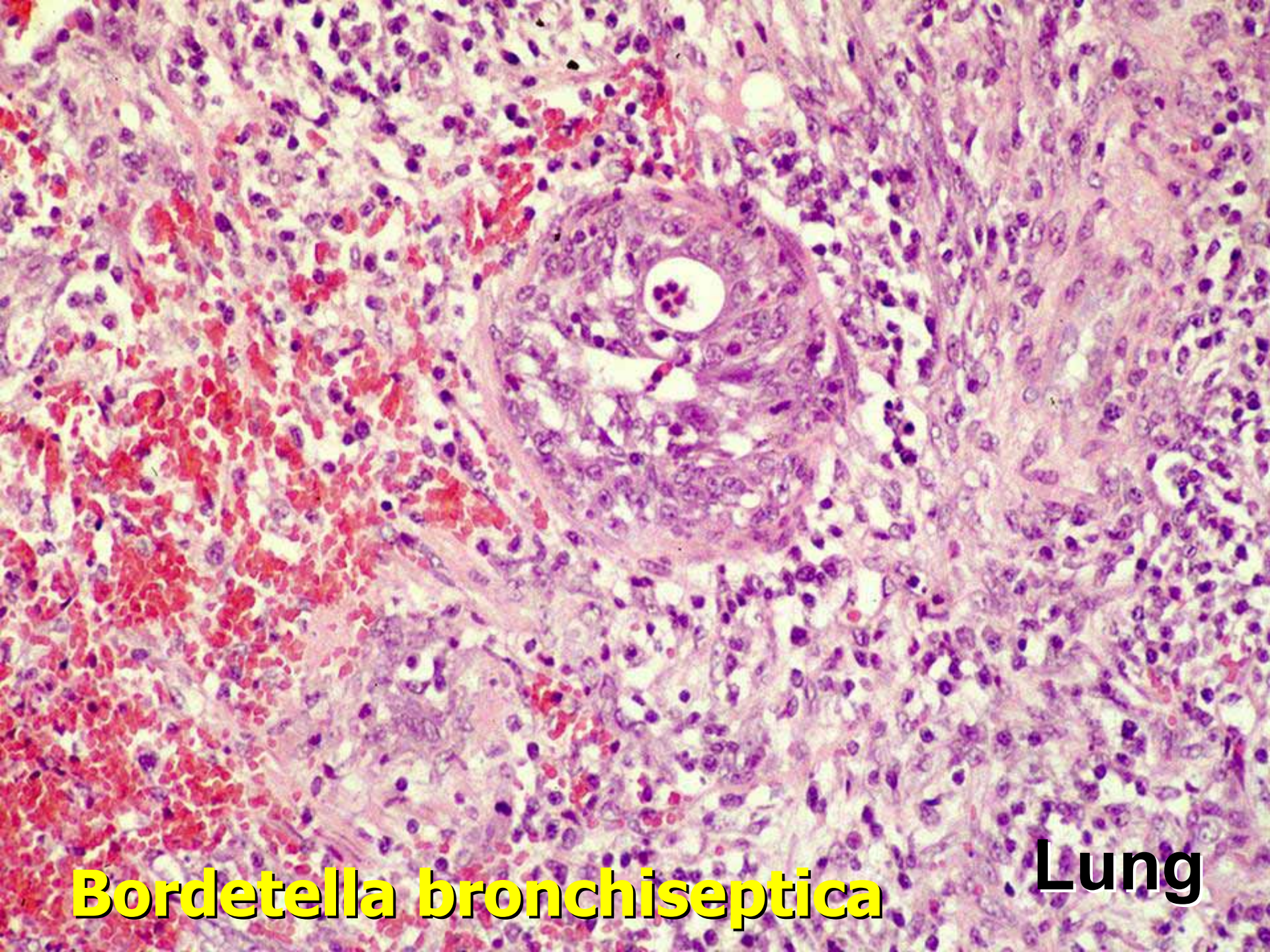


Bordetella bronchiseptica



Bordetella bronchiseptica

Lung



Bordetella bronchiseptica

Lung



Actinobacillus pleuropneumoniae

- **fastidious encapsulated coccobacillus found only in swine**
- **biovar 1: require NAD for growth**
- **biovar 2: NAD not required for growth**
- **15 serotypes**
 - **predominant serotypes vary by region**
 - **serotypes and strains vary in virulence**

Actinobacillus pleuropneumoniae

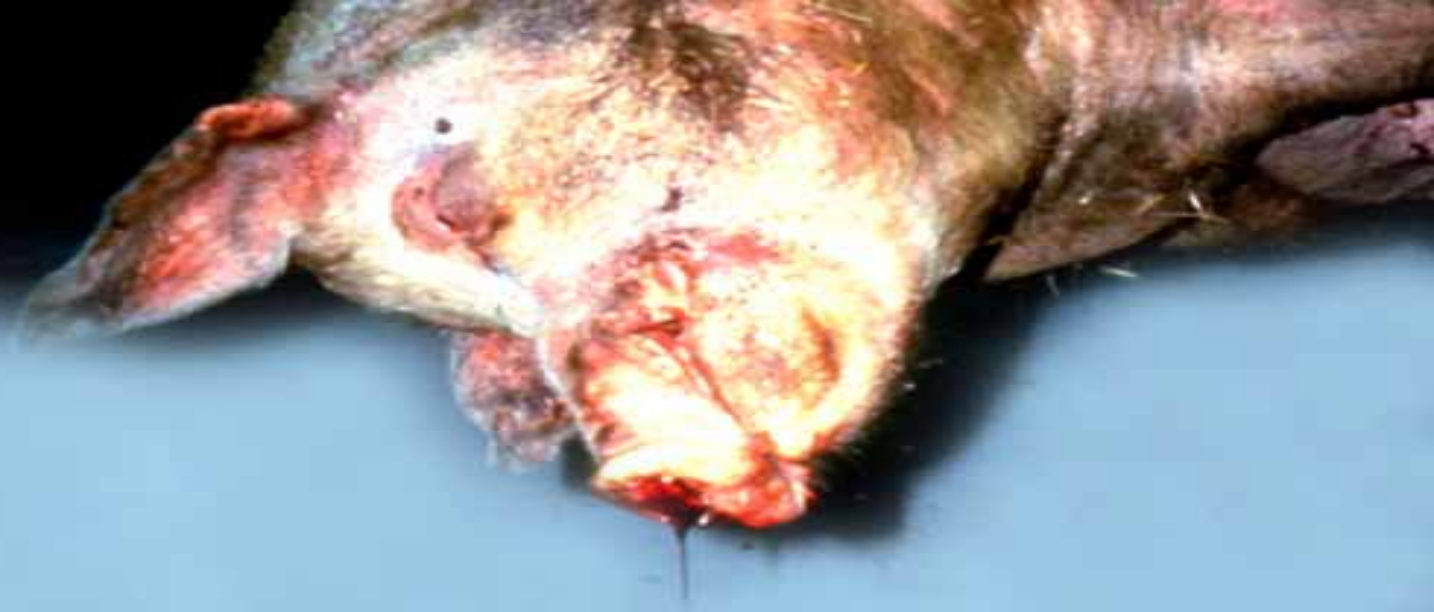Virulence Factors & Epidemiology

- **Virulence factors**
 - **Capsule**
 - **Endotoxin**
 - **Exotoxins: APX I, II, III**
 - **Hemolysin APX I, II**
 - **Cytolysin APX I, II, III**
- **Epidemiology**
 - **Carriers: tonsil, nasal cavity, lung**
 - **Carriers may be seronegative**

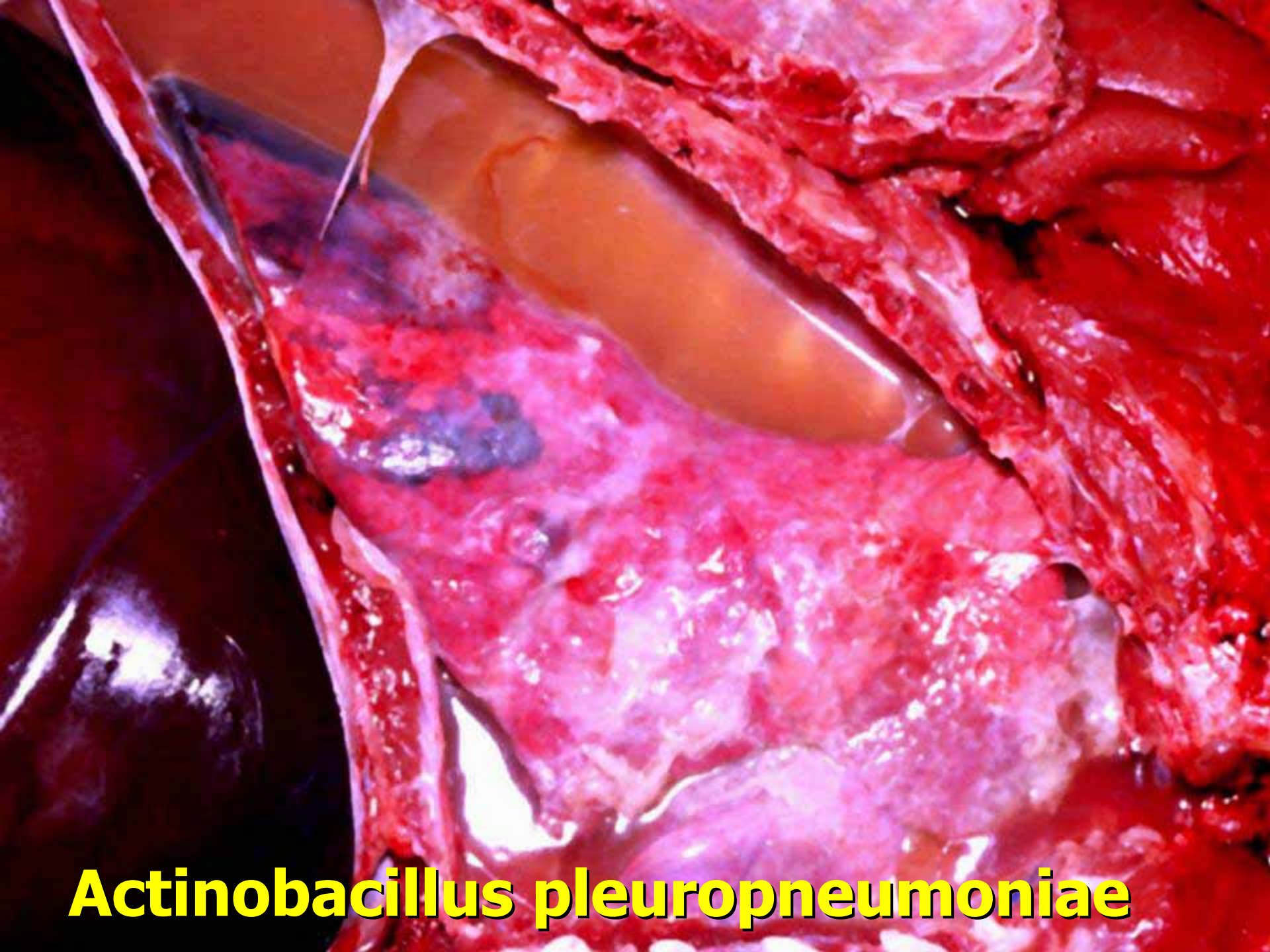
Actinobacillus pleuropneumoniae

Diagnosis

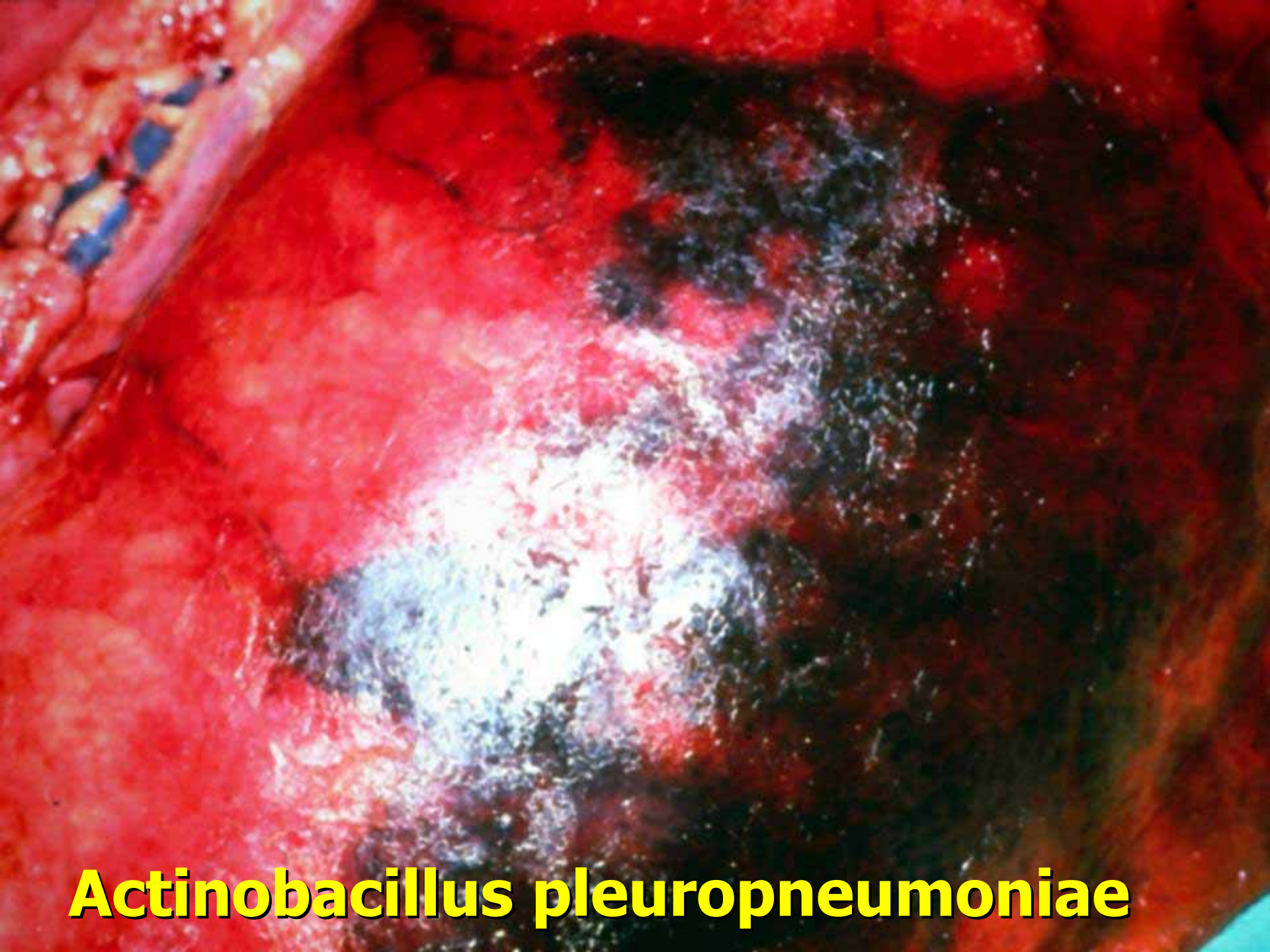
- **Clinical signs:**
 - most common in 3-6 month-old pigs
 - peracute - chronic
 - pyrexia, dyspnea, hemoptosis, death, anorexia
- **Lesions:** Fibrionecrotic hemorrhagic pleuropneumonia
- **Confirmation:**
 - Culture: fresh lung from untreated animals
 - Antigen: Agglutination, Co-agglutination, ELISA
 - Antibodies: CF, HN, ELISA



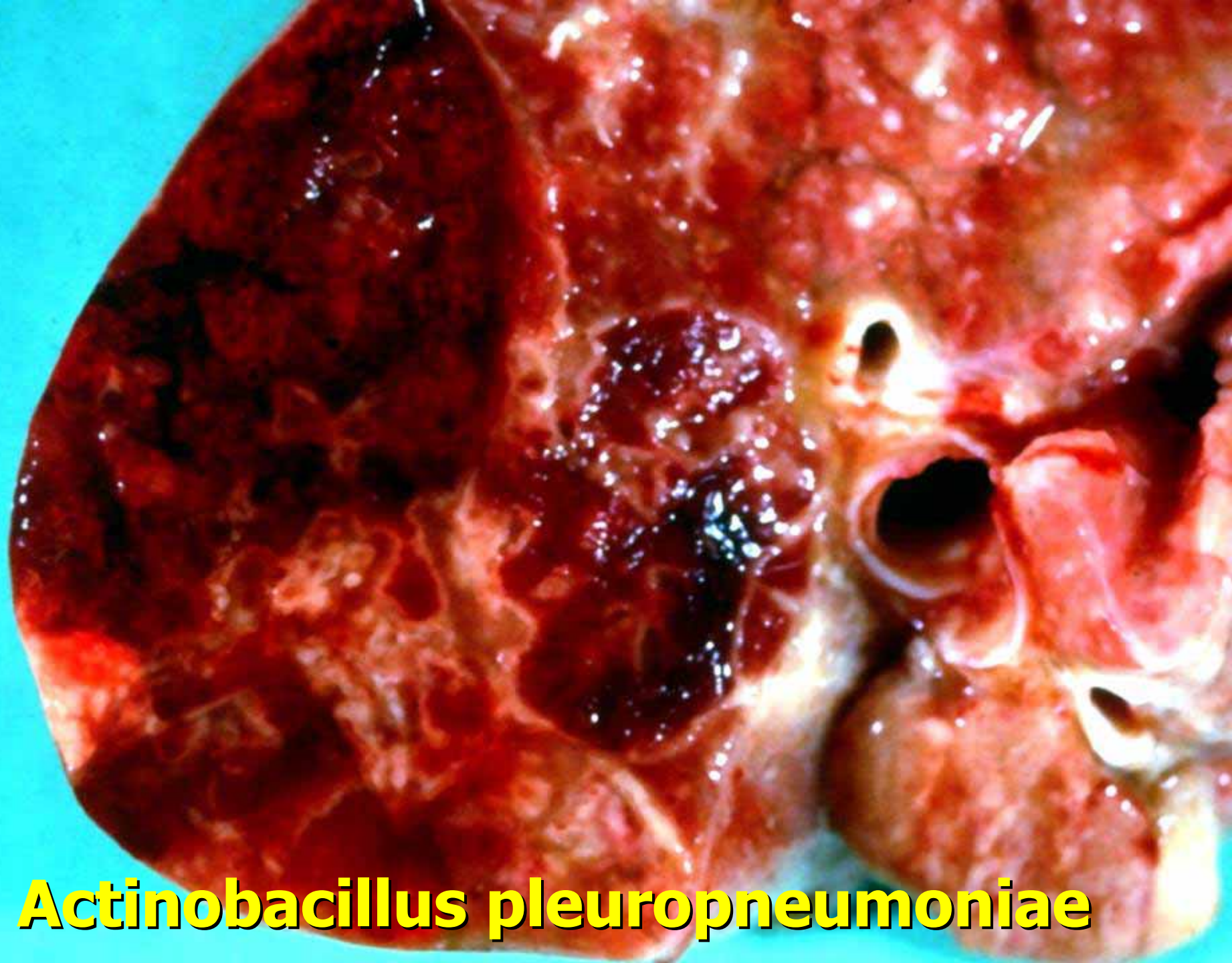
Actinobacillus pleuropneumoniae



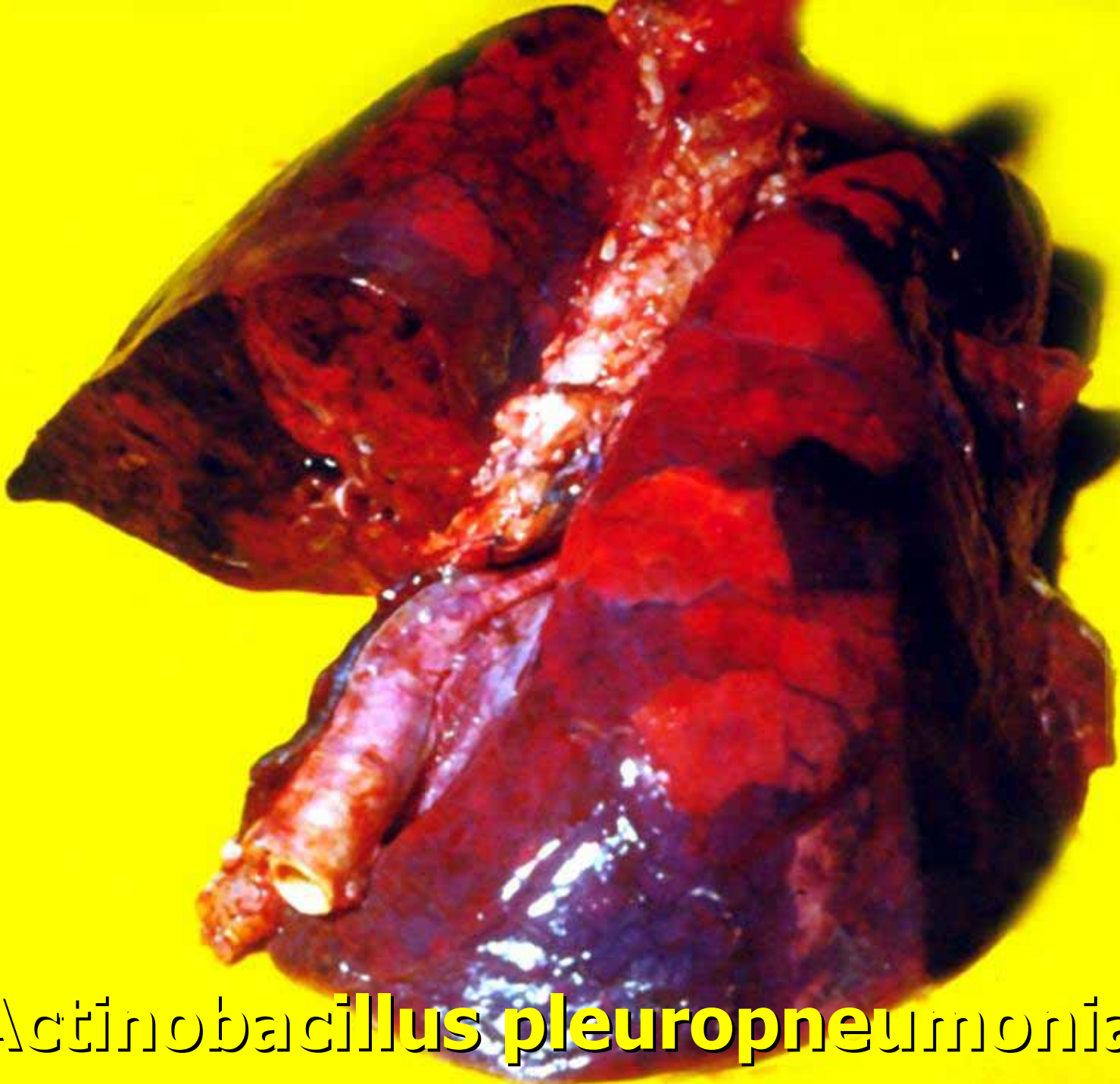
Actinobacillus pleuropneumoniae



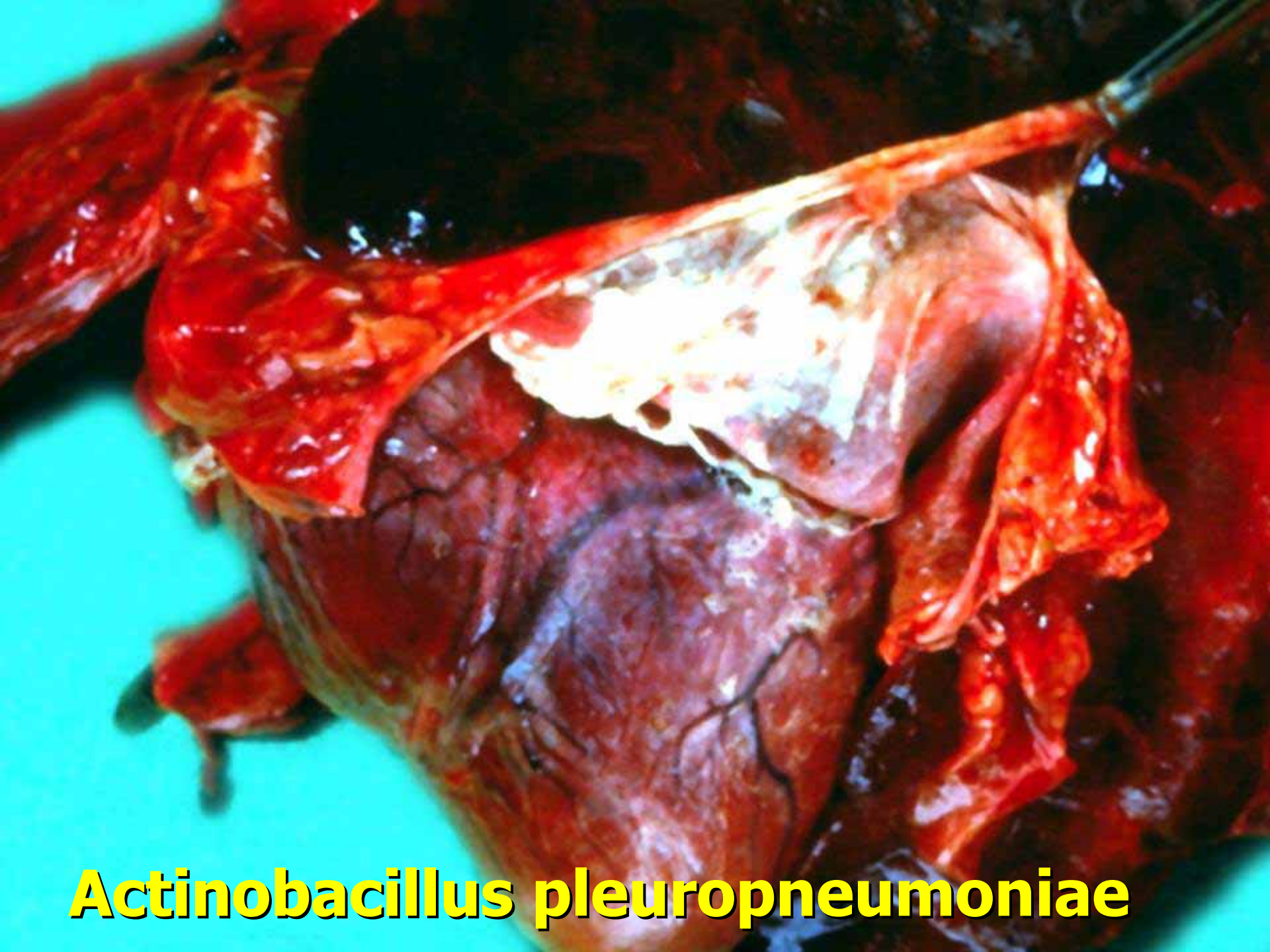
Actinobacillus pleuropneumoniae



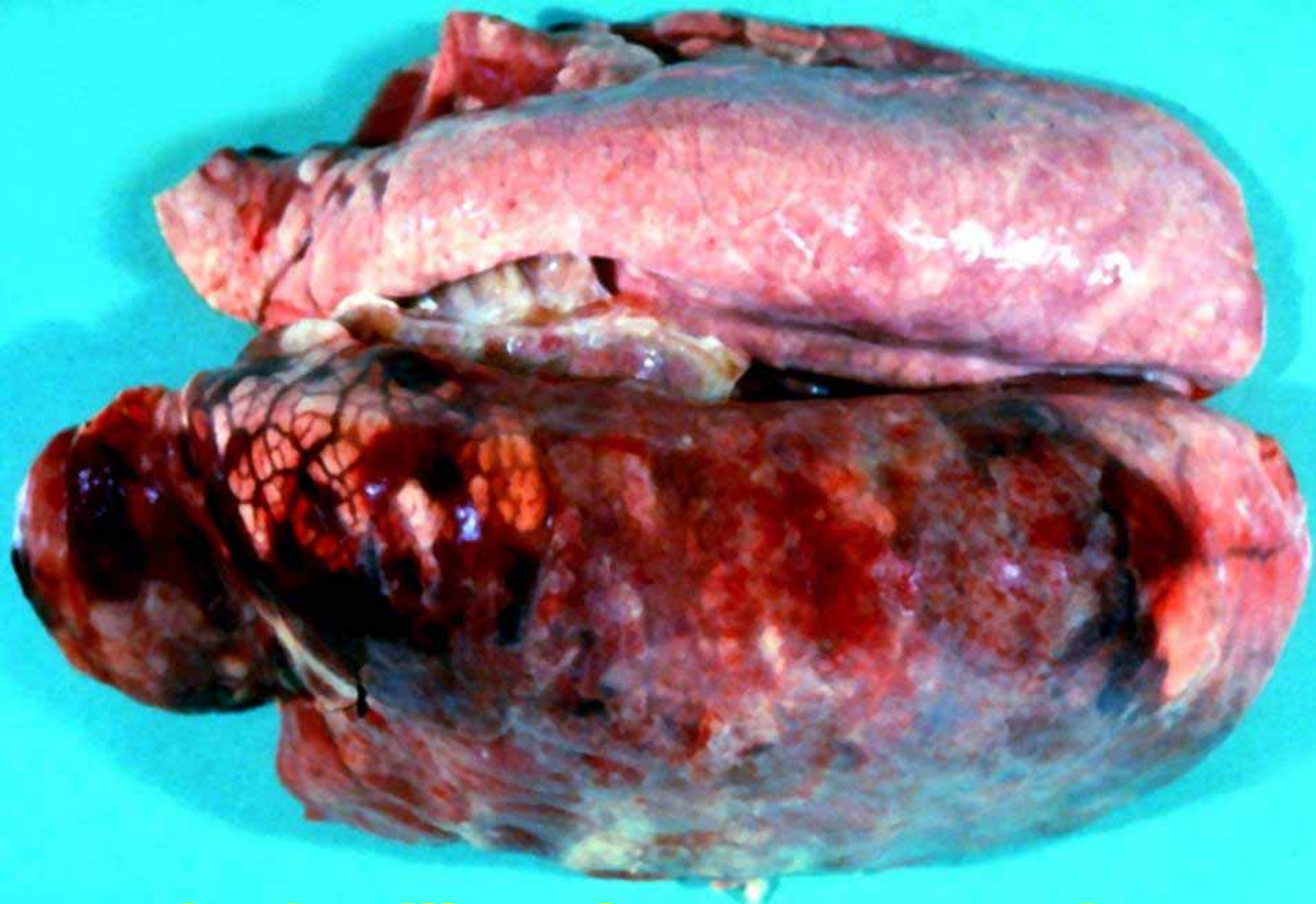
Actinobacillus pleuropneumoniae



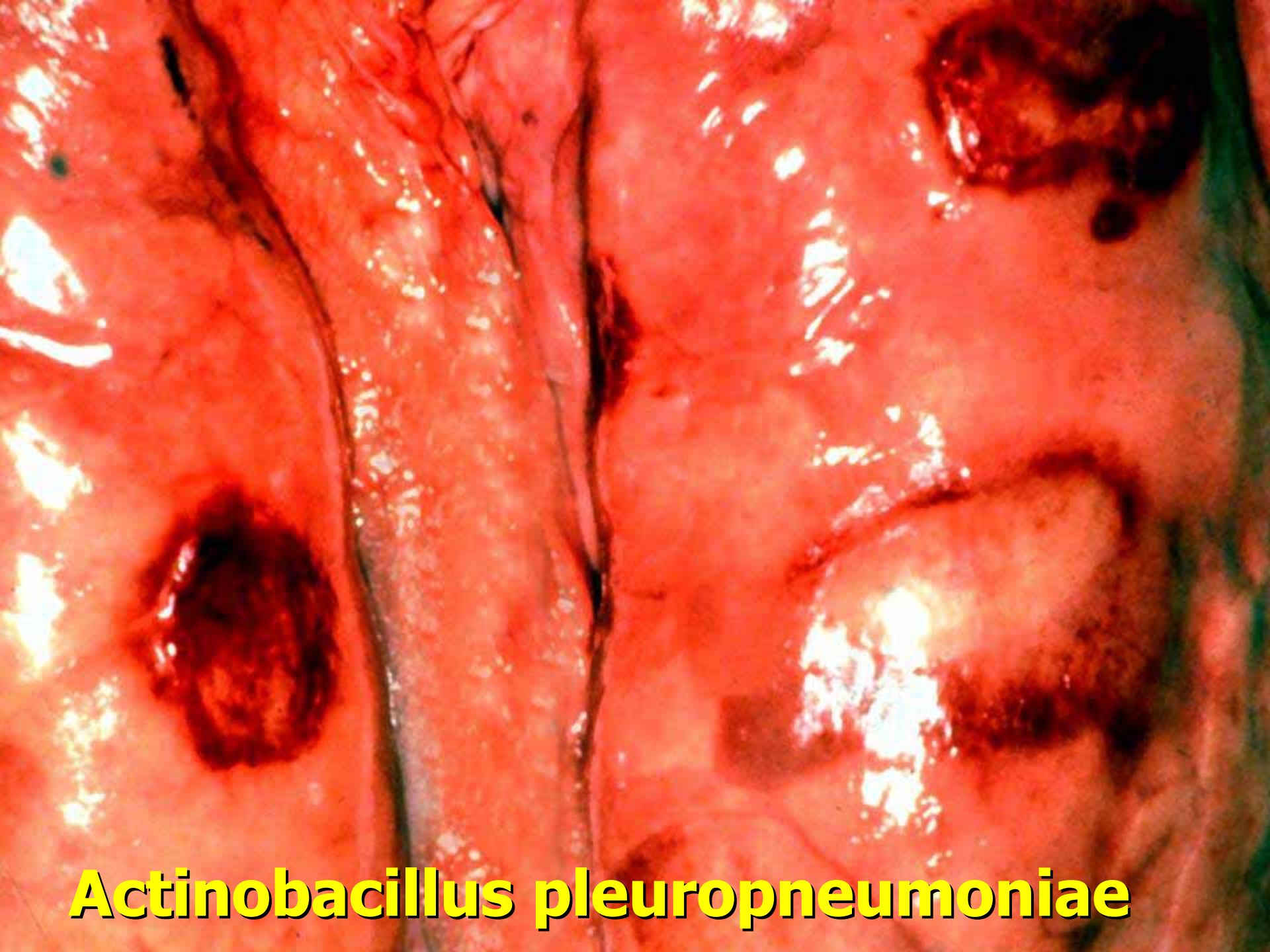
Actinobacillus pleuropneumoniae



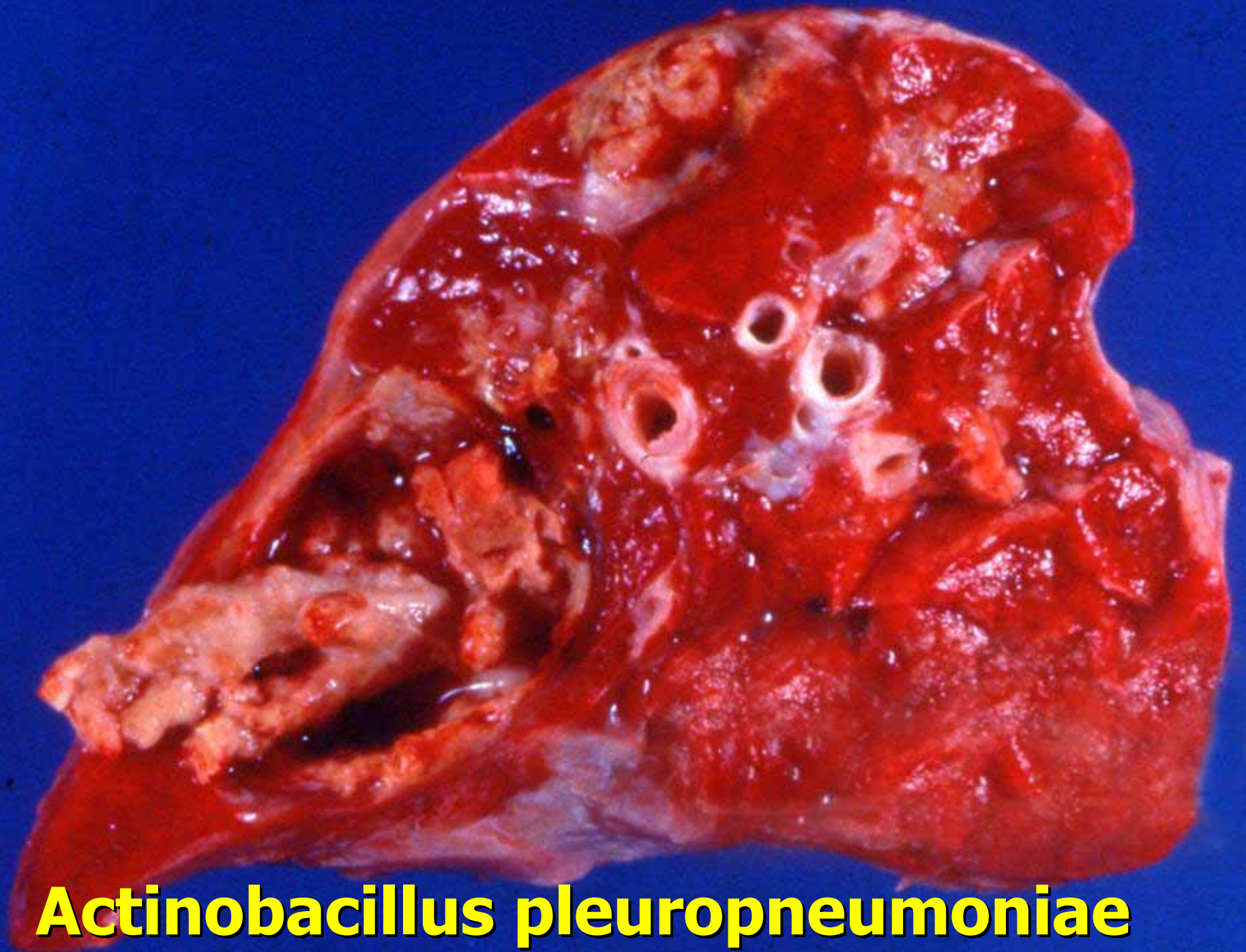
Actinobacillus pleuropneumoniae



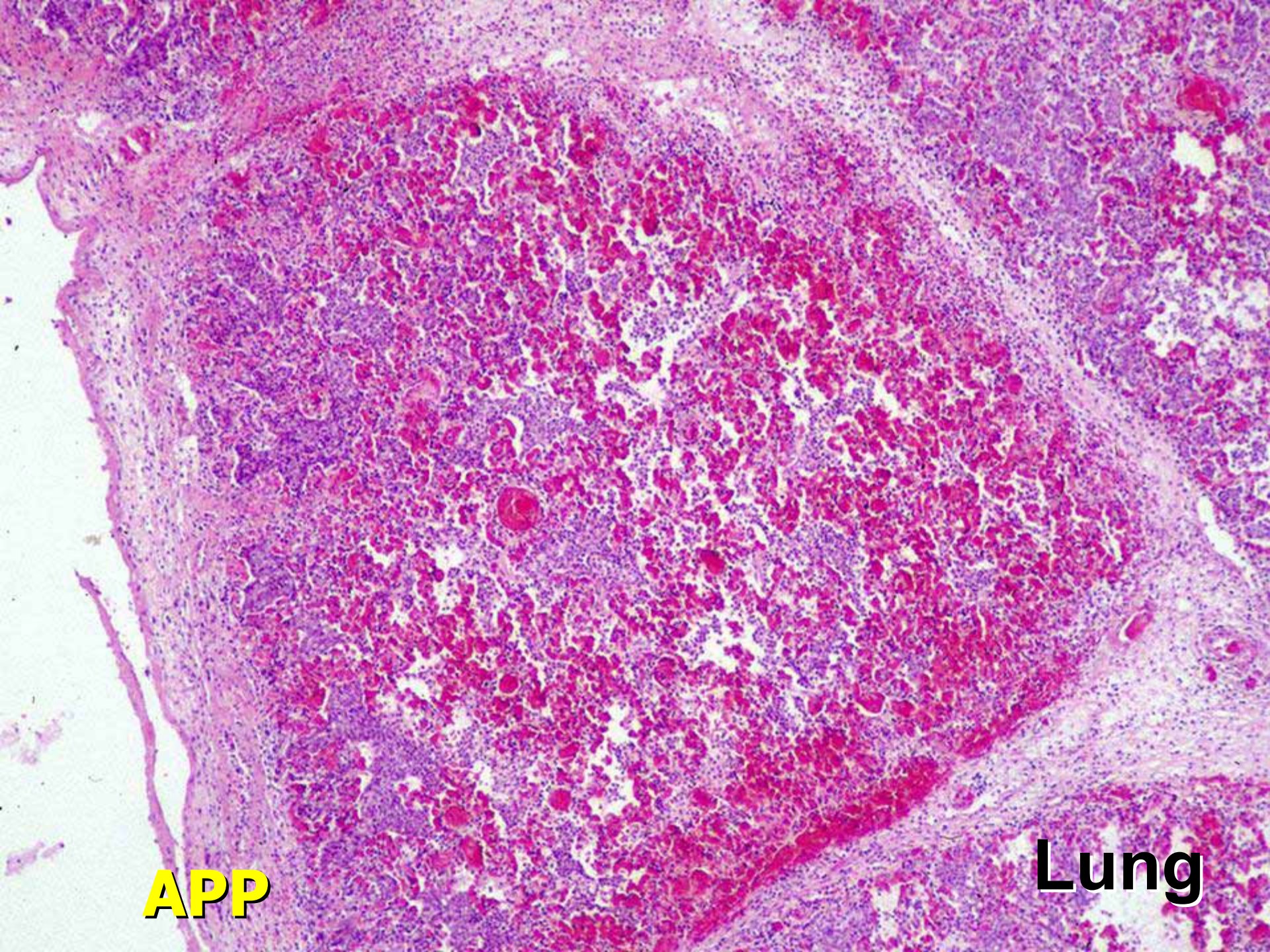
Actinobacillus pleuropneumoniae



Actinobacillus pleuropneumoniae

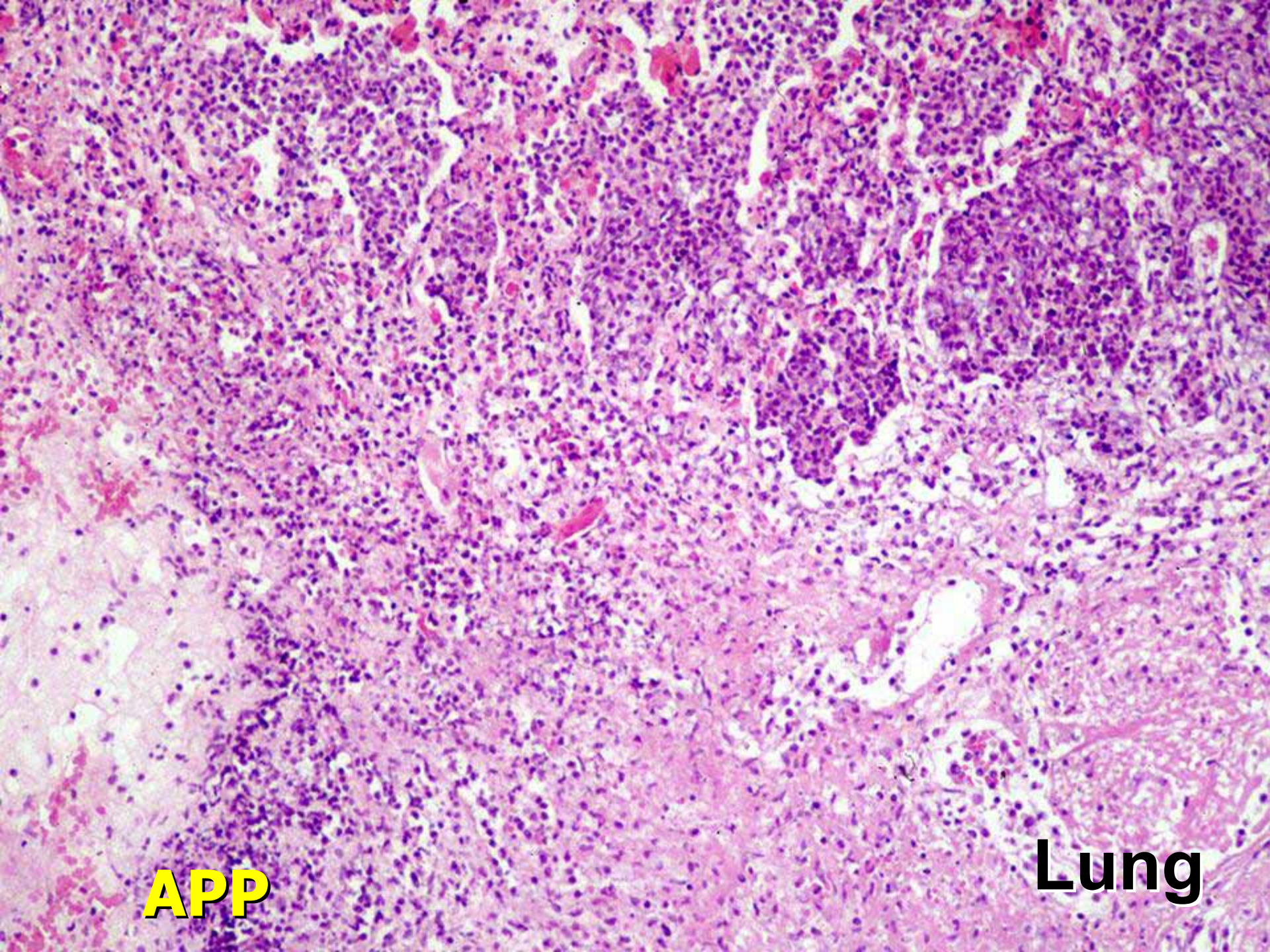


Actinobacillus pleuropneumoniae



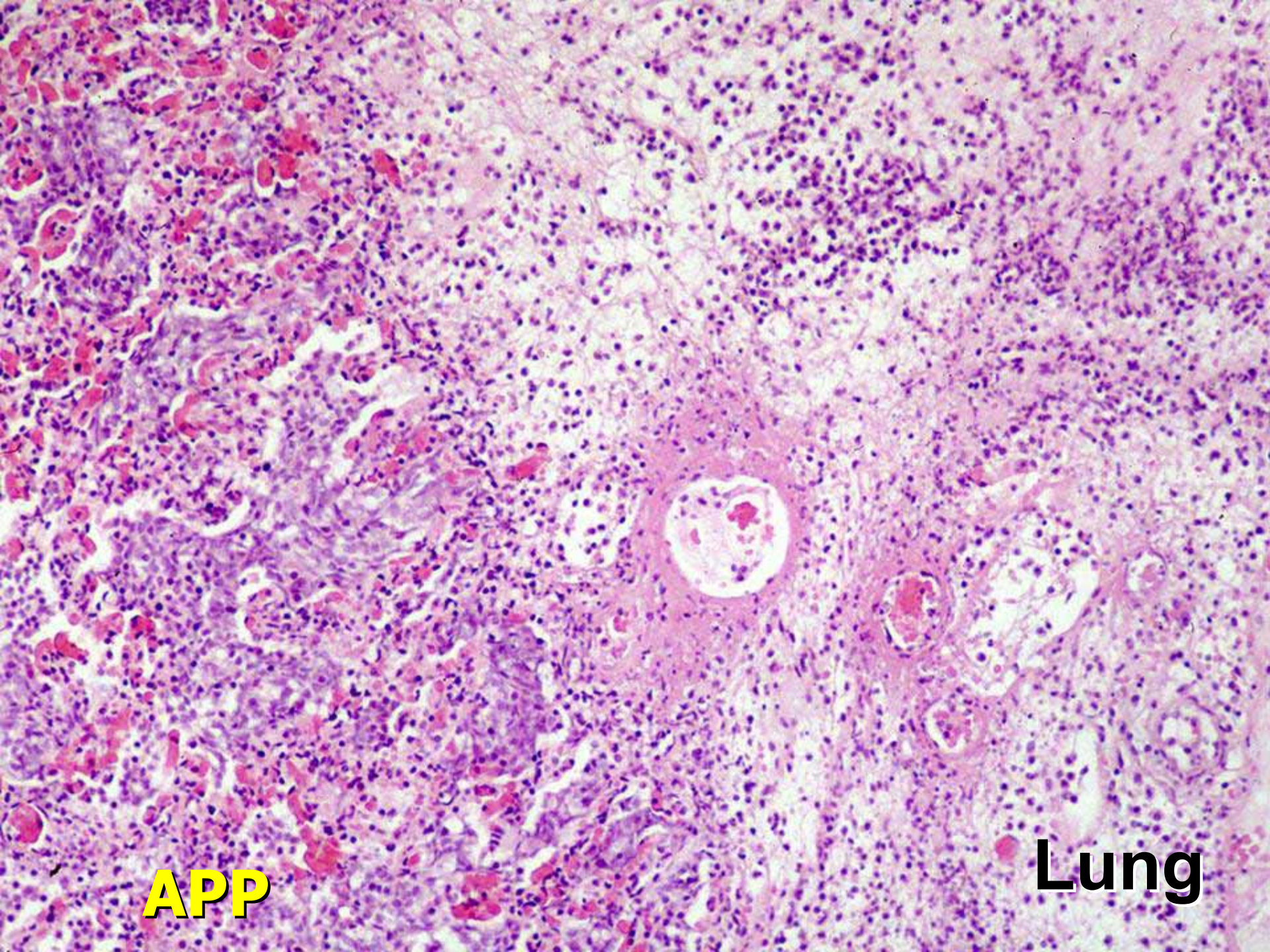
APP

Lung



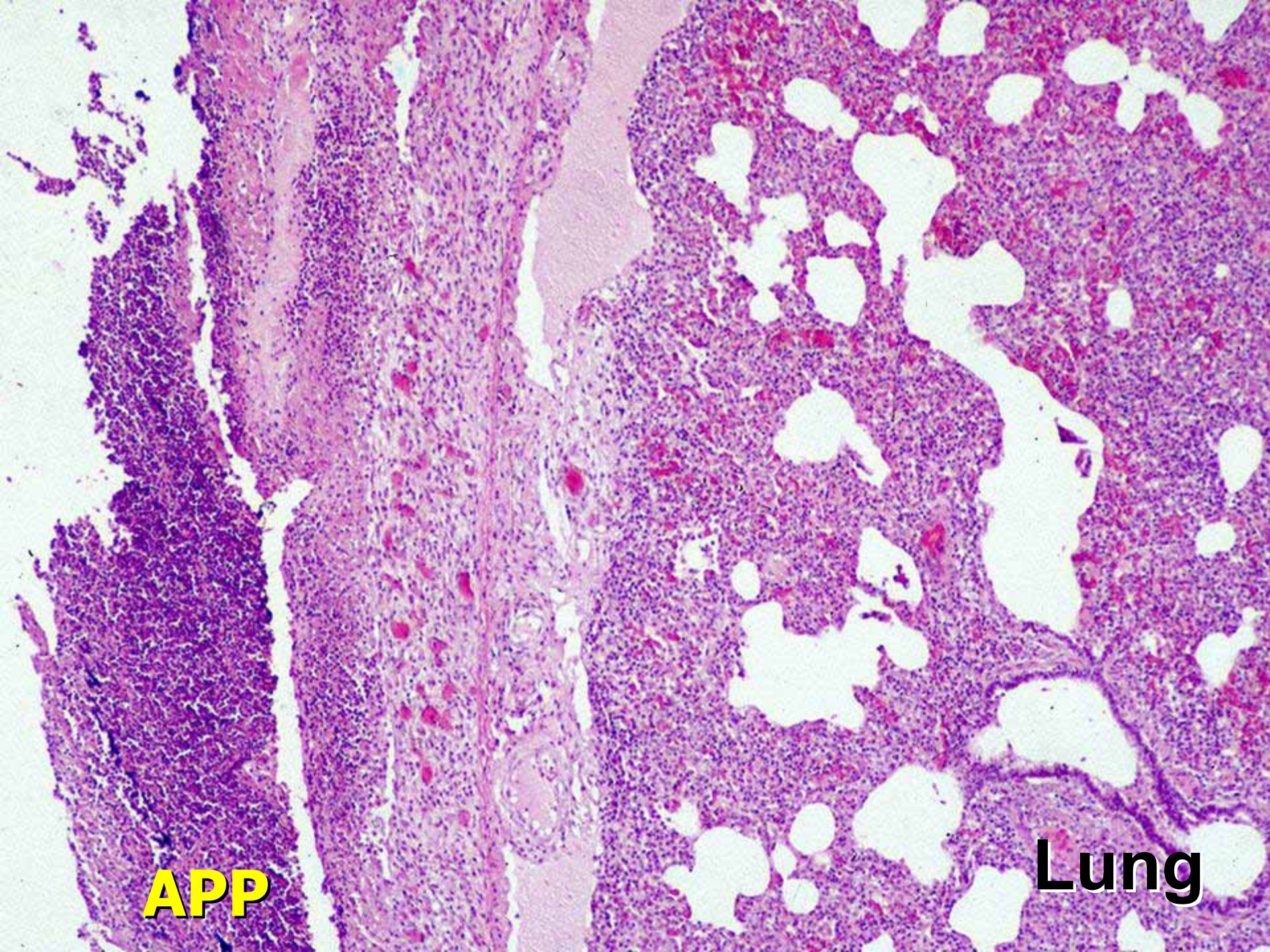
APP

Lung



APP


Lung



APP

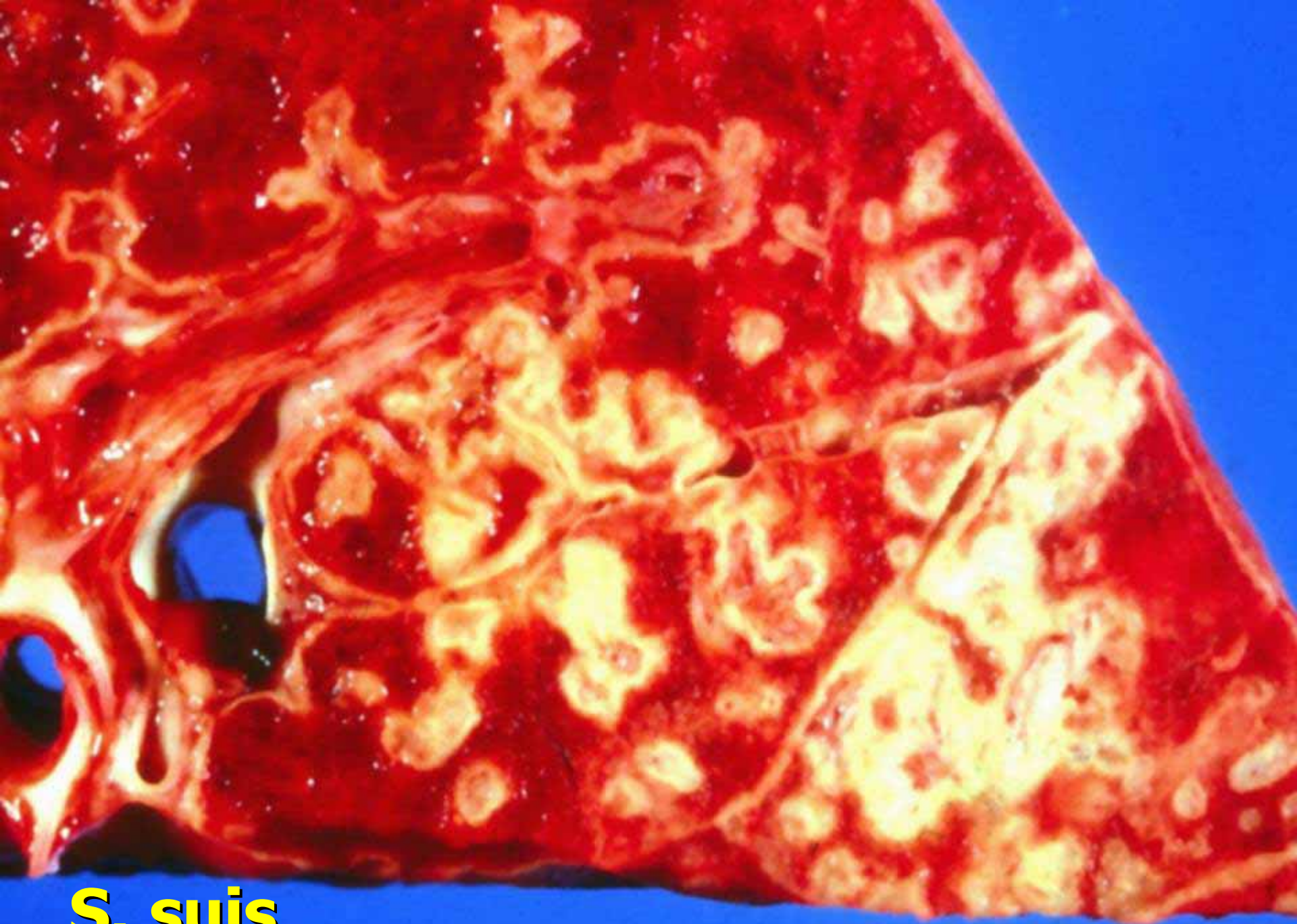Lung

OH, D-D-DEAR DEAR... I SEEM TO
HAVE SPILLED YOUR D-DINNER ALL
OVER M-ME...

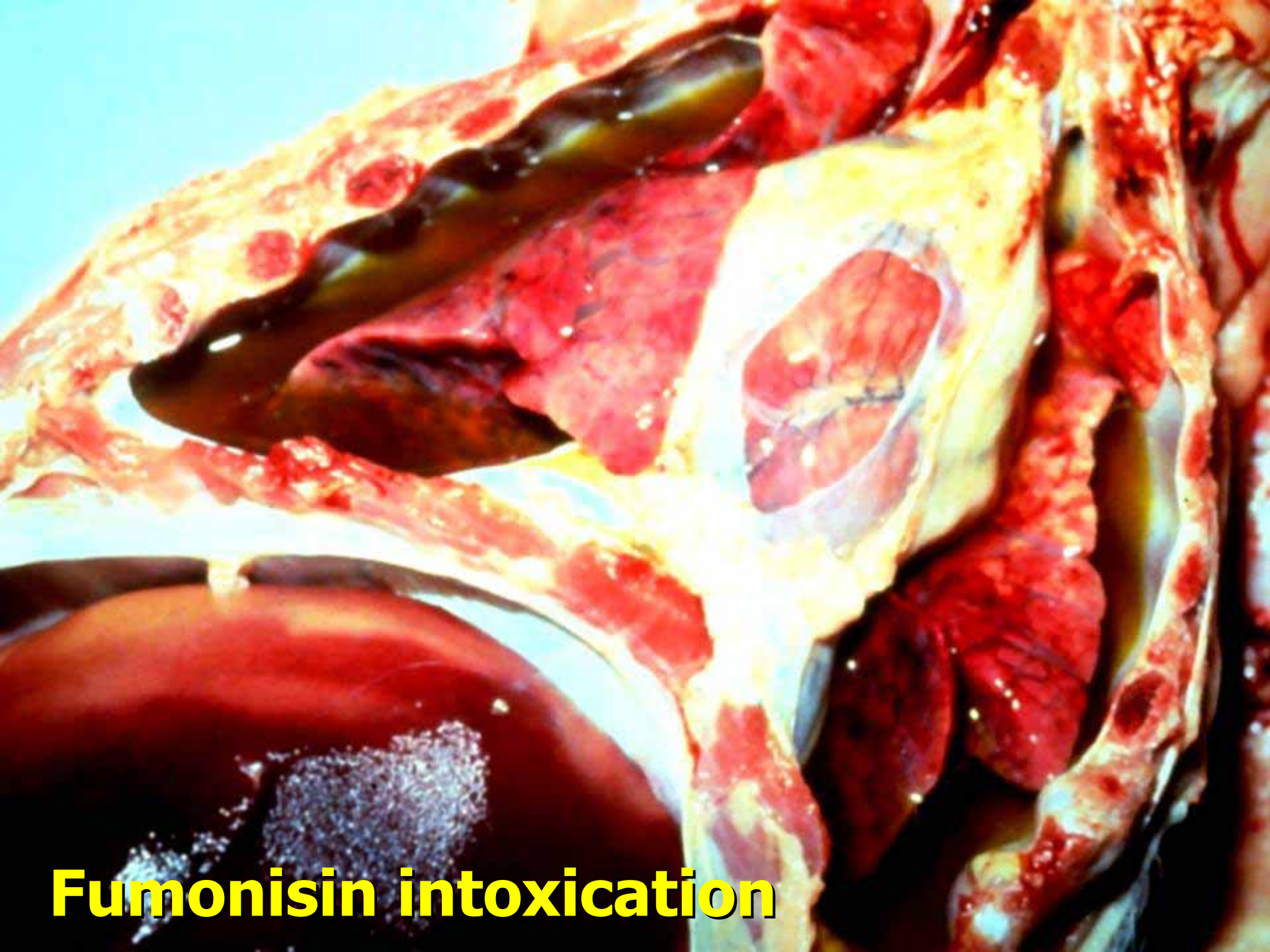

www.offthemark.com

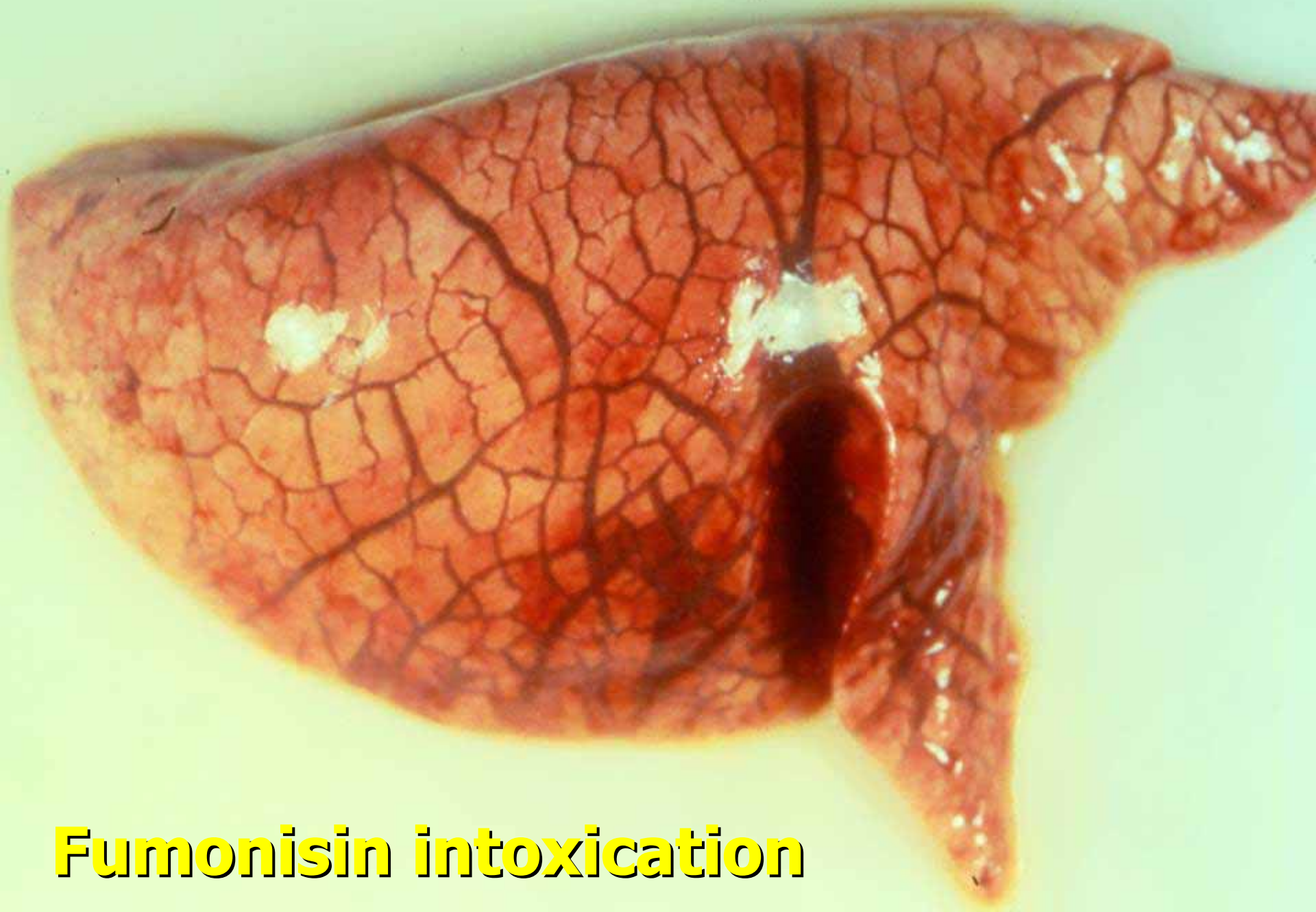WINNIE THE POOH, ABOUT TO INVENT
THE FIRST HONEY-ROASTED HAM



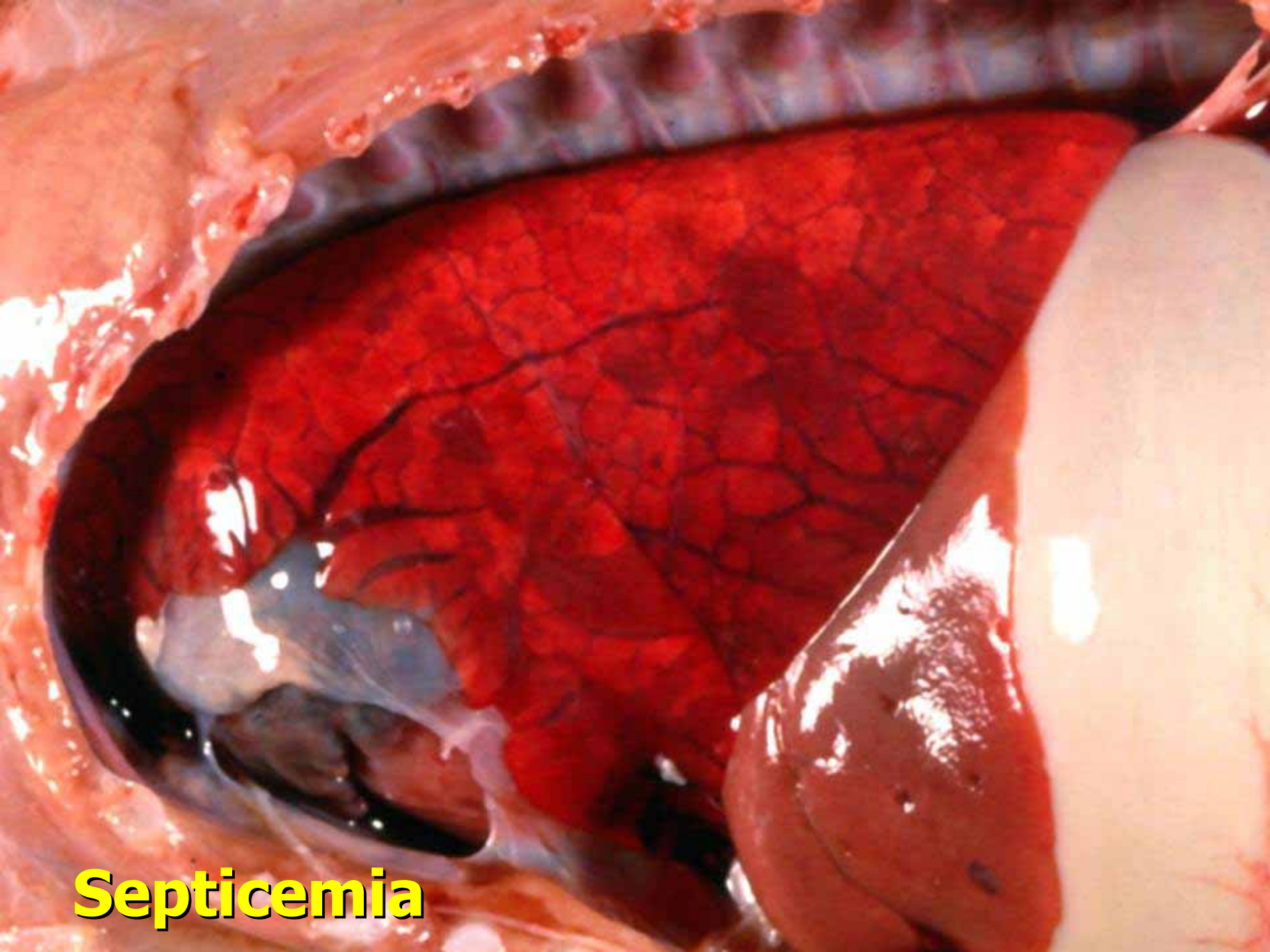
S. suis



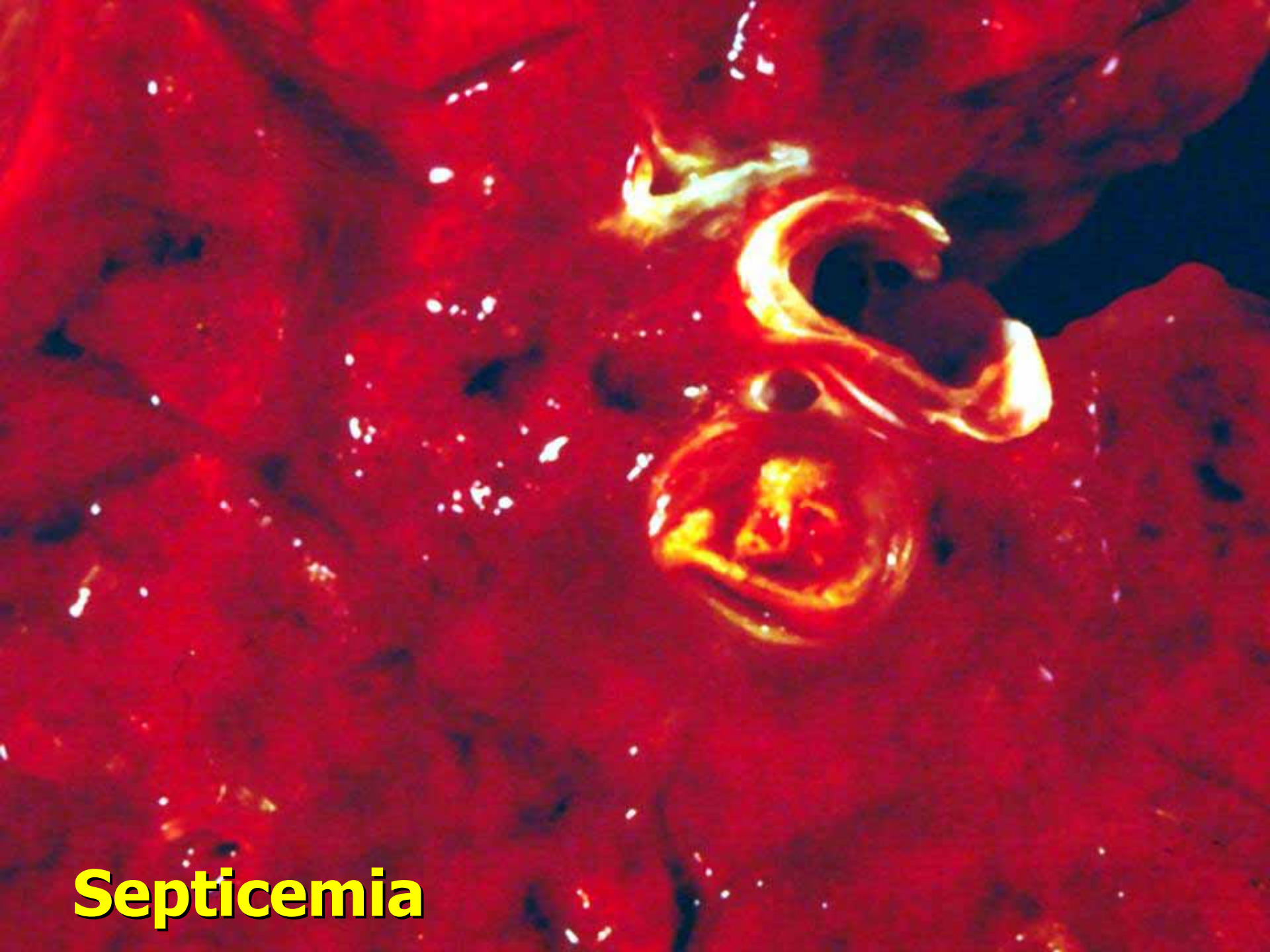Fumonisin intoxication



Fumonisin intoxication



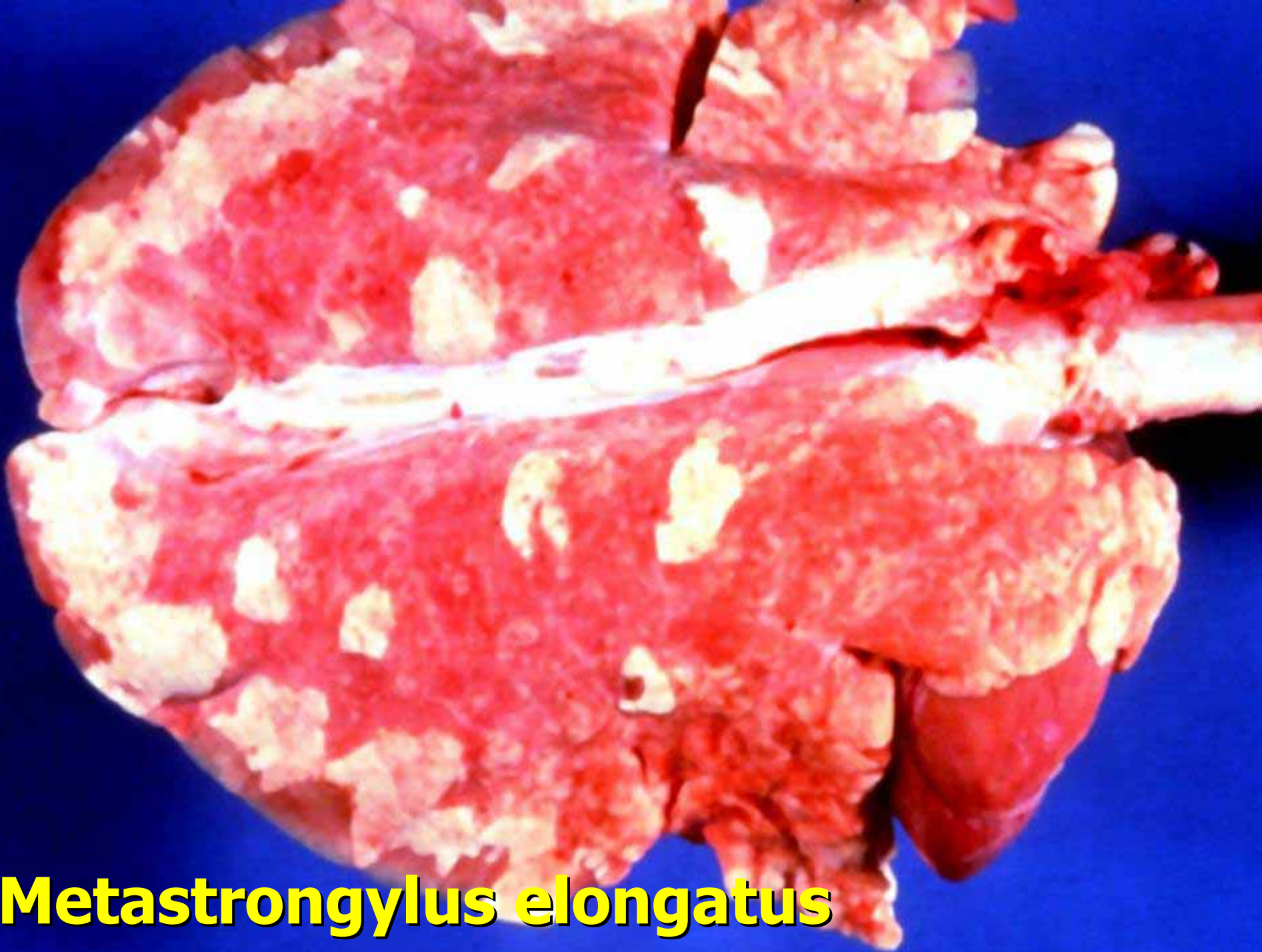Septicemia



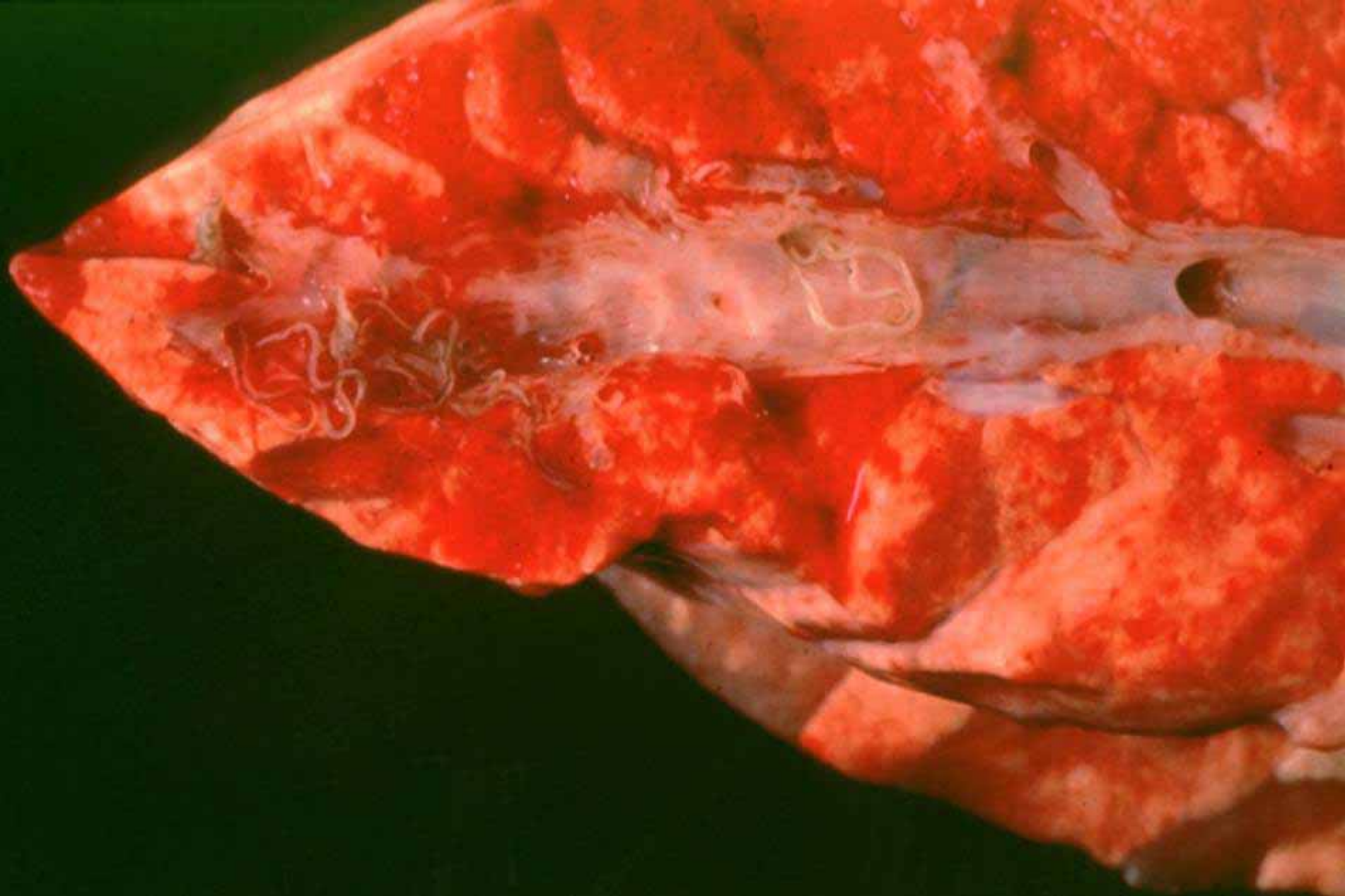
Septicemia

COMMON CAUSES AND GROSS TYPES OF PNEUMONIA IN SWINE

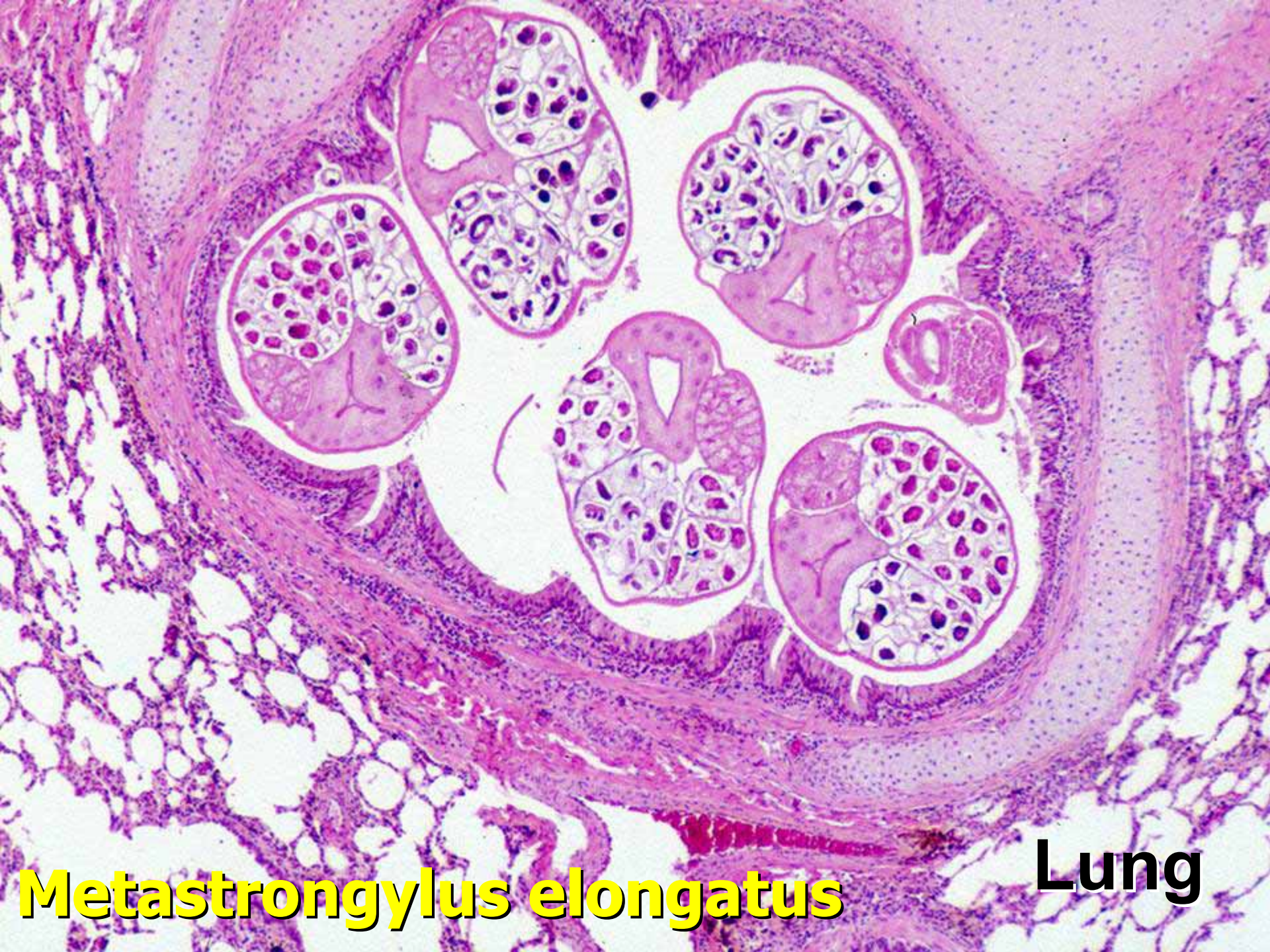| Cause | Type of Pneumonia | Ages Commonly Affected | Is Coughing Typical? |
|---|-------------------------------------|------------------------|----------------------|
| <i>Aujeszky's virus</i> | Interstitial pneumonia | Any age | Sometimes |
| Swine Influenza virus | Interstitial pneumonia | Any age | Yes (loud, harsh) |
| PRRS virus | Interstitial pneumonia | Any age | No |
| Ascarid larval migration | Interstitial pneumonia | After weaning | No |
| <i>S. choleraesuis</i> septicemia | Interstitial pneumonia | 1 – 5 months | No |
| <i>Mycoplasma hyopneumoniae</i> | Bronchopneumonia | 1 ½ – 6 months | Yes (dry, soft) |
| <i>Actinobacillus pleuropneumoniae</i> | Pleuropneumonia | Any age | No |
| <i>Bordetella bronchiseptica</i> | Bronchopneumonia | 1-5 weeks | Yes |
| <i>Pasteurella multocida</i> Streptococcus suis Haemophilus parasuis Actinomyces pyogenes | Secondary purulent bronchopneumonia | Any age | Yes |



Metastrongylus elongatus

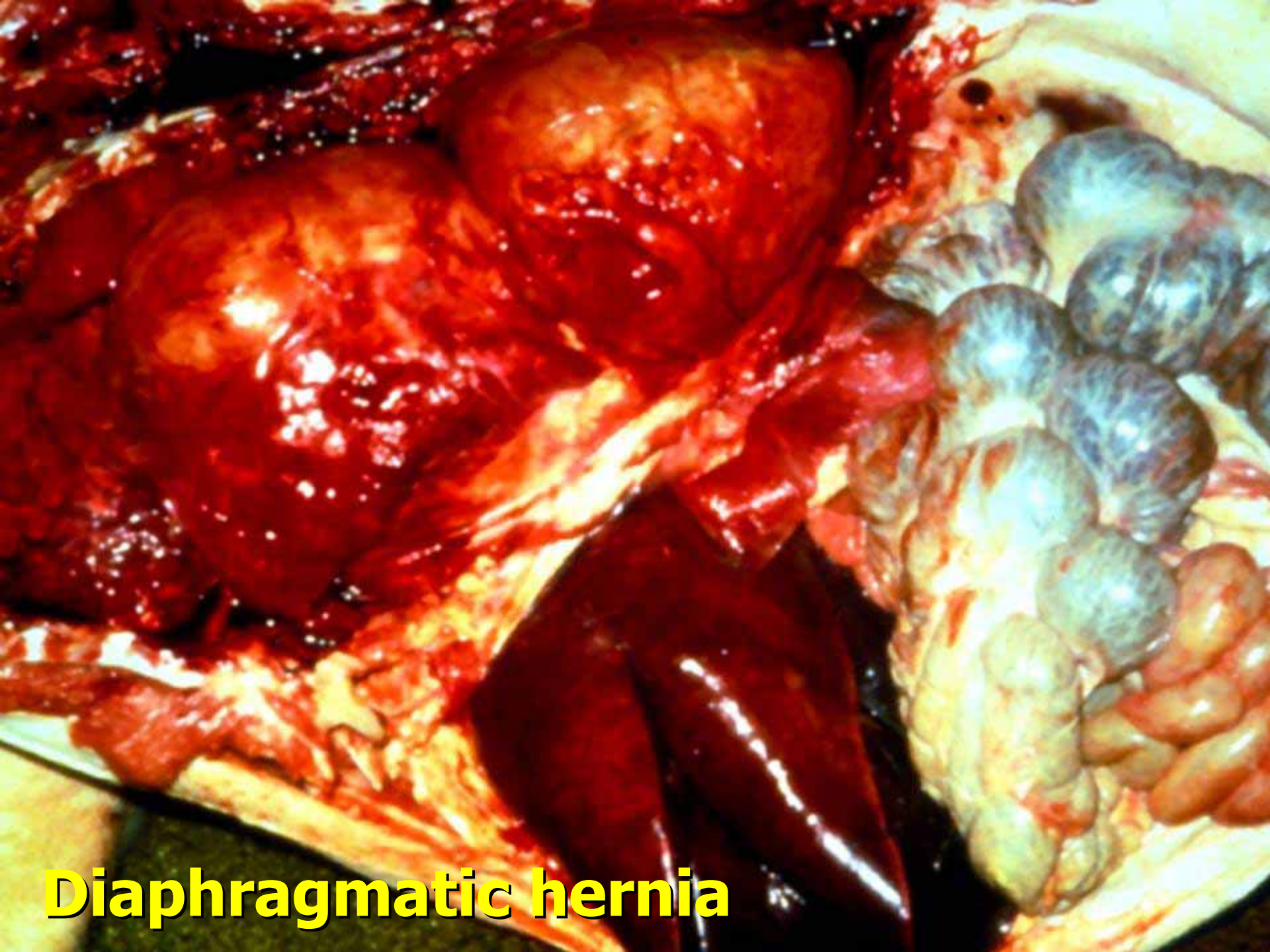


Metastrongylus elongatus

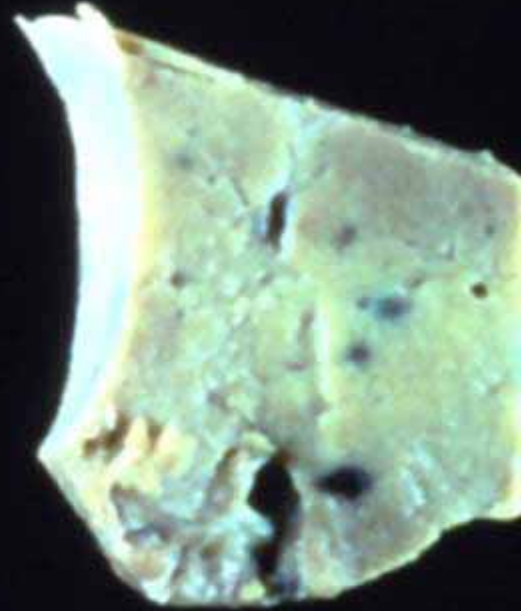
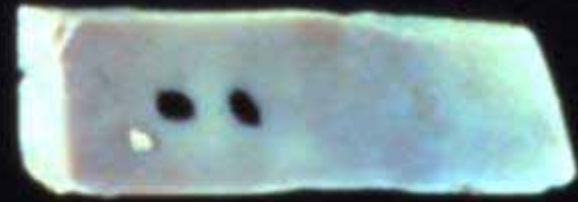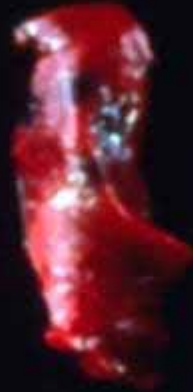

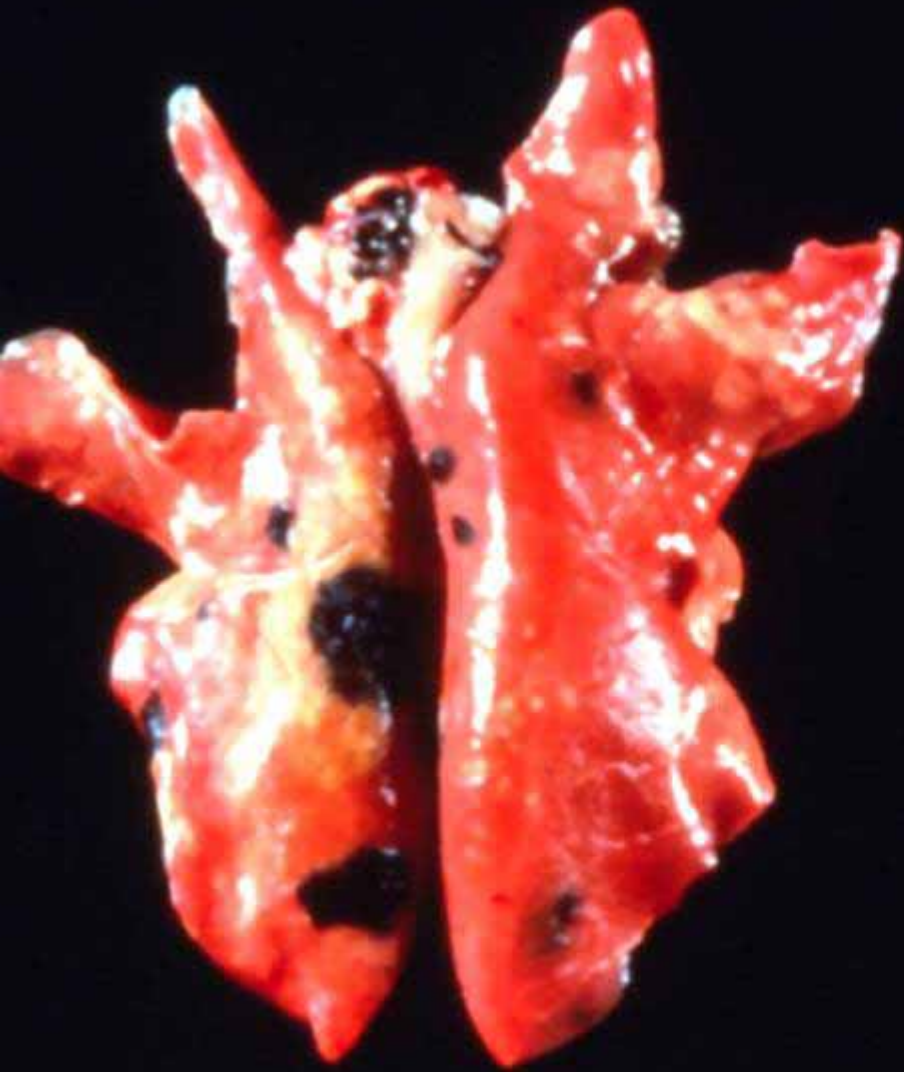
Metastrongylus elongatus

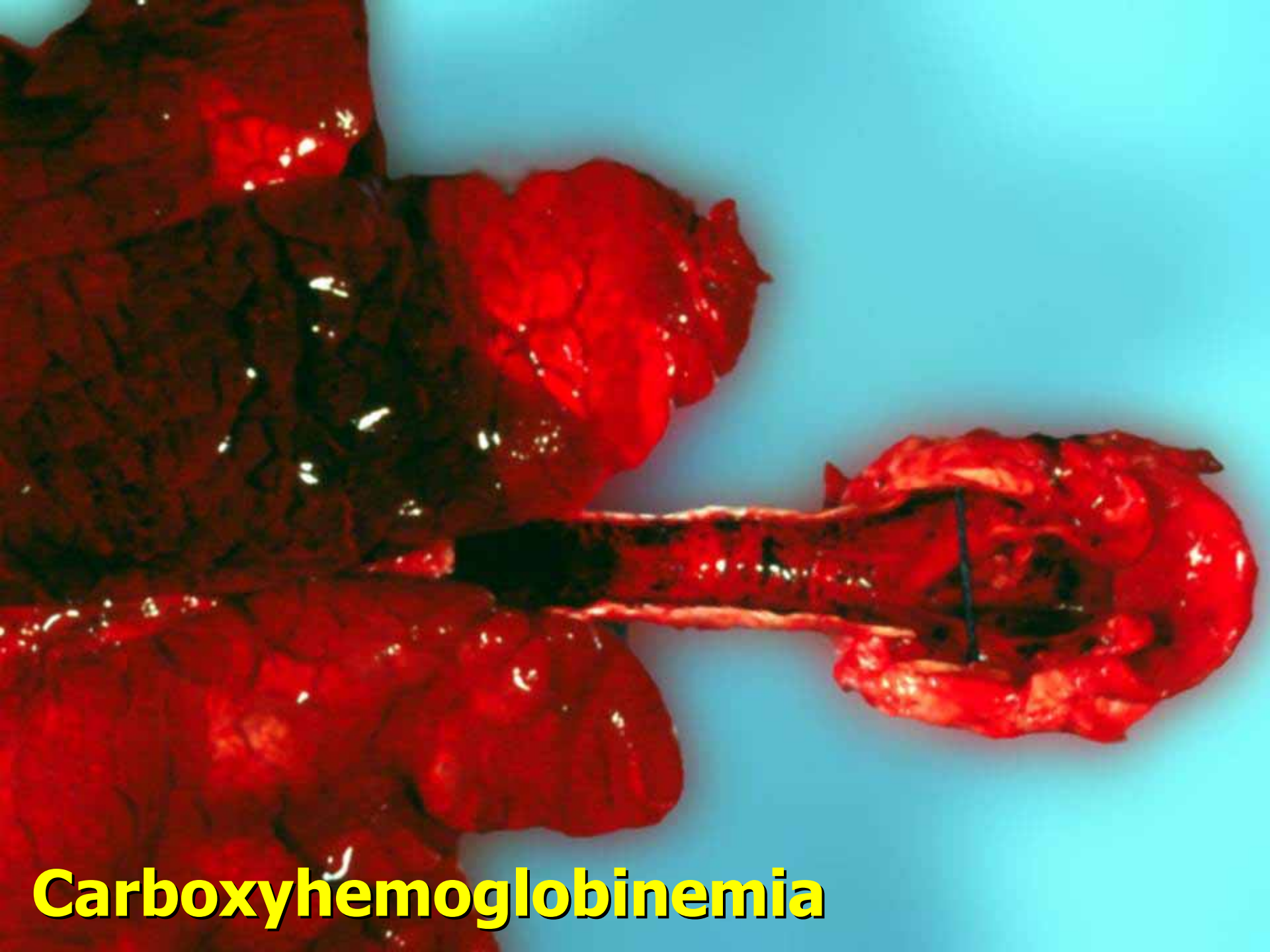
Lung



Diaphragmatic hernia



Melanosis

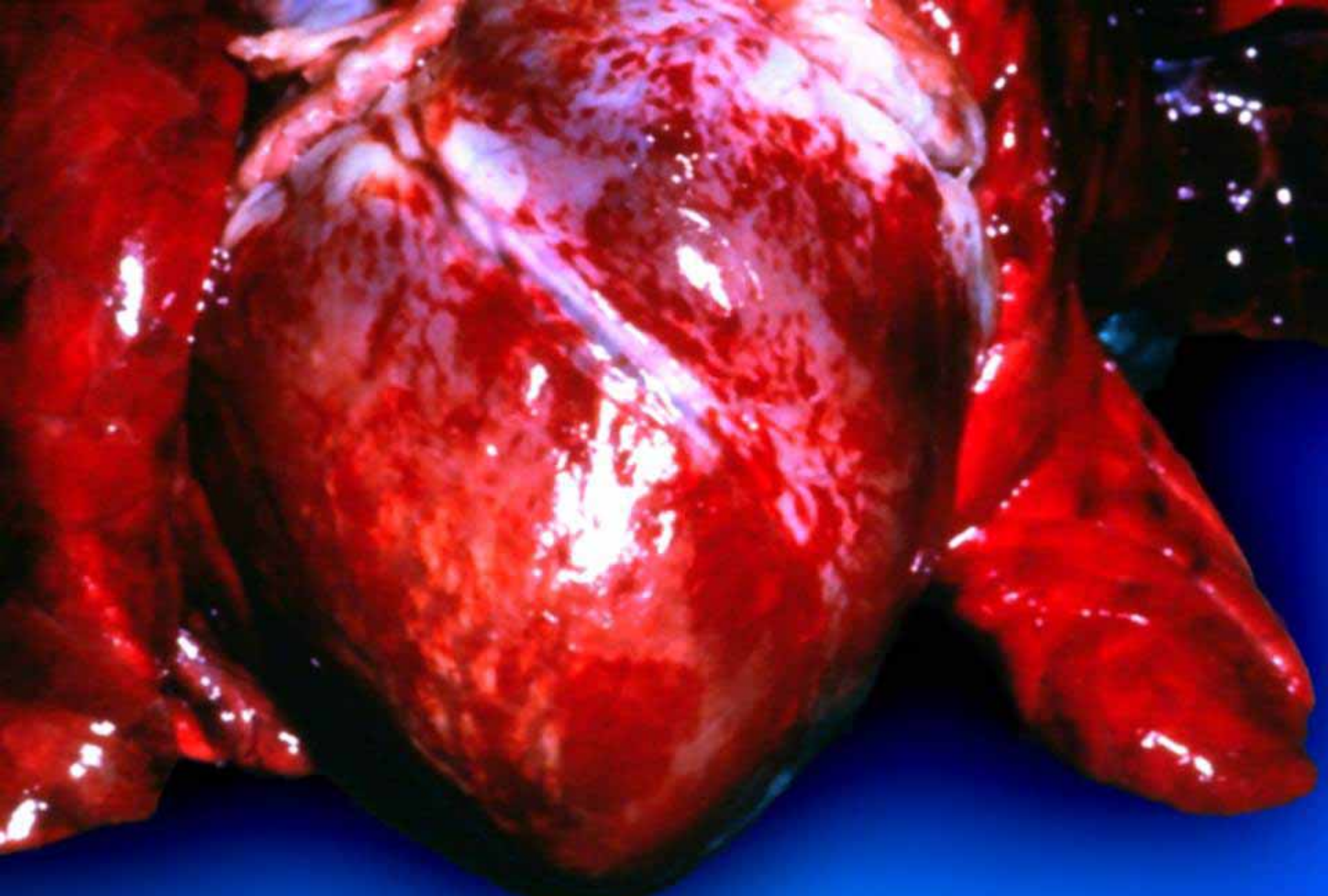


Carboxyhemoglobinemia

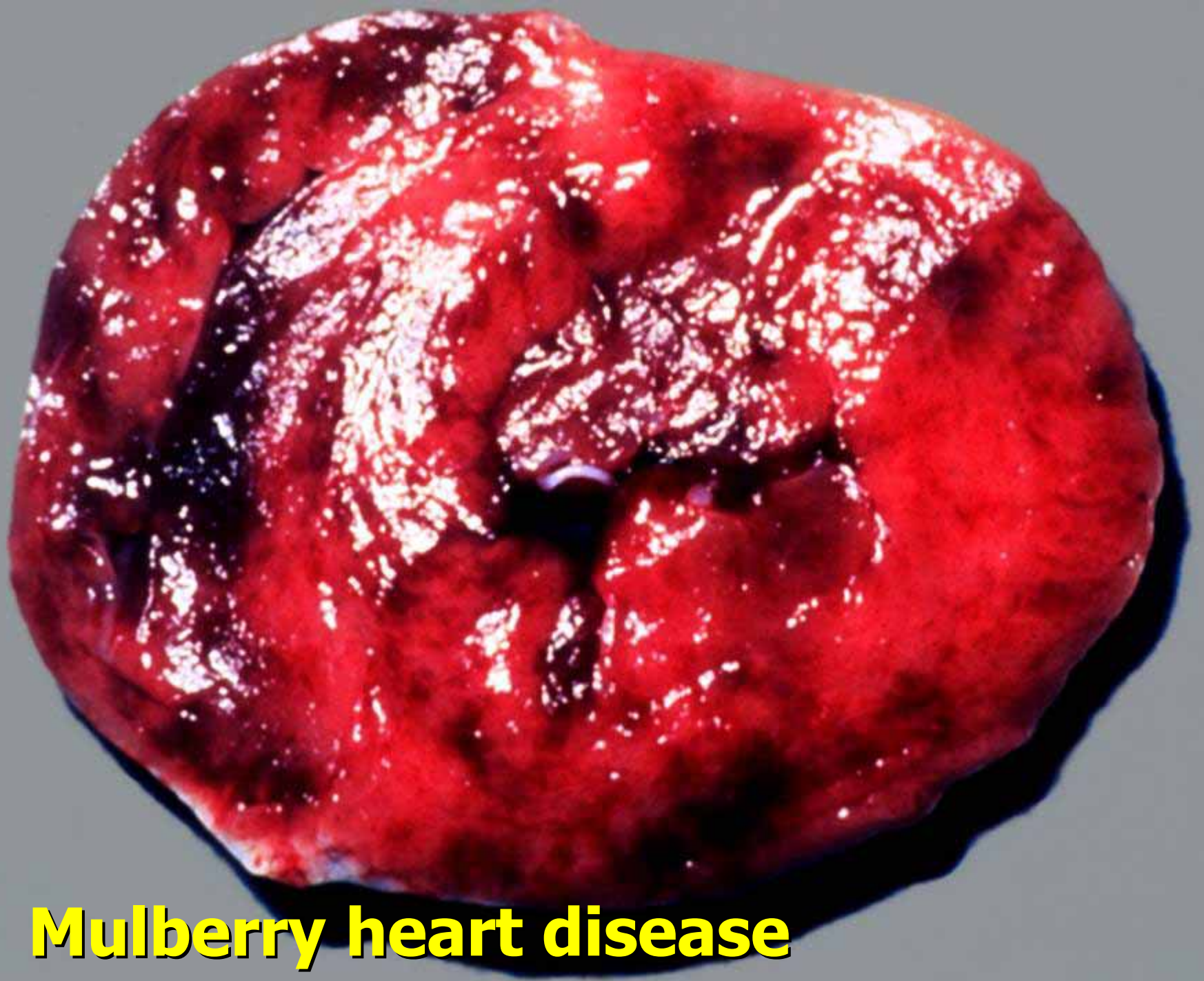



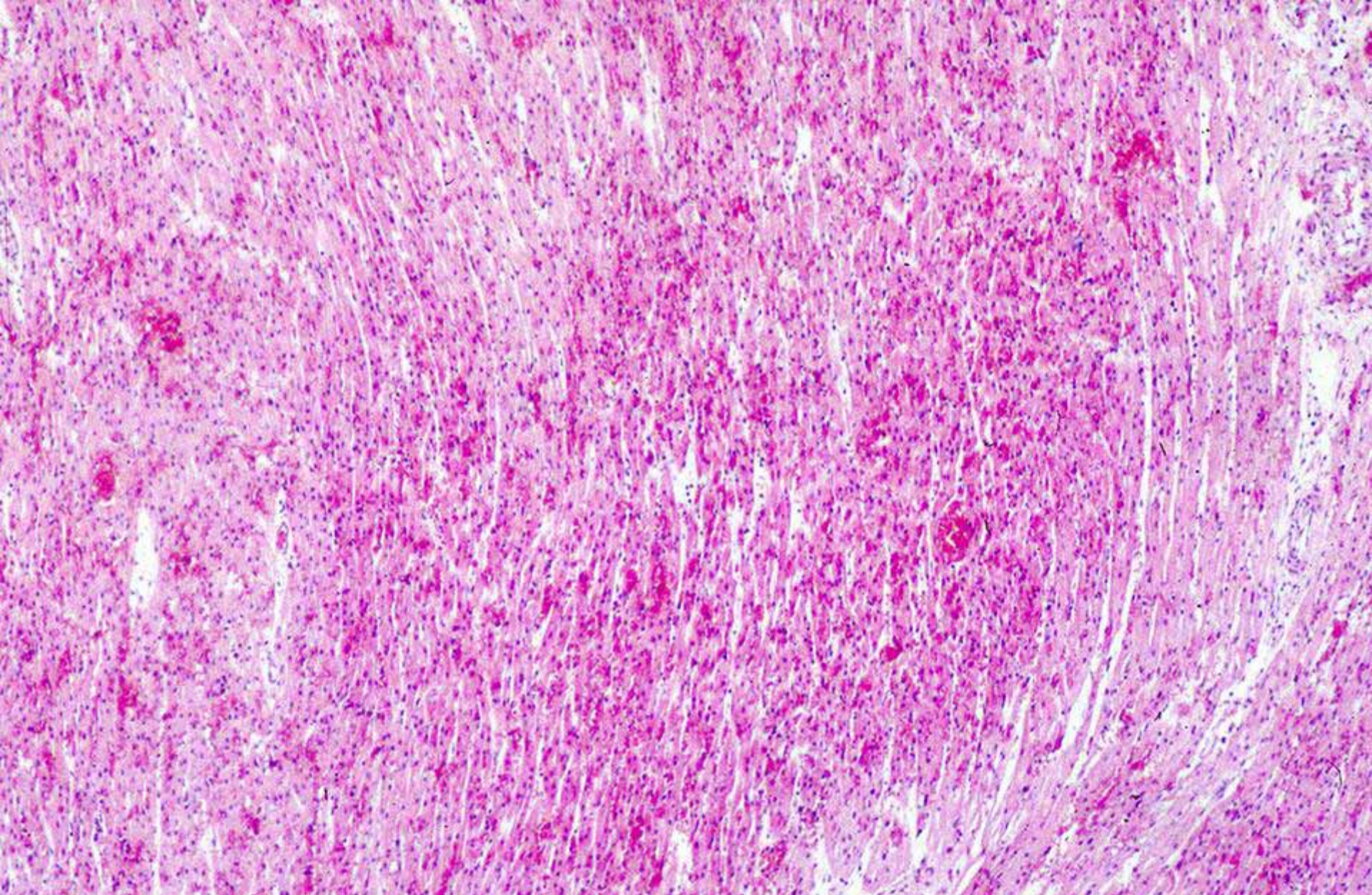
Cardiovascular System



Mulberry heart disease

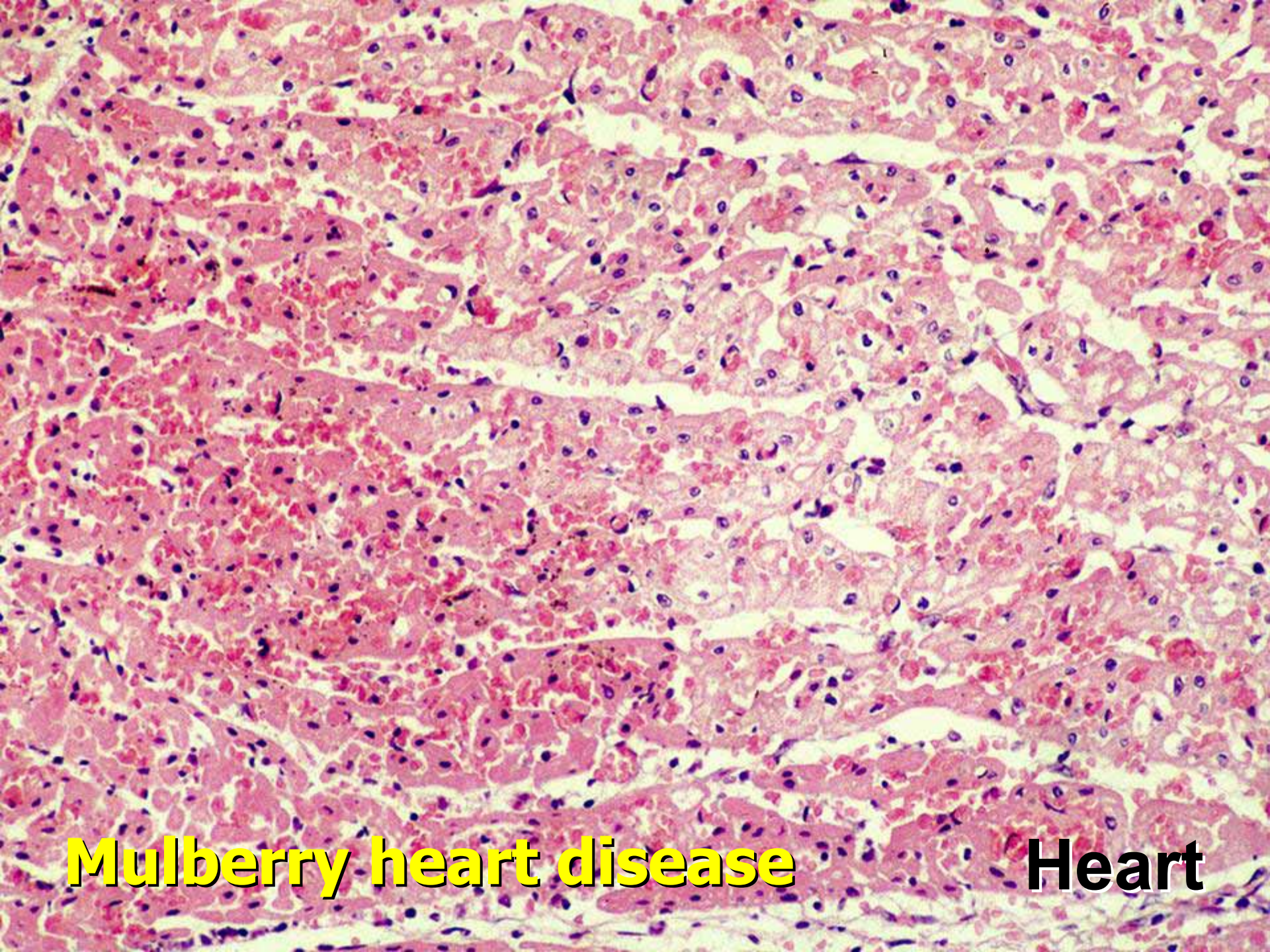


Mulberry heart disease



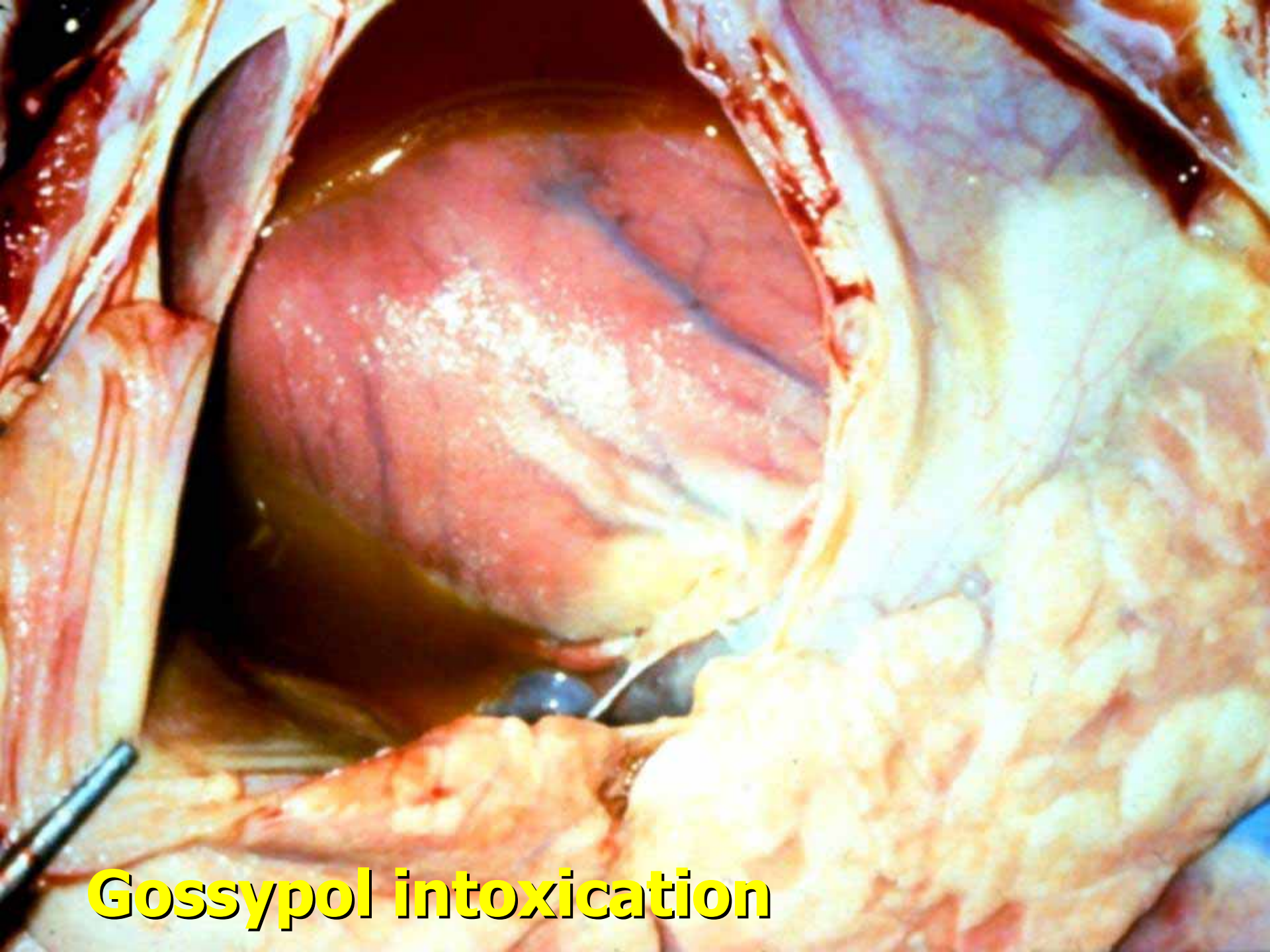
Mulberry heart disease

Heart

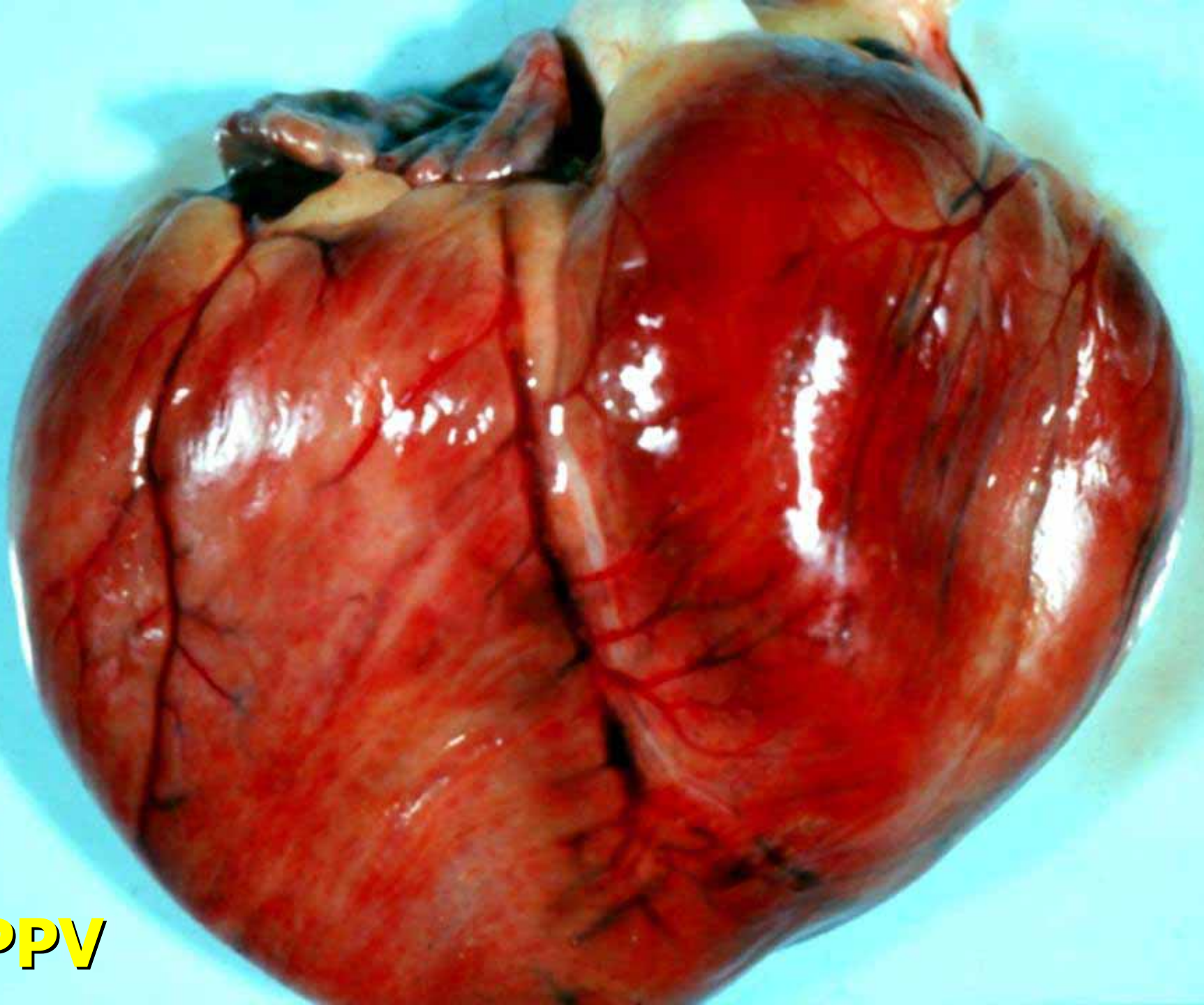


Mulberry heart disease

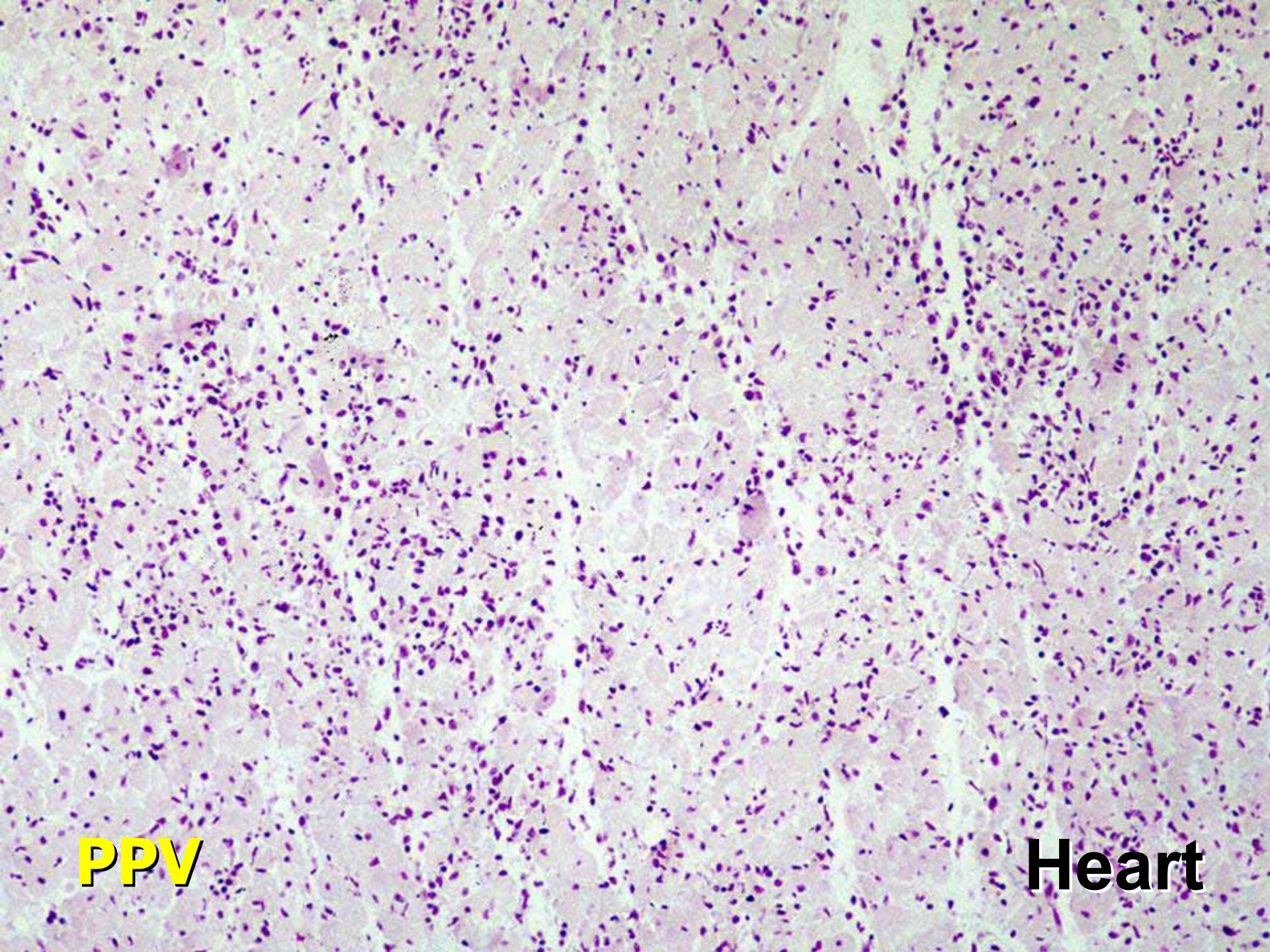
Heart



Gossypol intoxication

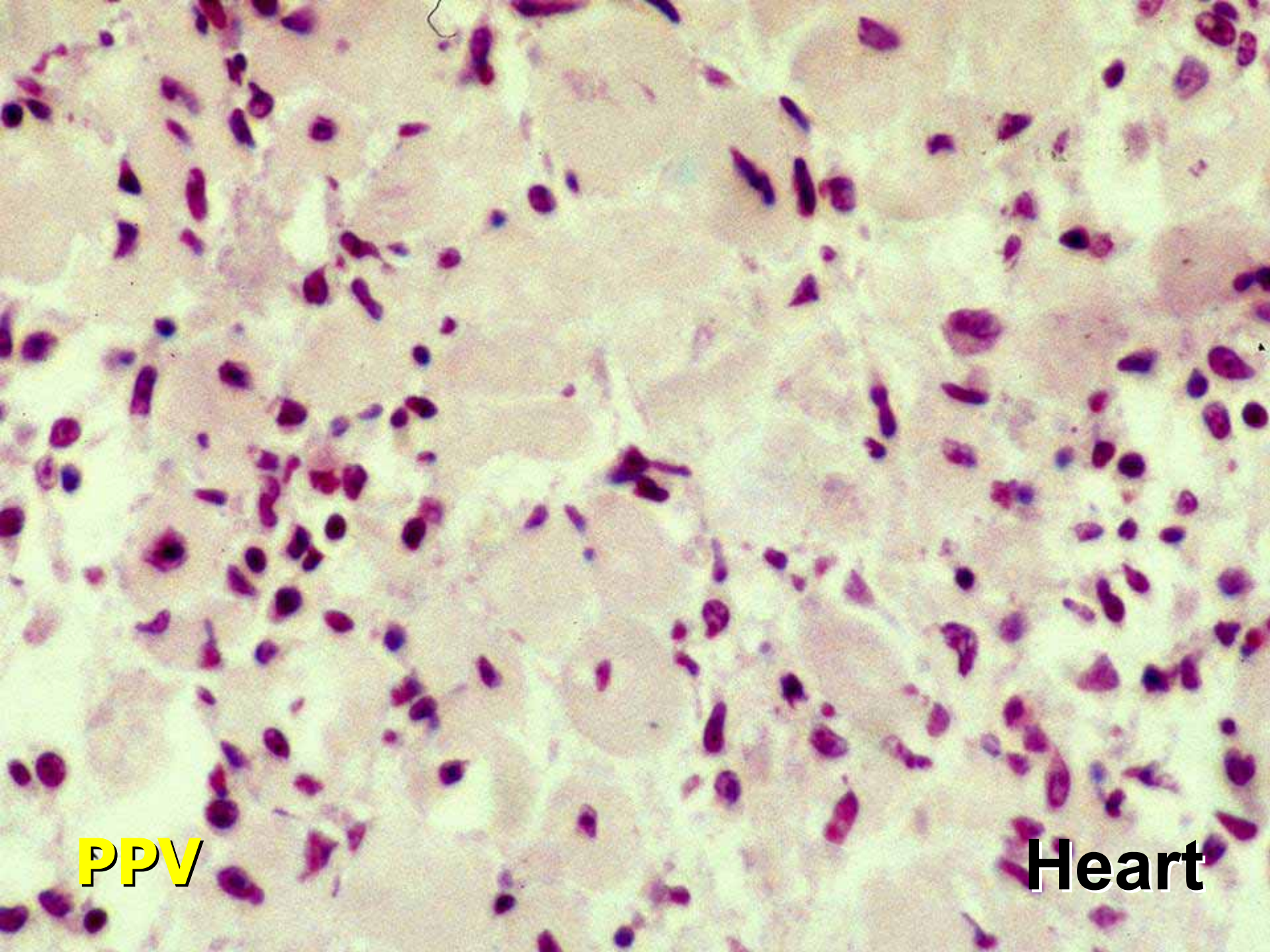


PPV



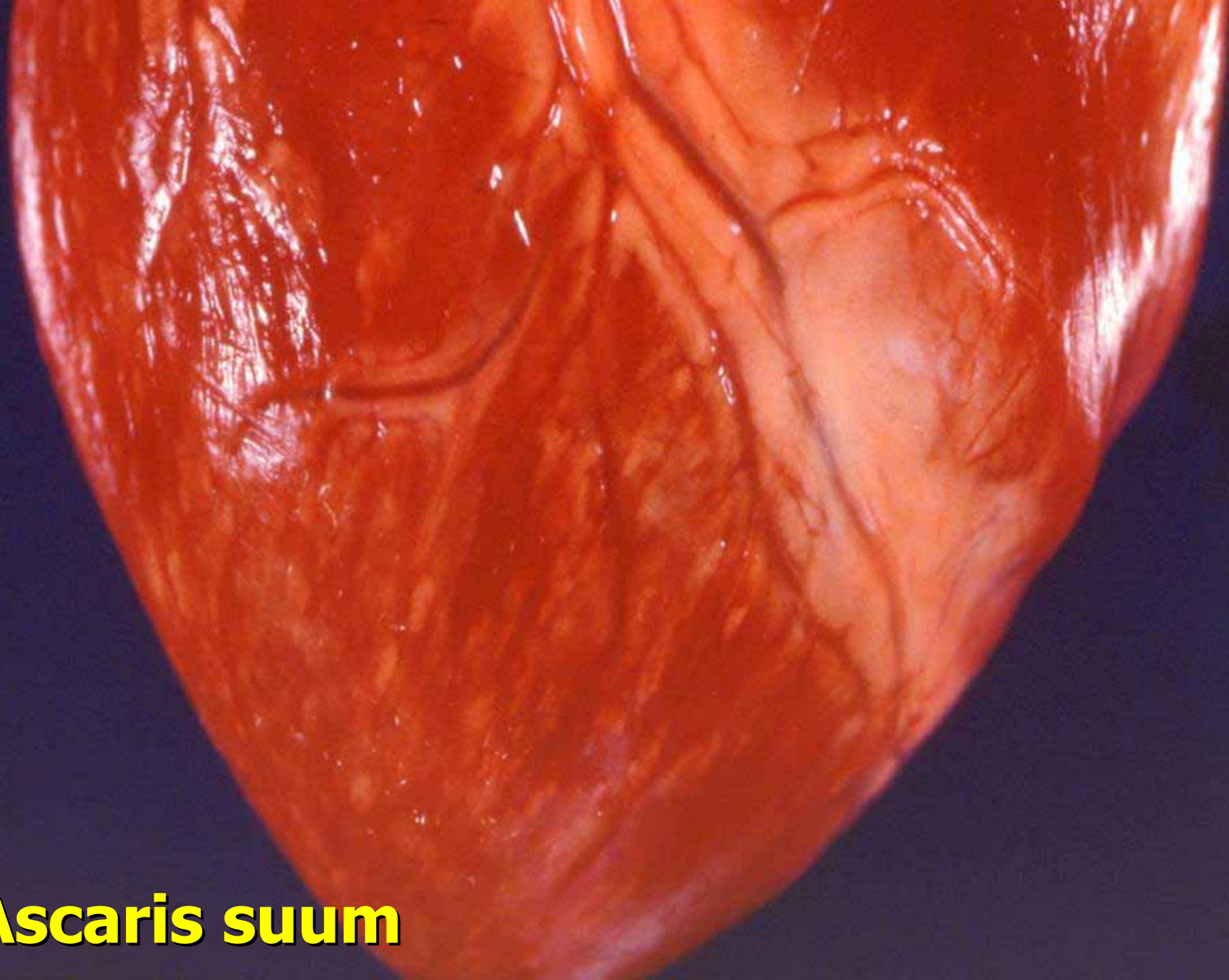
PPV

Heart

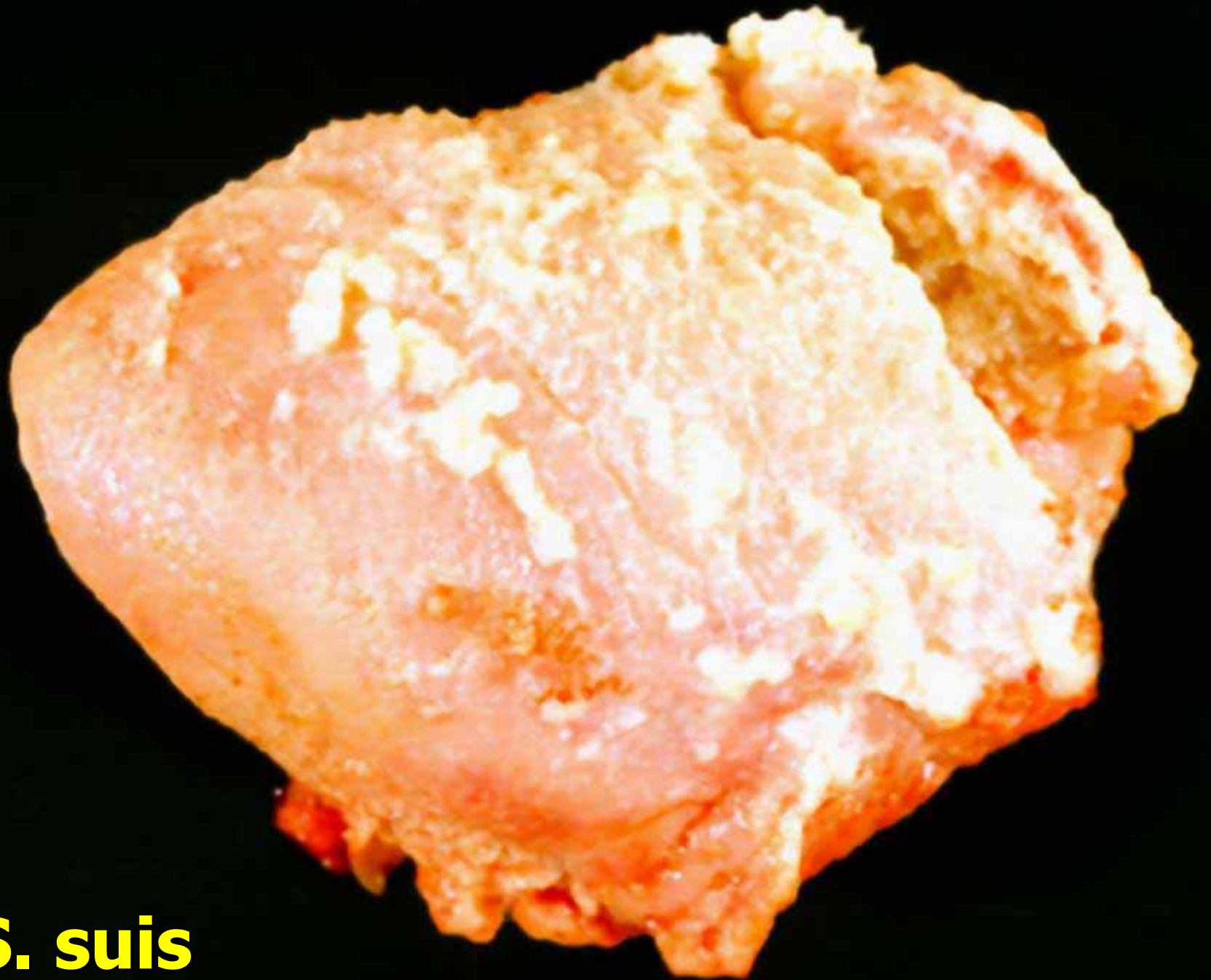

PPV

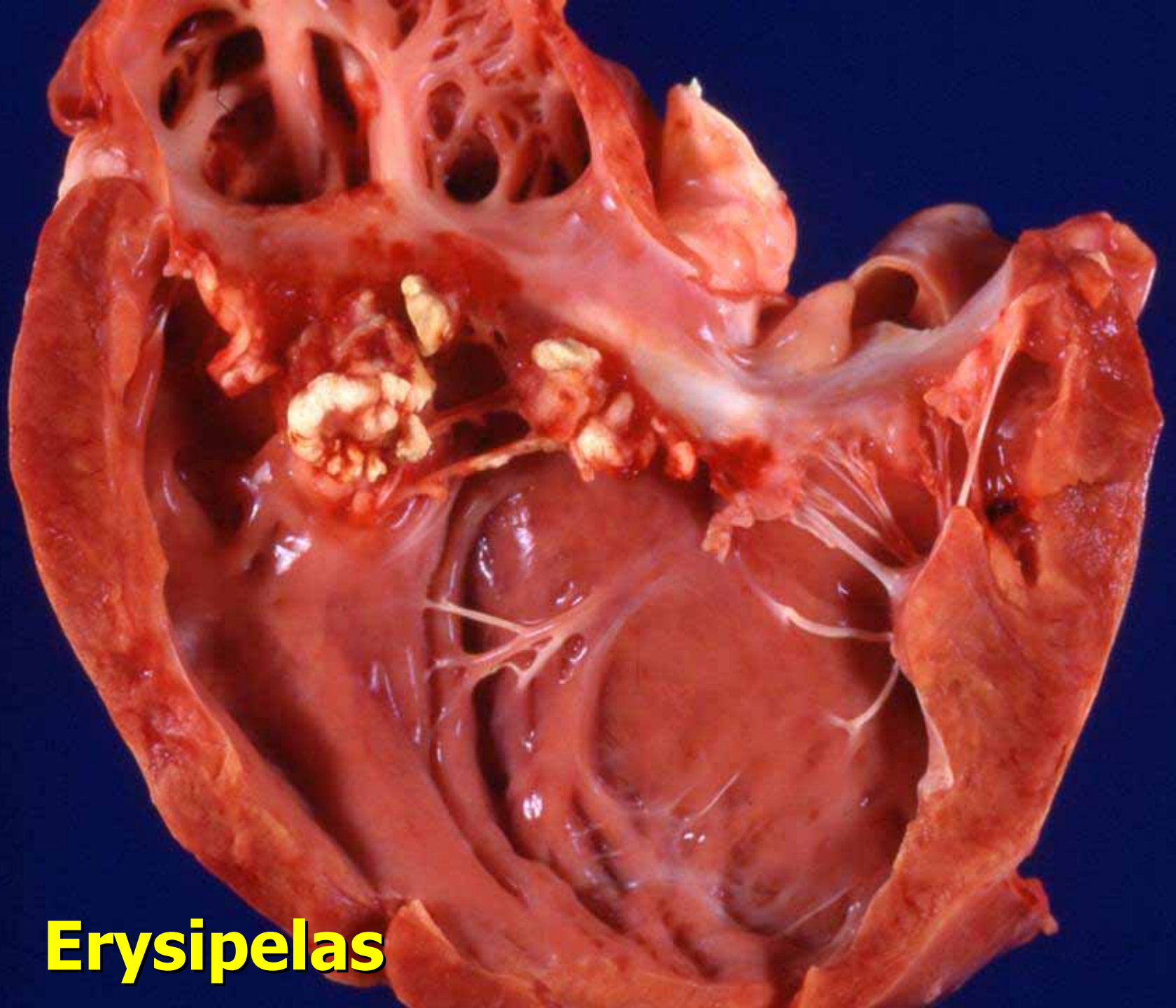
Heart



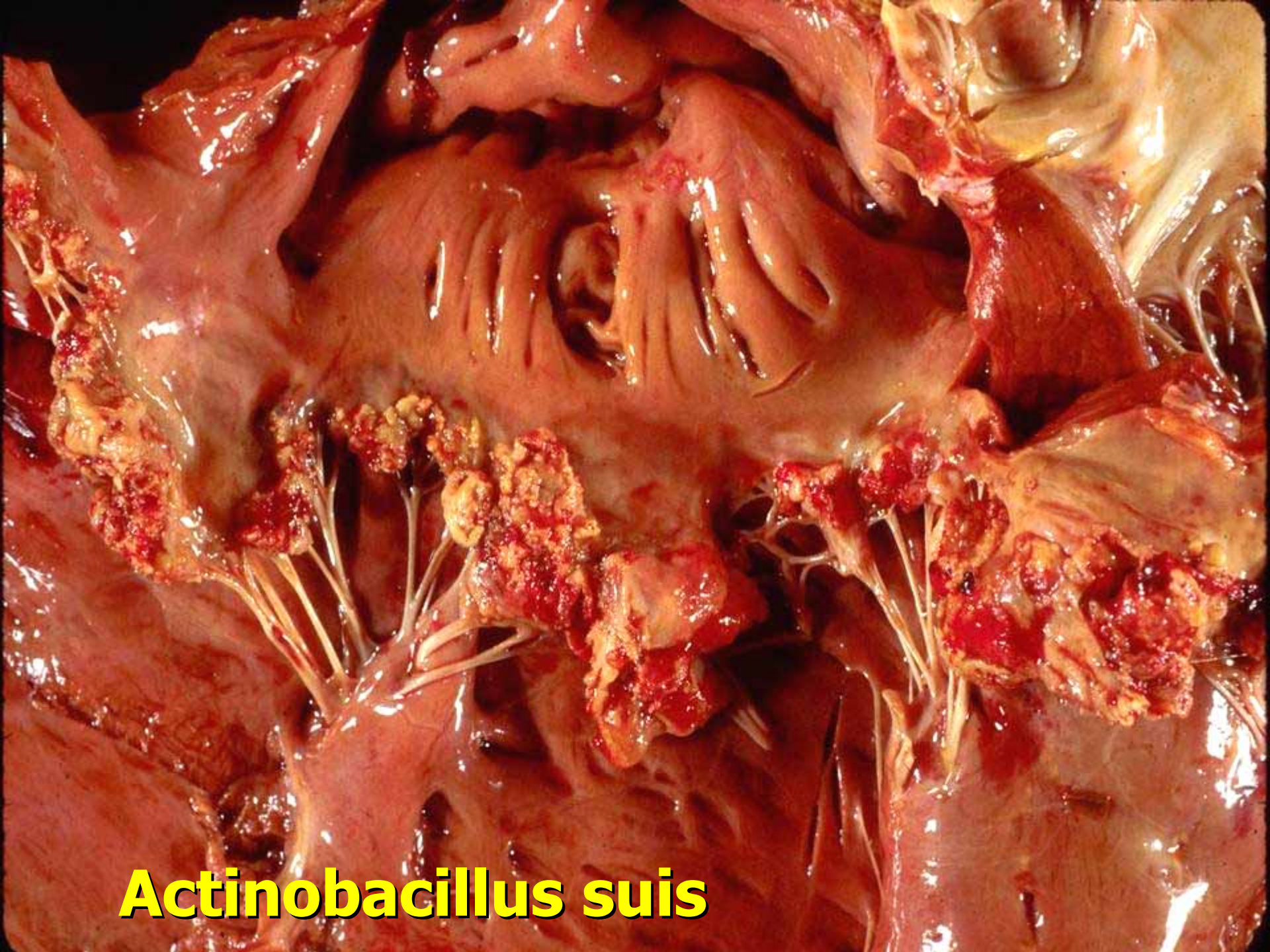
Ascaris suum



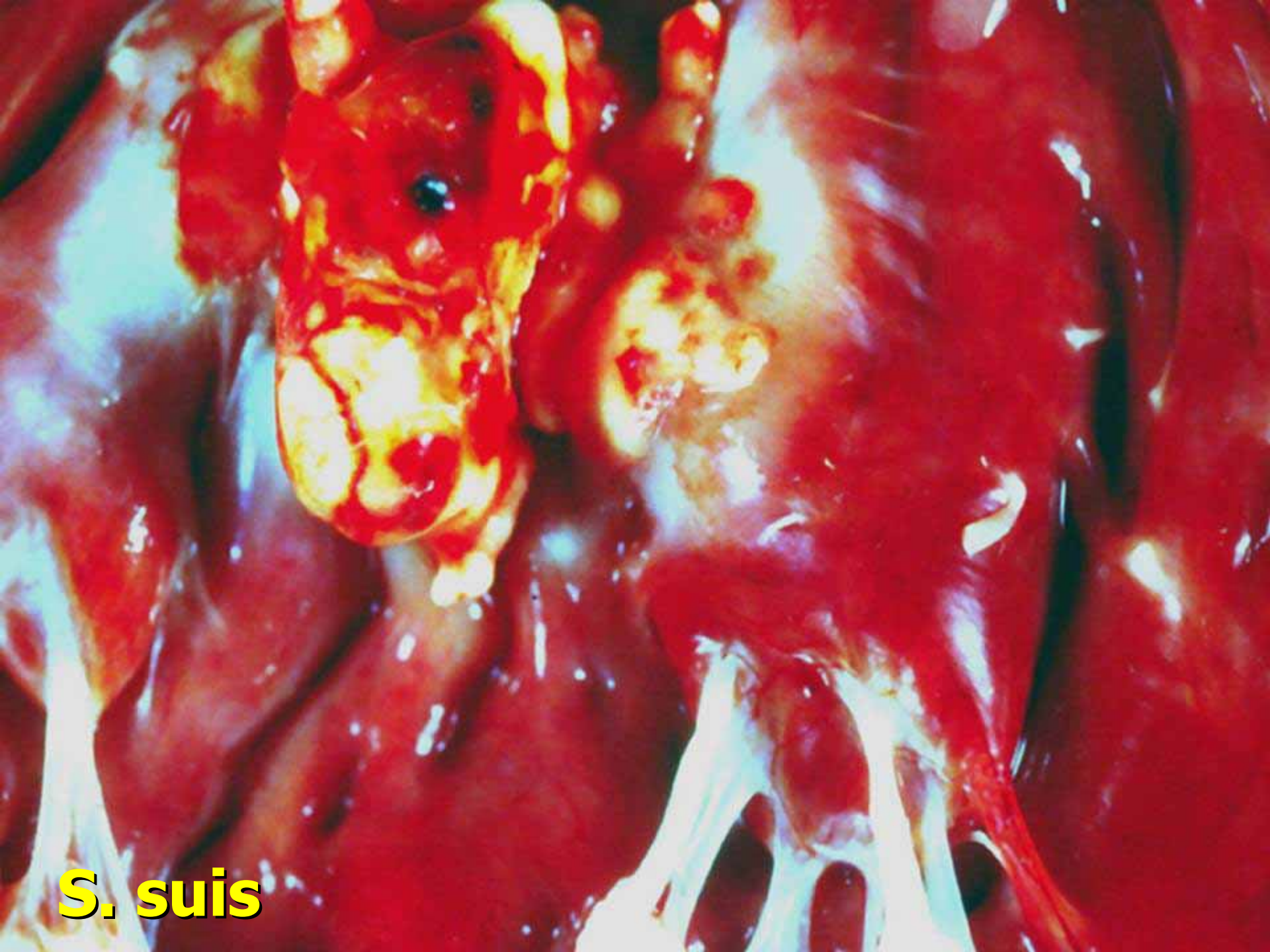
S. suis



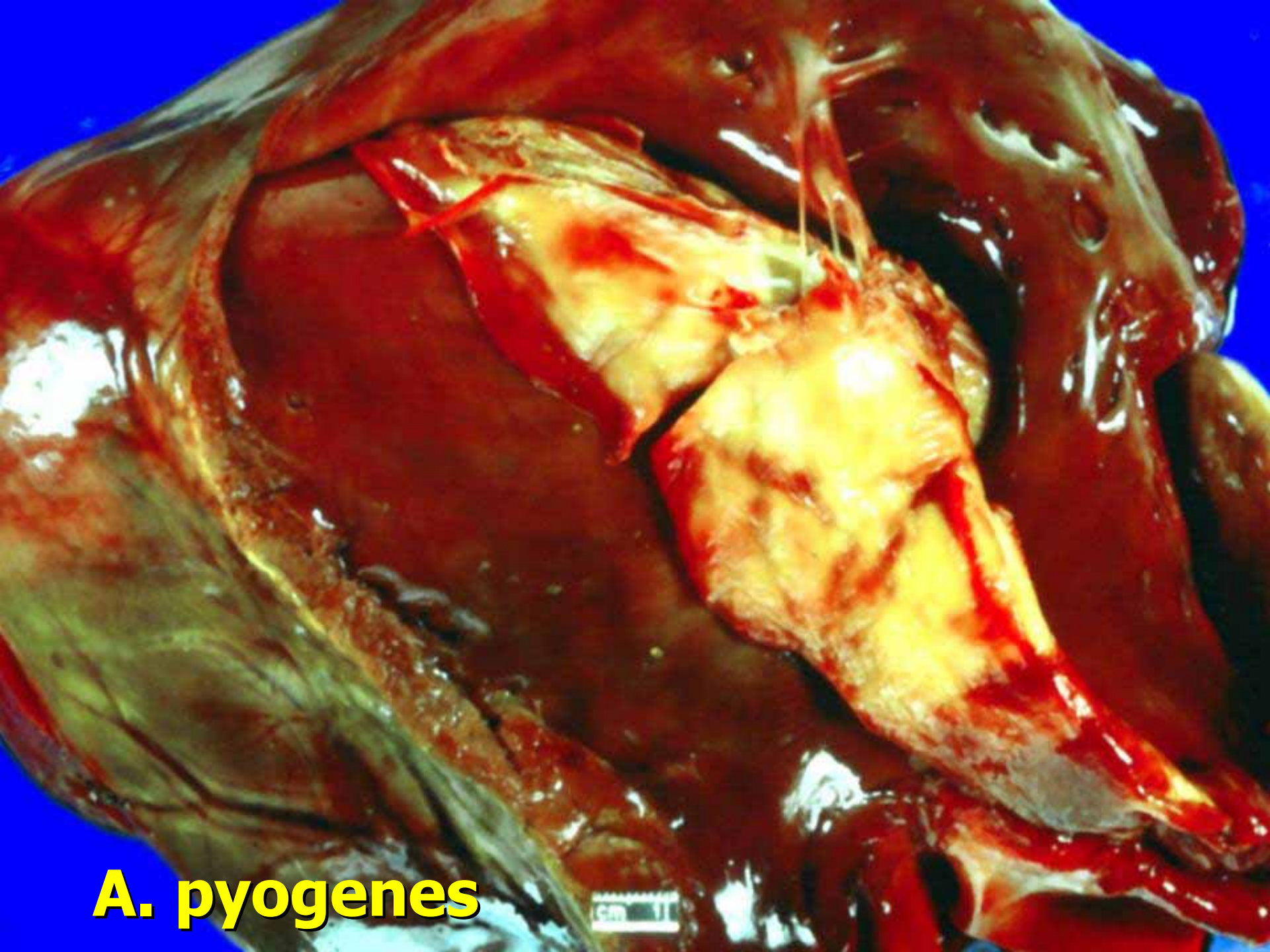
Erysipeloid



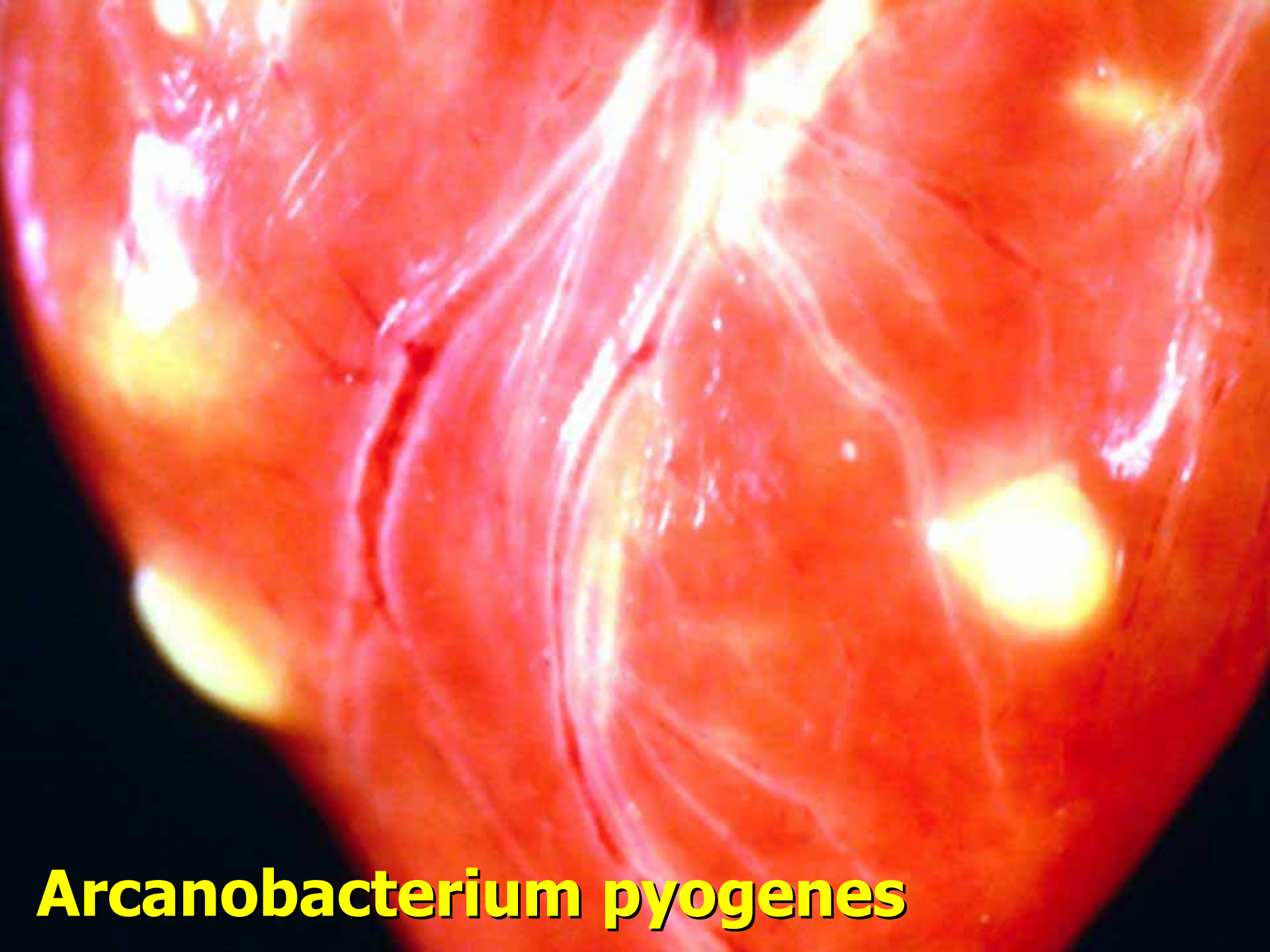
Actinobacillus suis



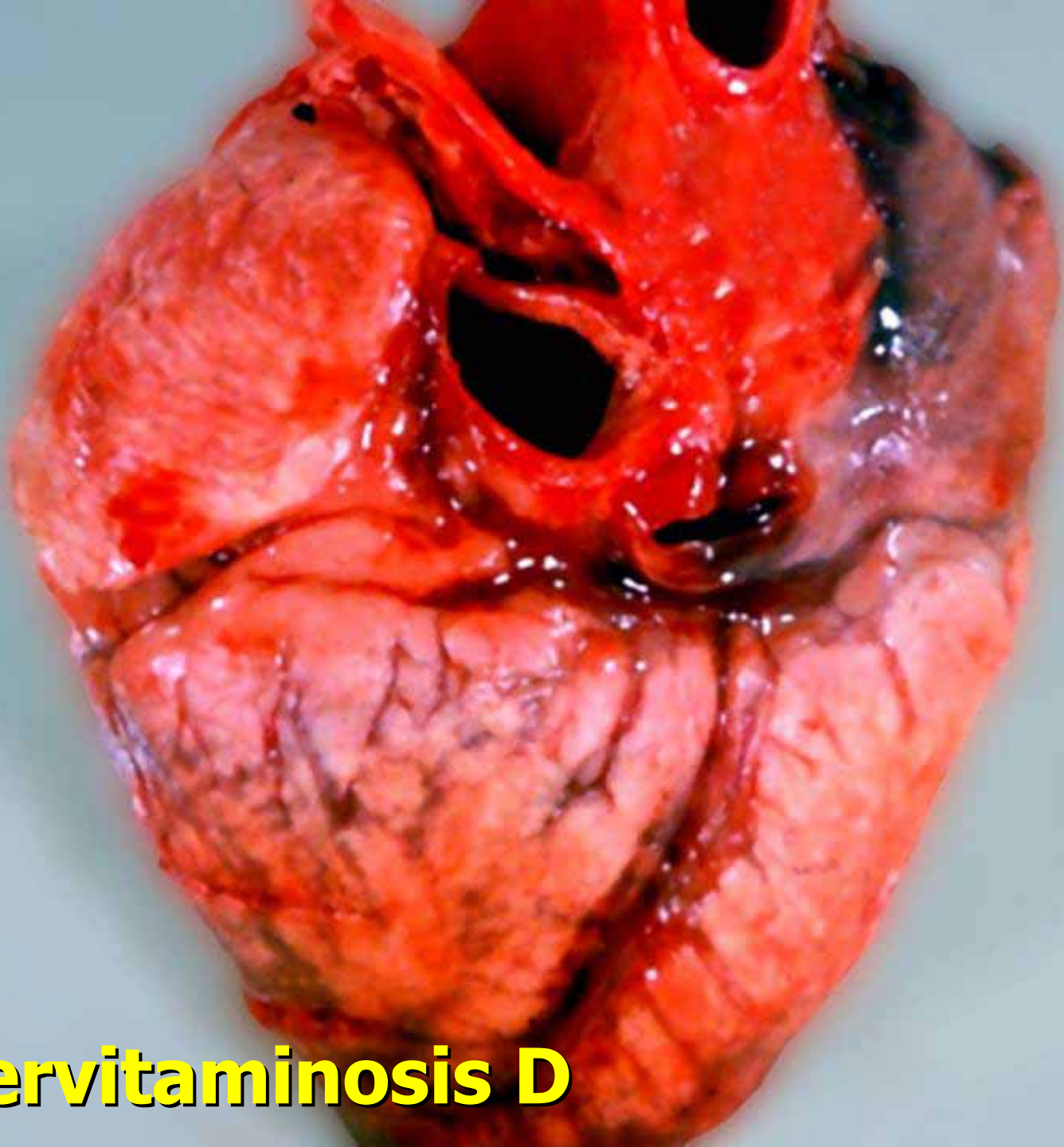
S. suis



A. pyogenes



Arcanobacterium pyogenes



Hypervitaminosis D