

# Pathology of Swine

**Dr. med. vet. Matti Kiupel, BS, MS, PhD,  
DACVP**

**Diagnostic Center for Population and Animal Health  
College of Veterinary Medicine, Michigan State University**

**4125 Beaumont Road 152A, Lansing, MI 48910, USA**

**Tel.: \*\* 517 432 2670; Fax: \*\* 517 432 6557;**

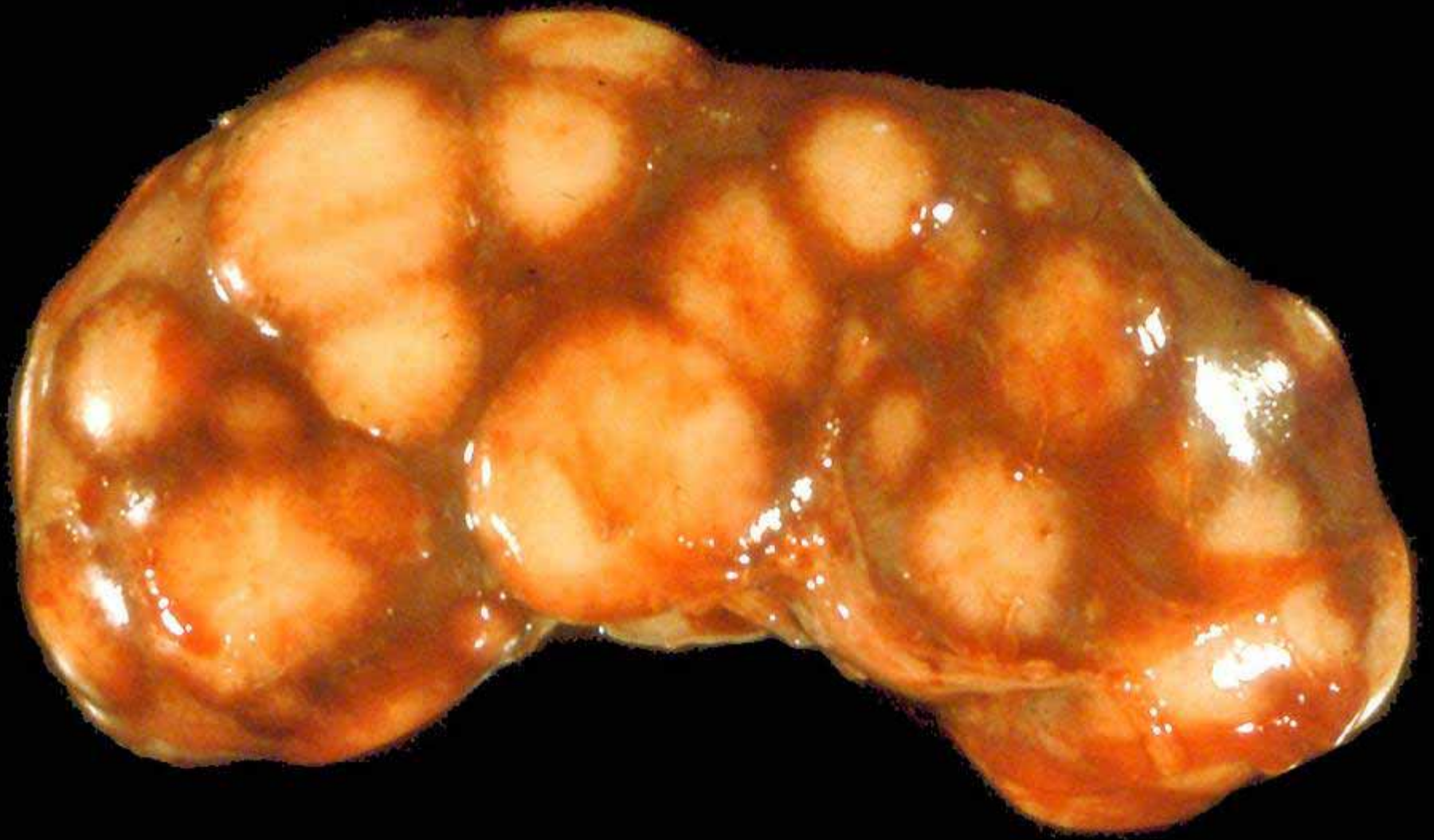**E-mail: [kiupel@dcpah.msu.edu](mailto:kiupel@dcpah.msu.edu)**



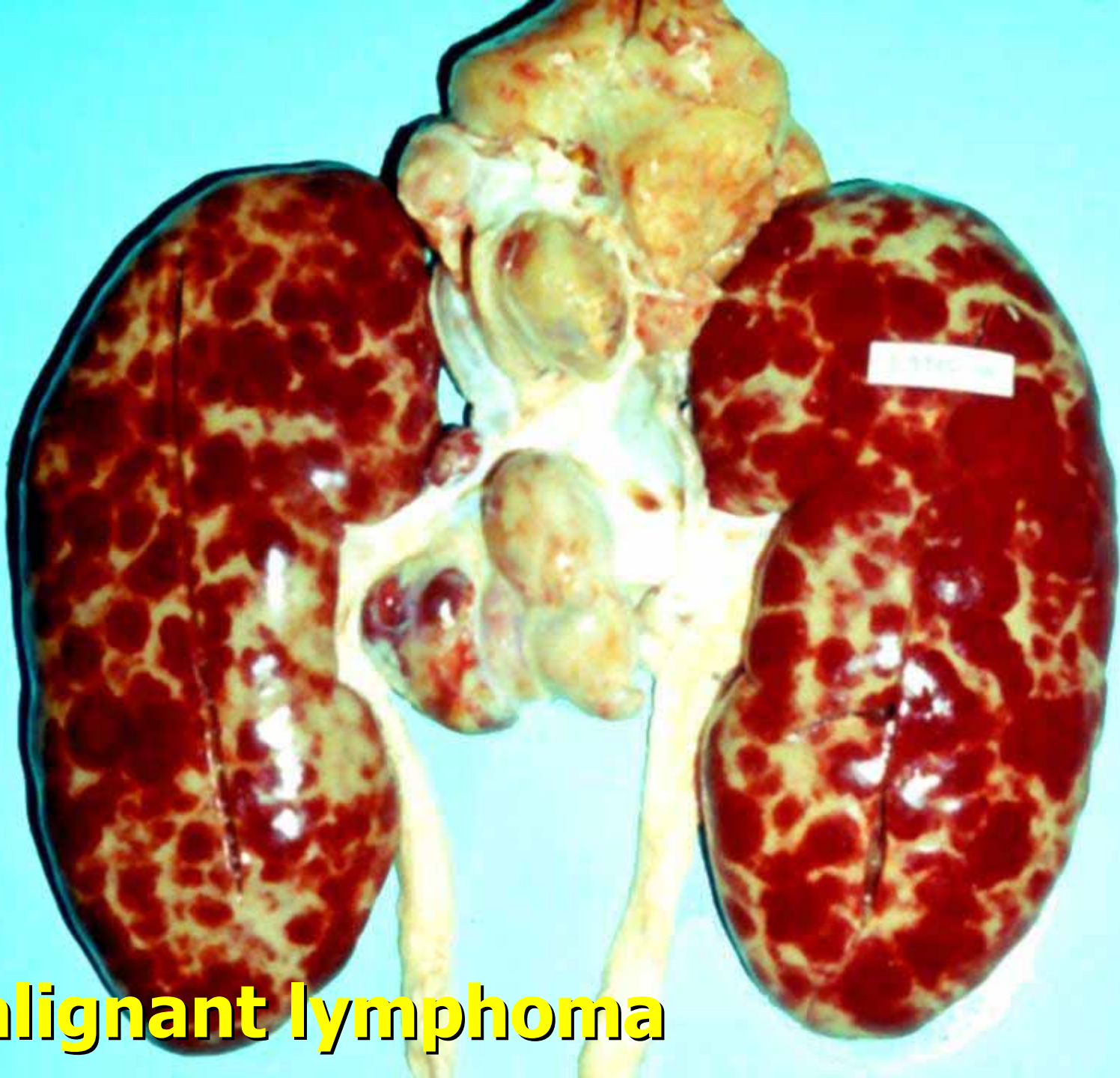
A blue-tinted photograph of a large, textured rock formation, possibly a fossil or mineral specimen. The rock surface is highly irregular and porous, with various shades of blue and white. The word "Neoplastic" is overlaid in the center in a bold, yellow, serif font with a black outline.

# Neoplastic



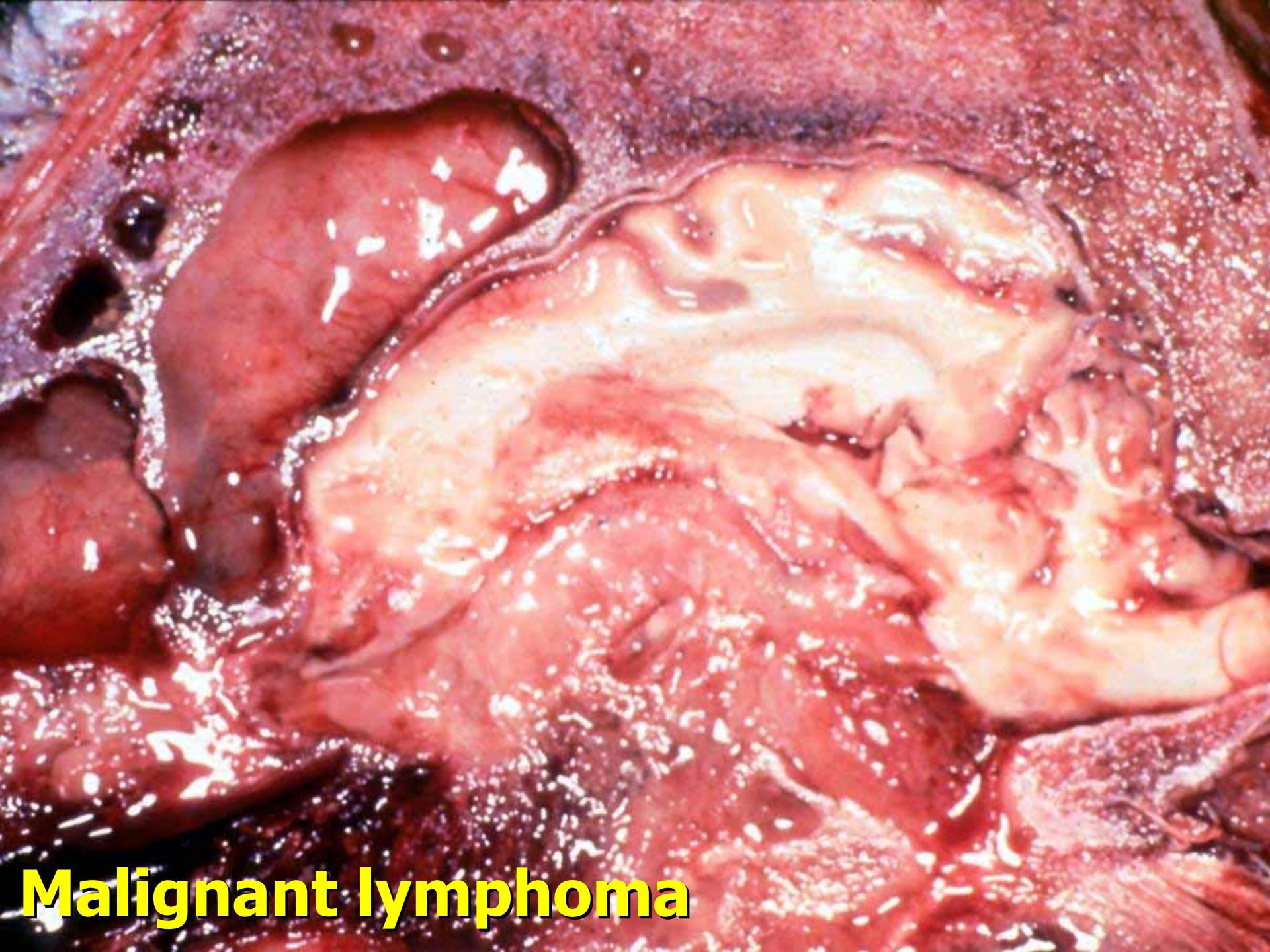

**Malignant lymphoma**



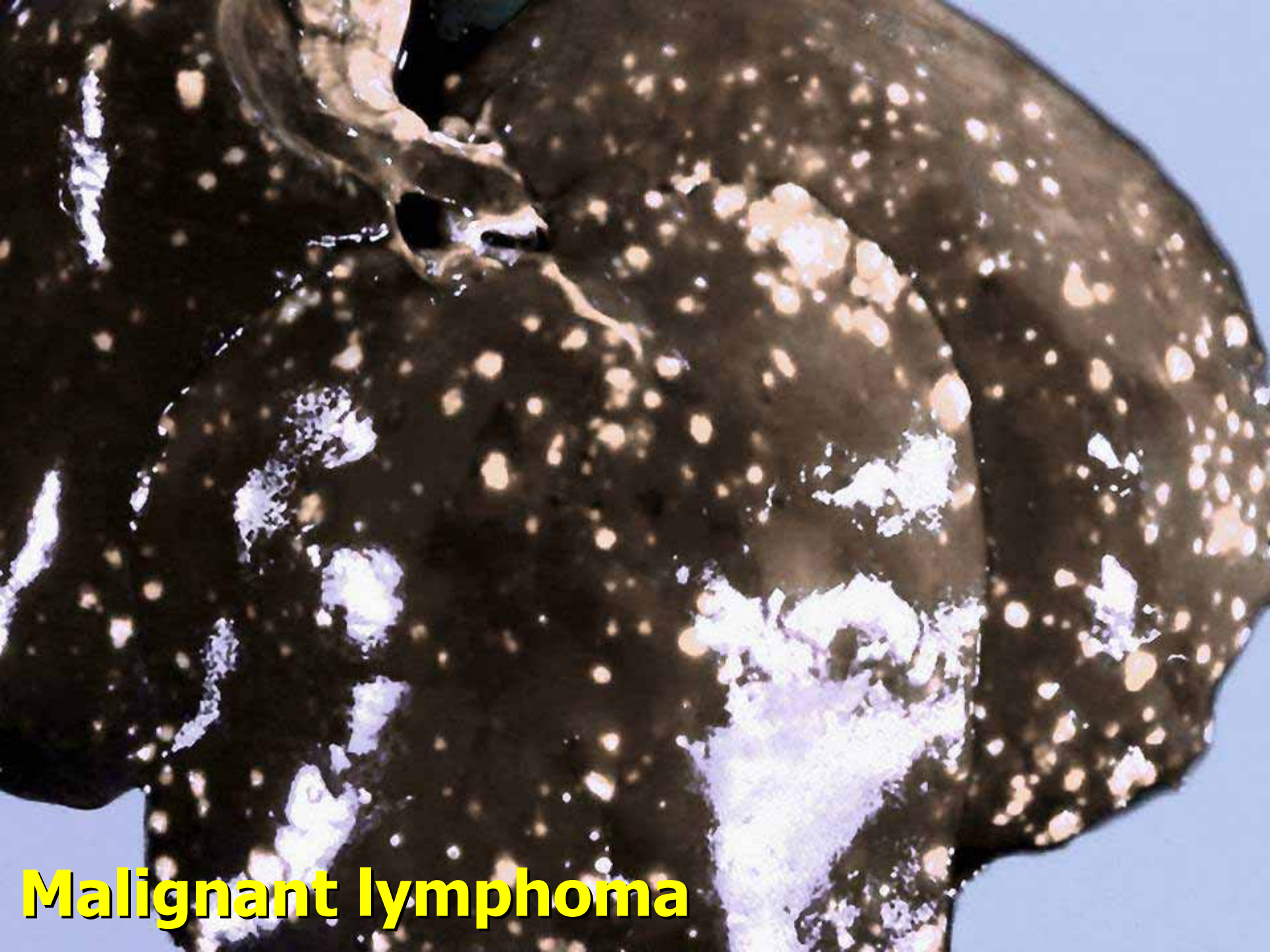
**Malignant lymphoma**



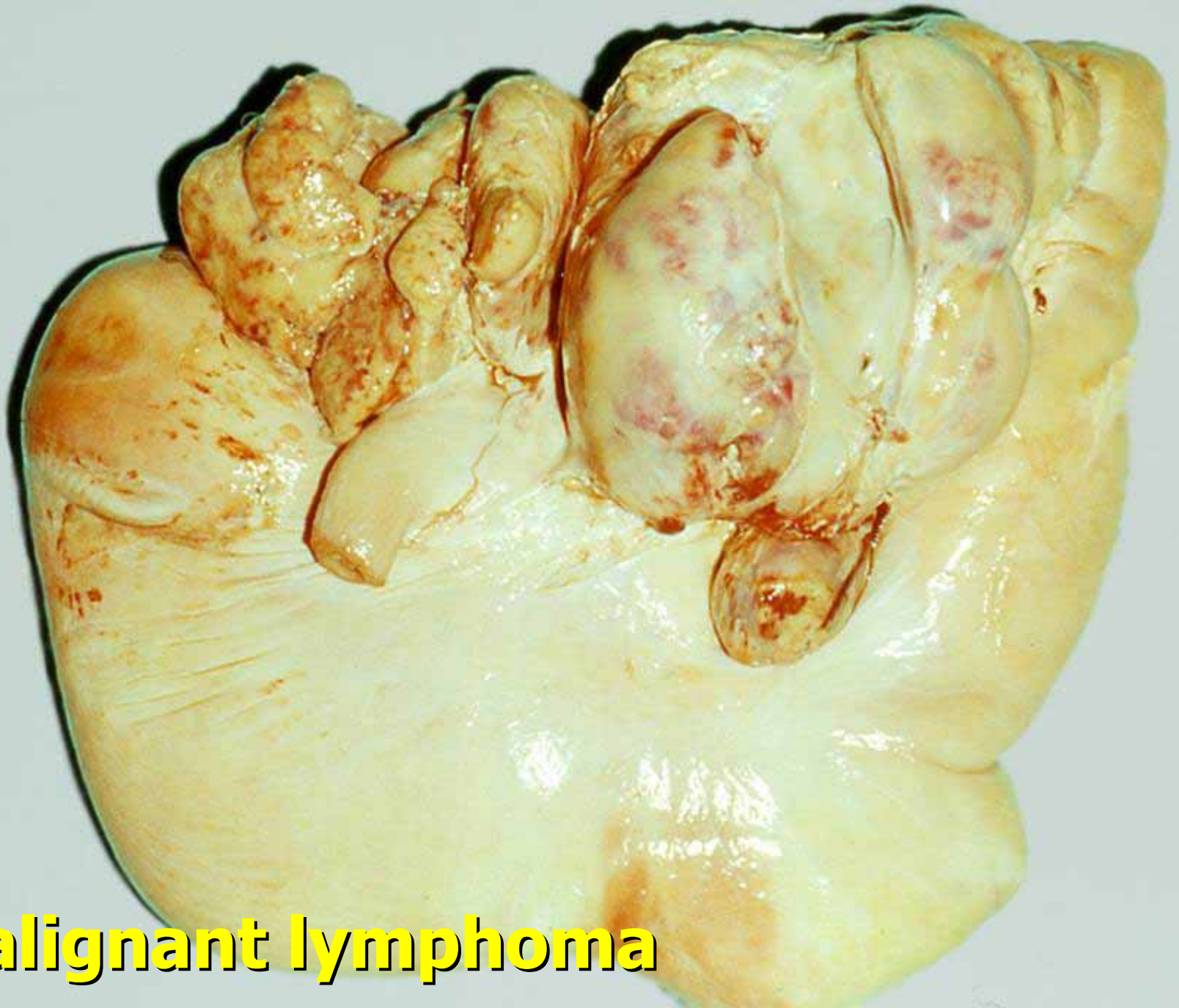


**Malignant lymphoma**



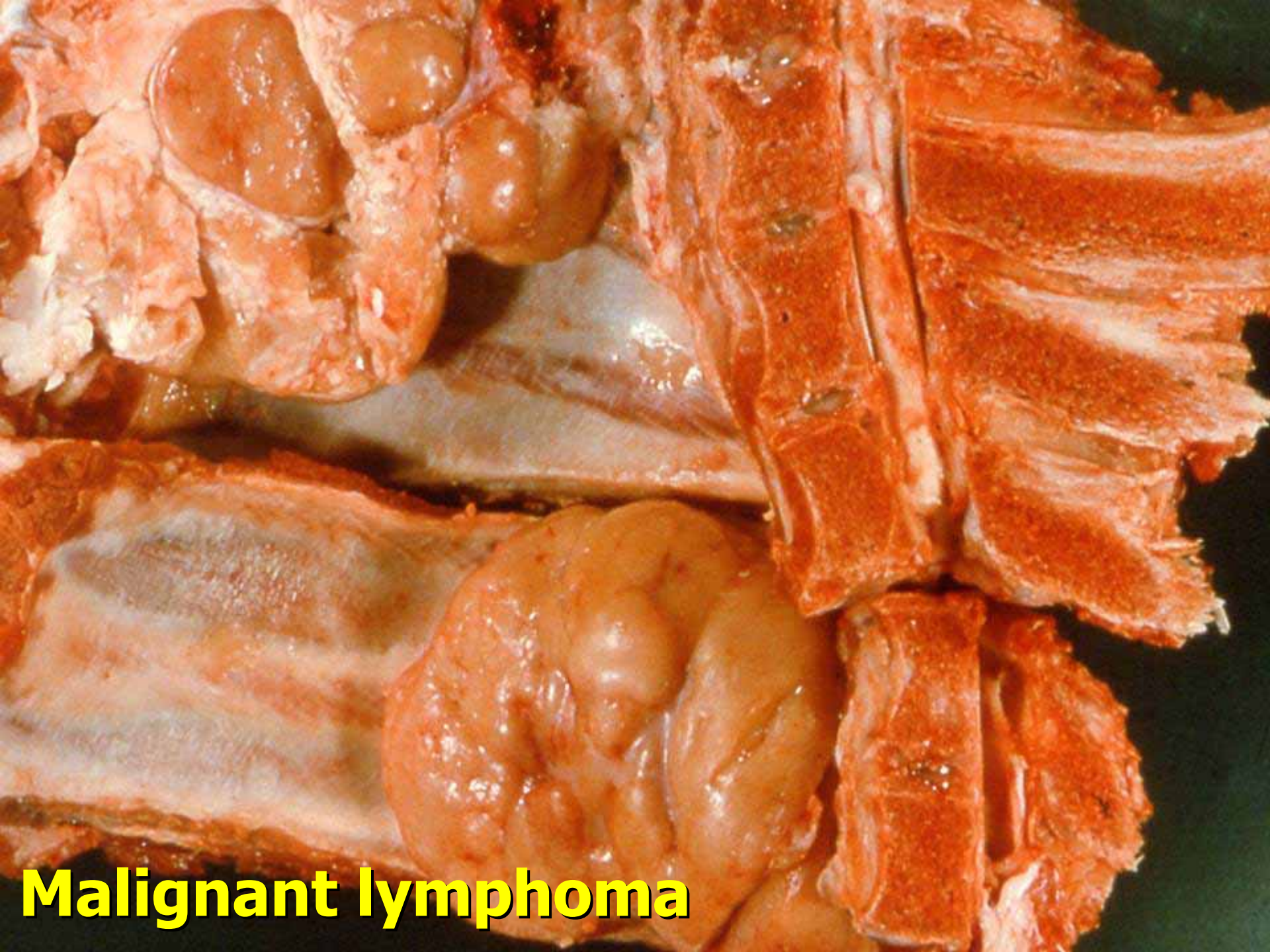


**Malignant lymphoma**



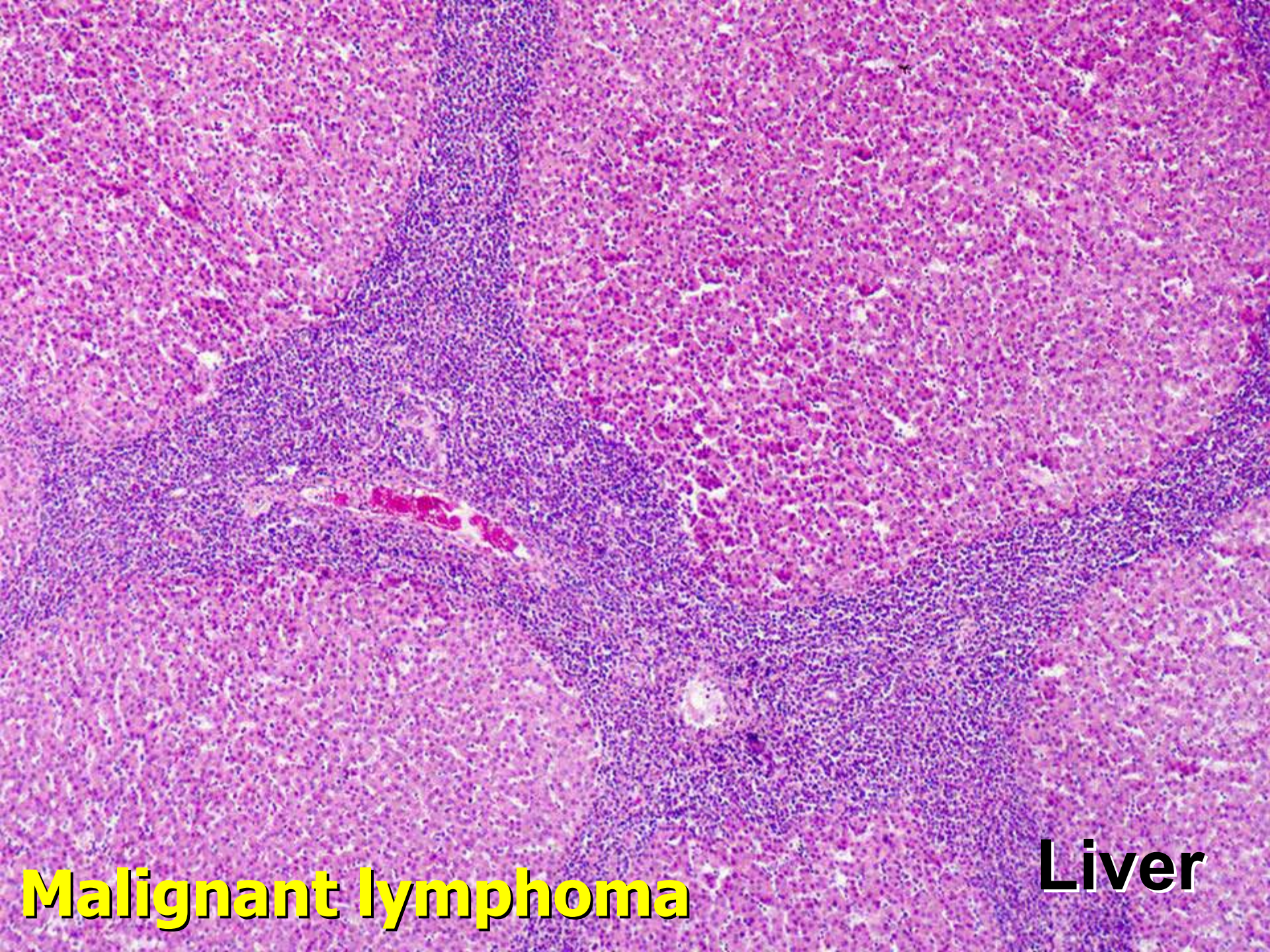
**Malignant lymphoma**





**Malignant lymphoma**

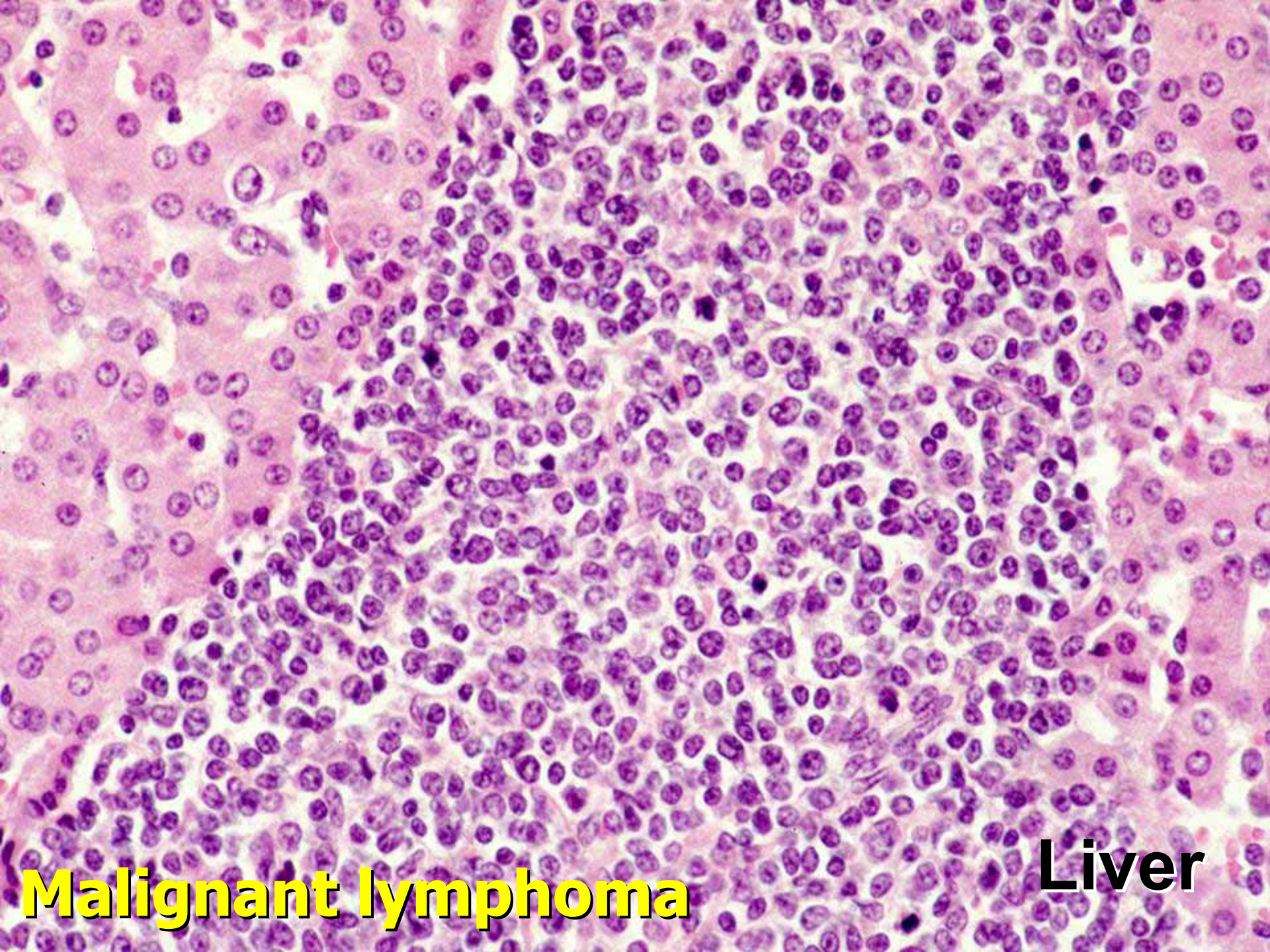




**Malignant lymphoma**

**Liver**

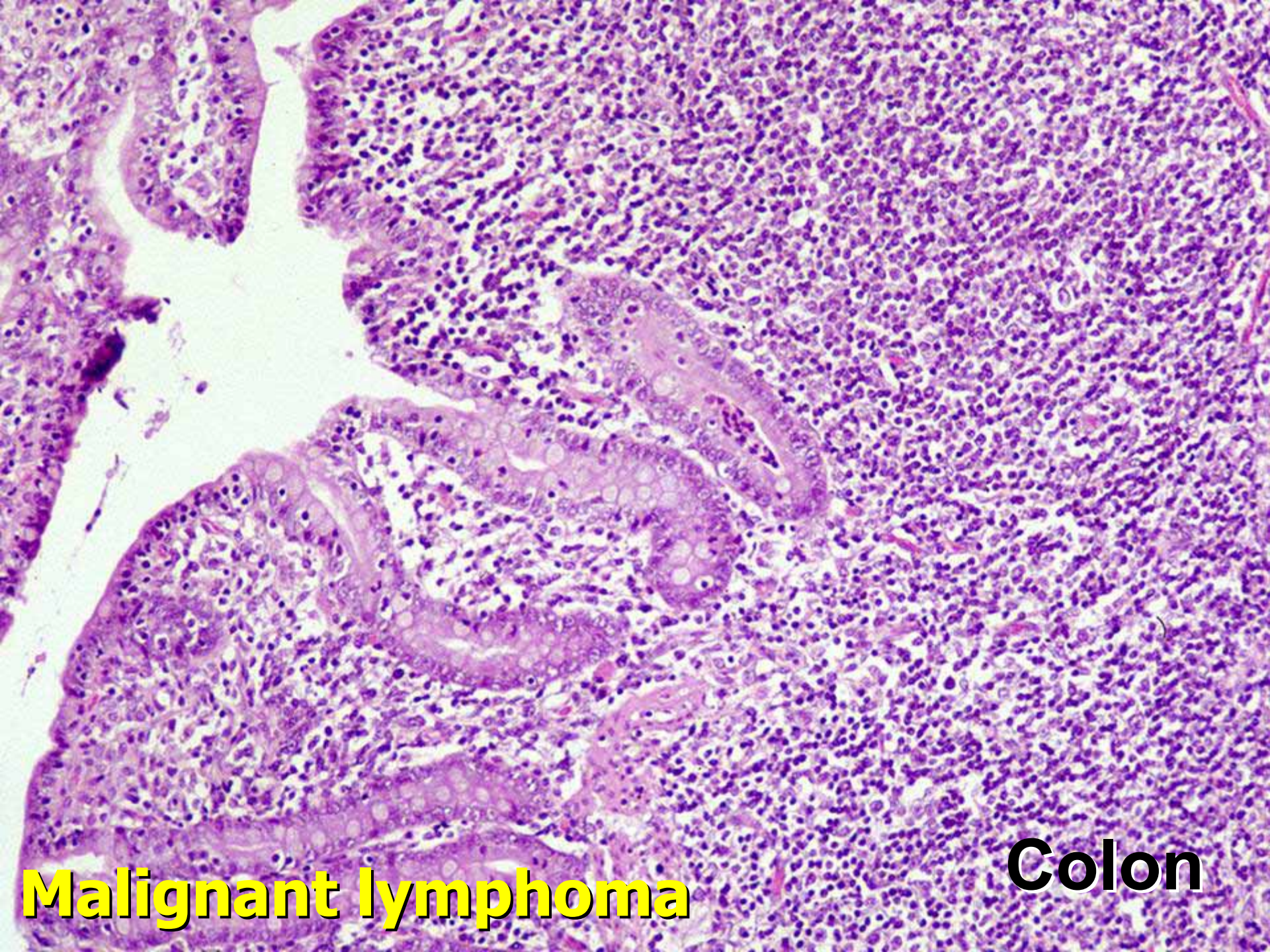




**Malignant lymphoma**

**Liver**

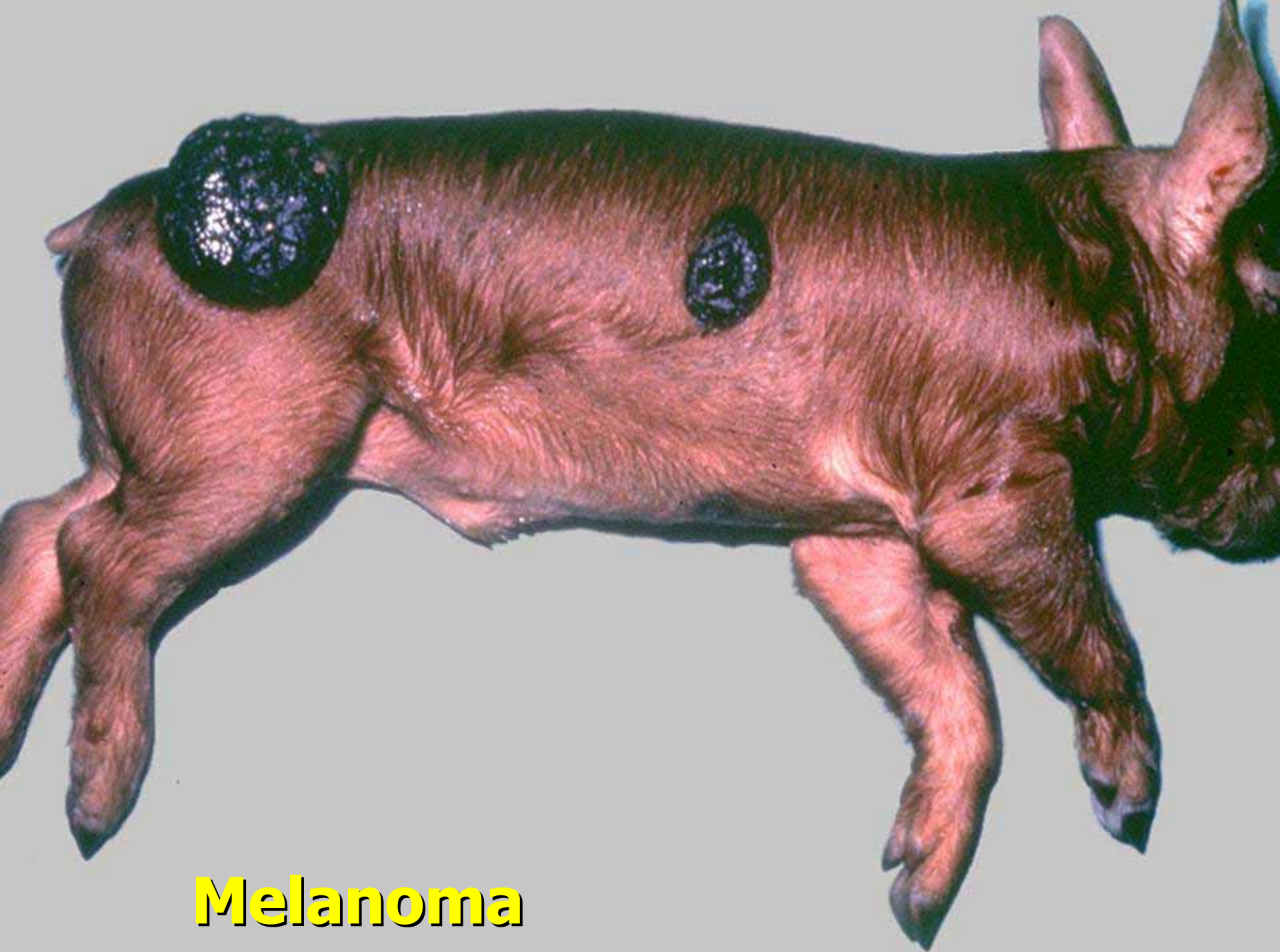



**Malignant lymphoma**

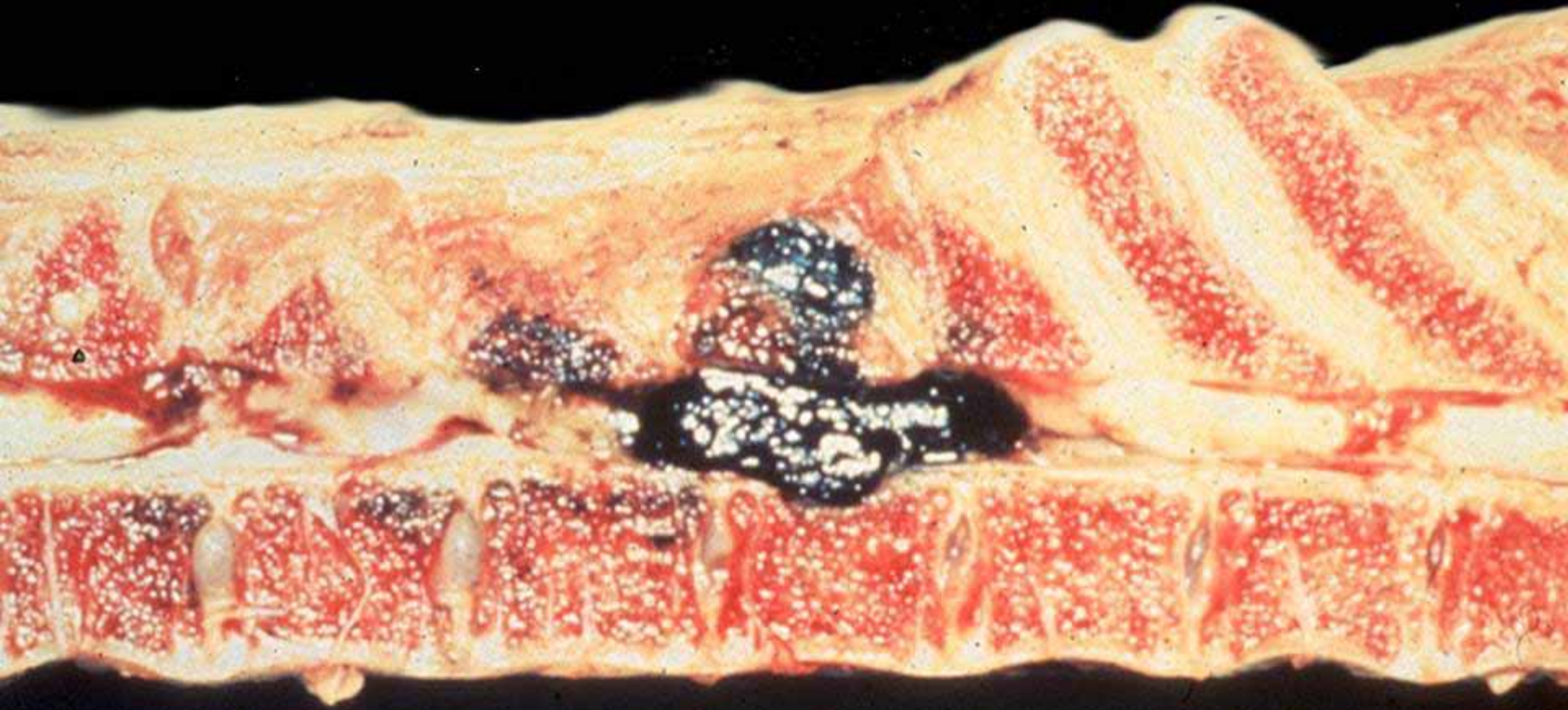
**Colon**





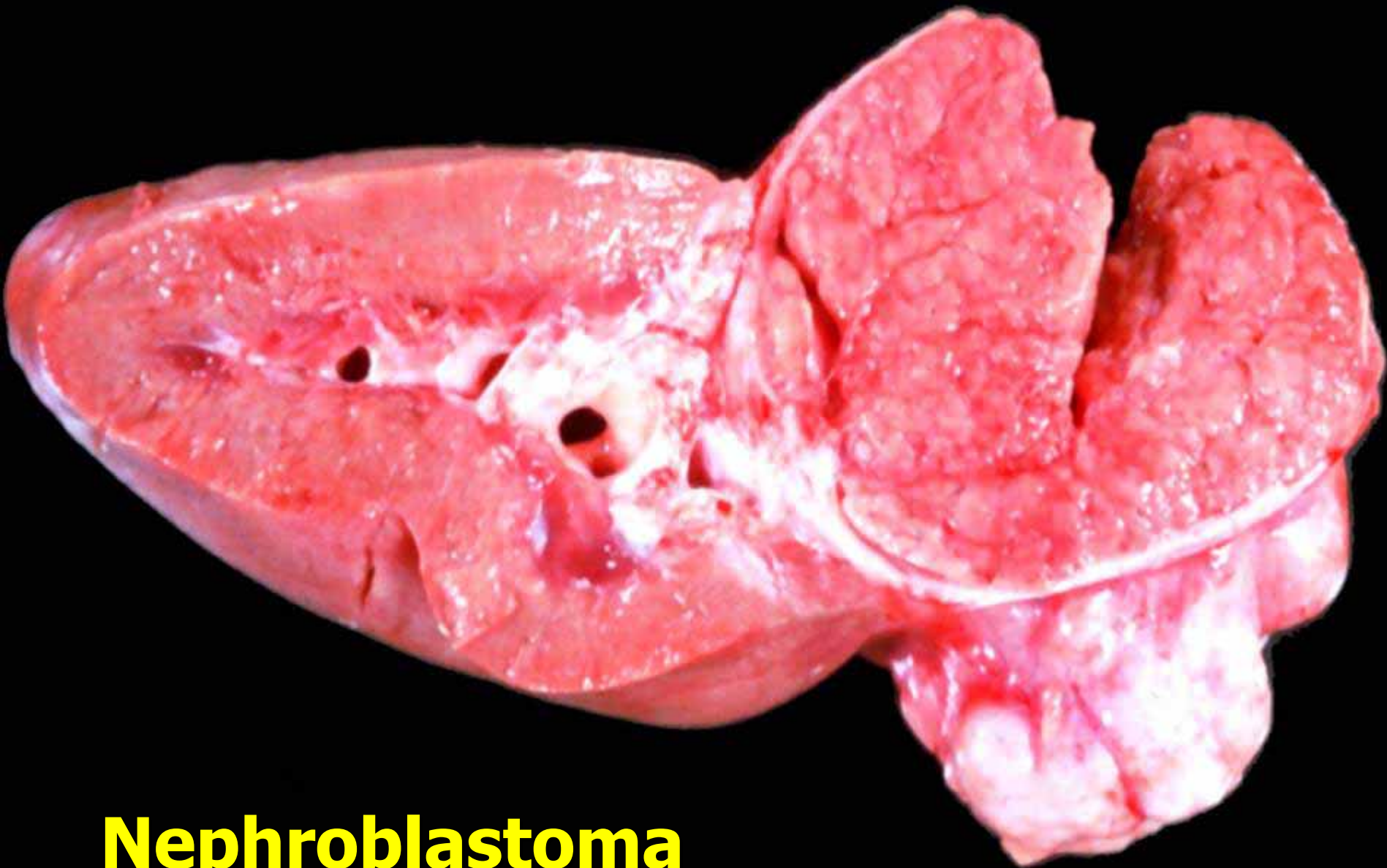**Melanoma**





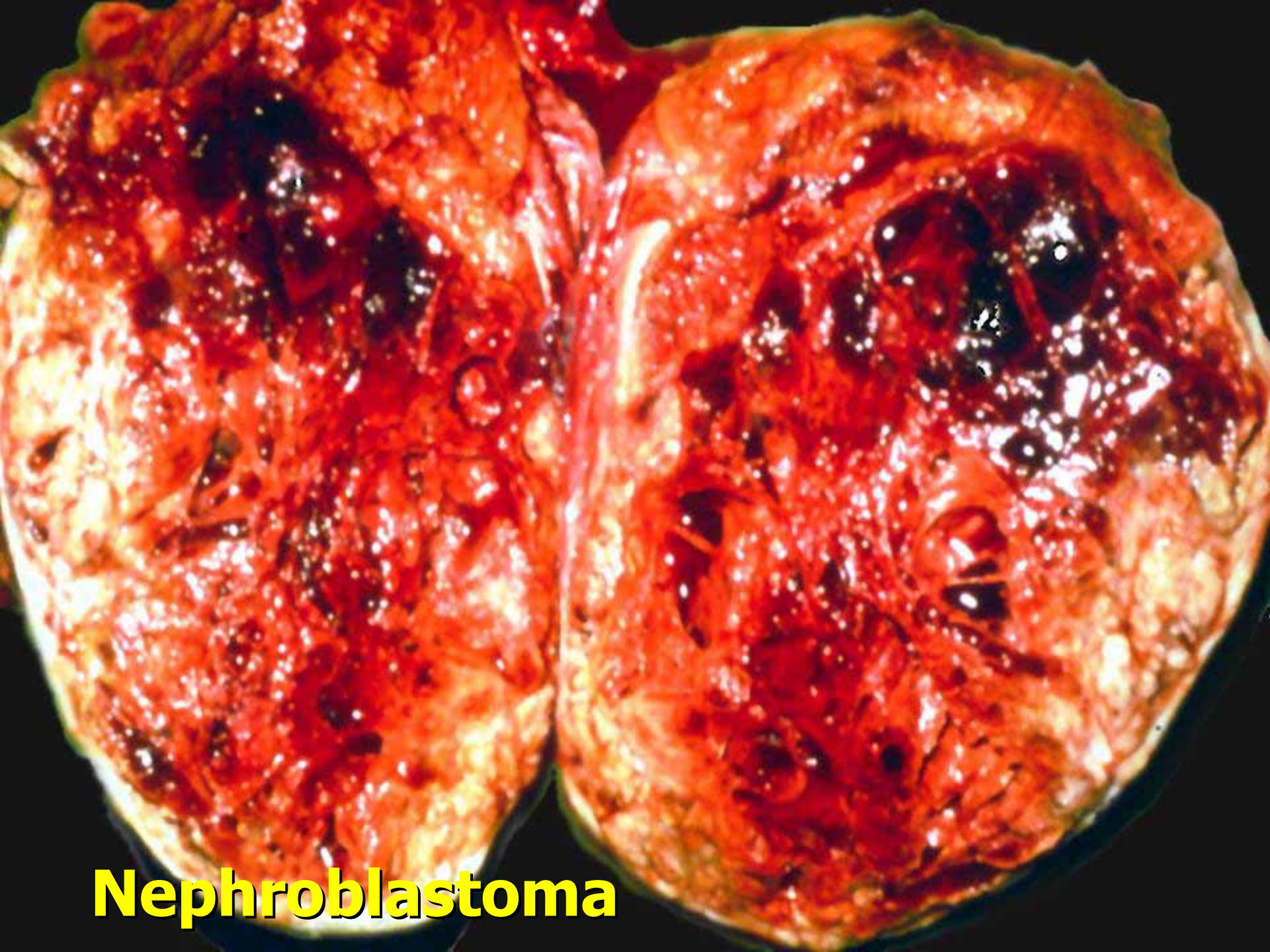**Malignant melanoma**





**Nephroblastoma**





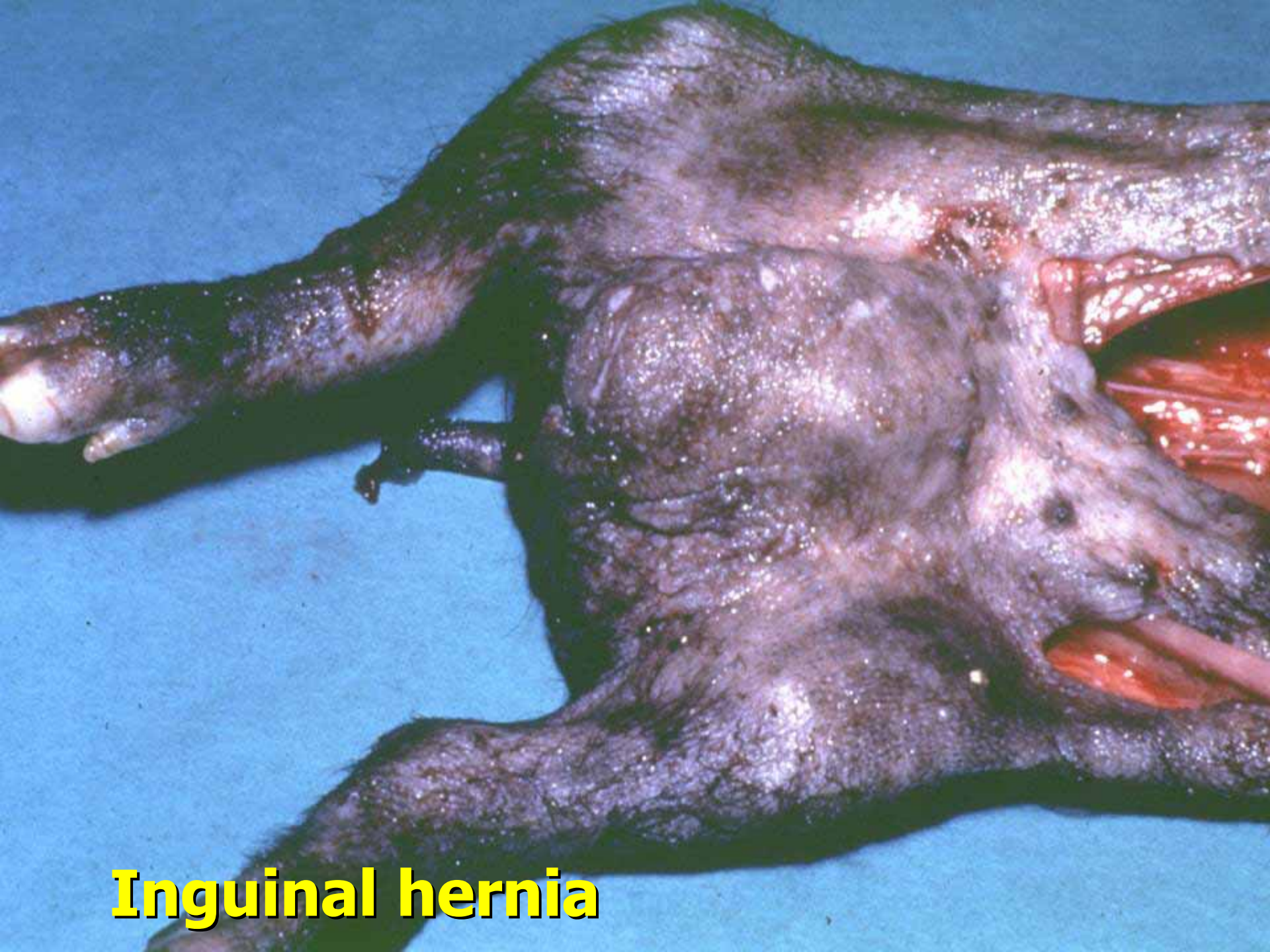
**Nephroblastoma**





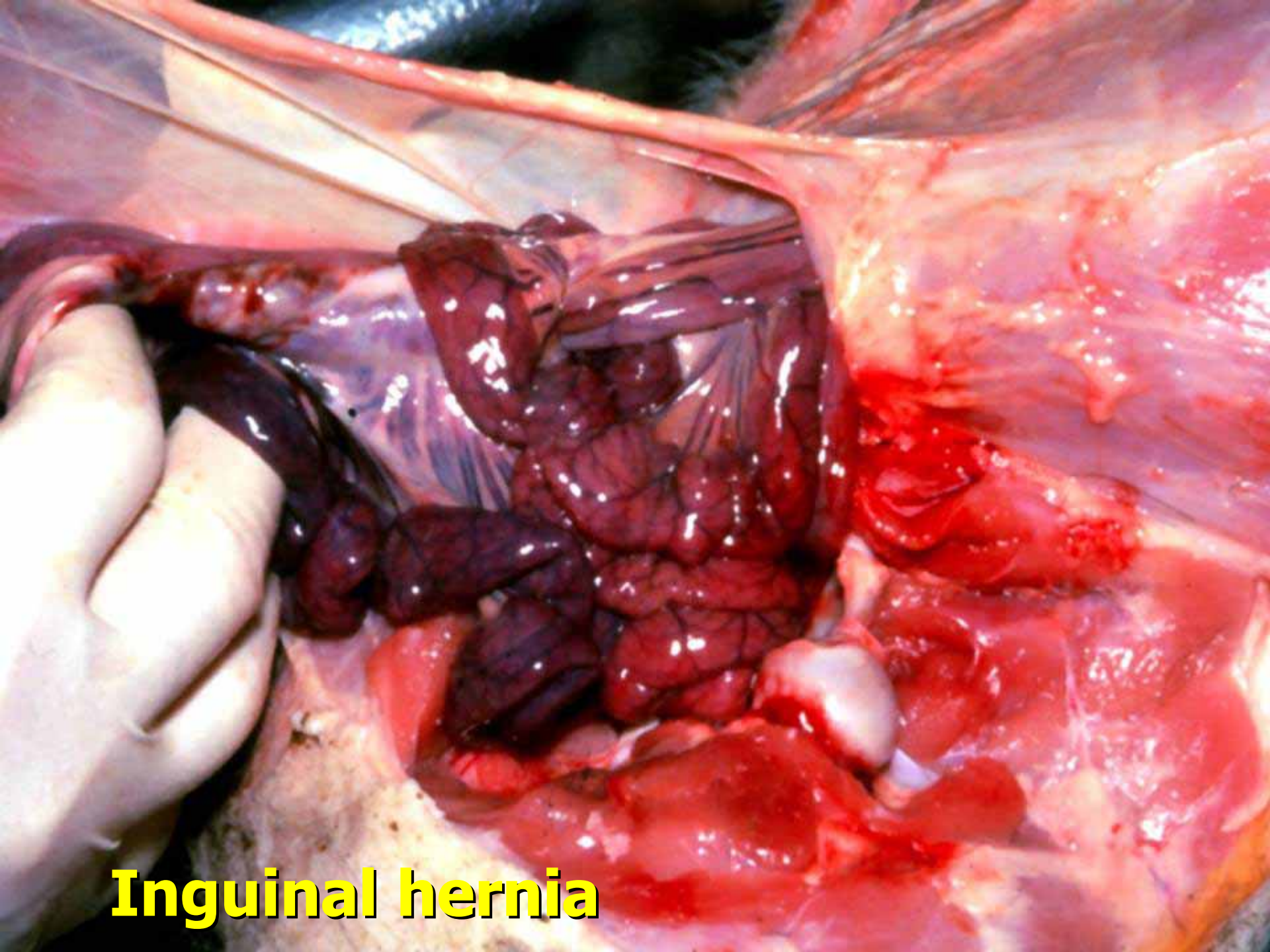
# Congenital Hereditary





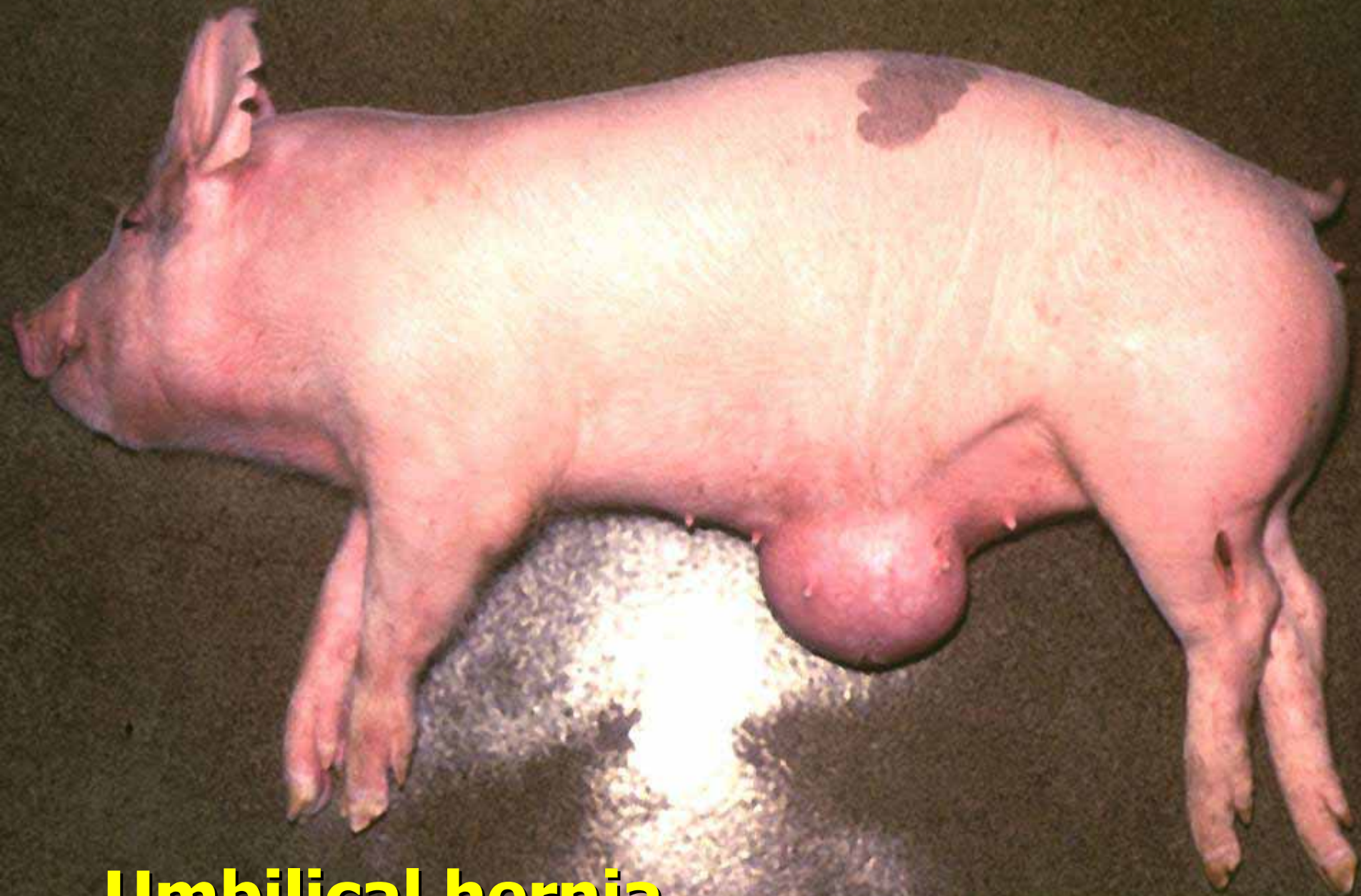**Inguinal hernia**





**Inguinal hernia**





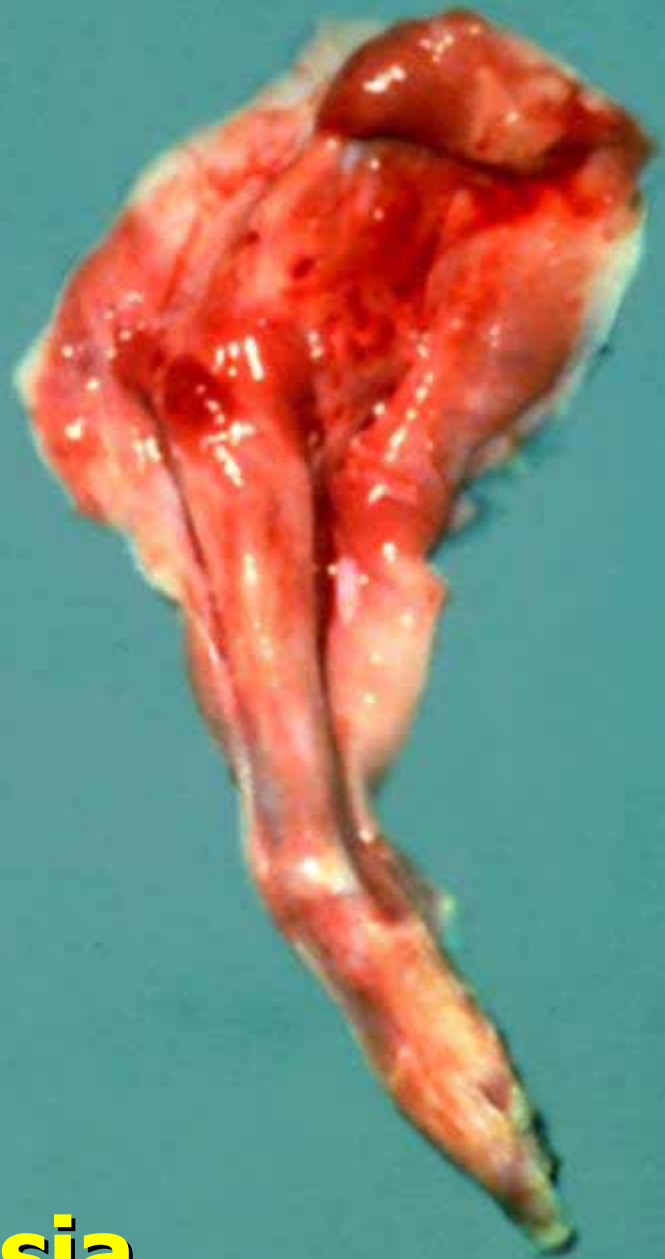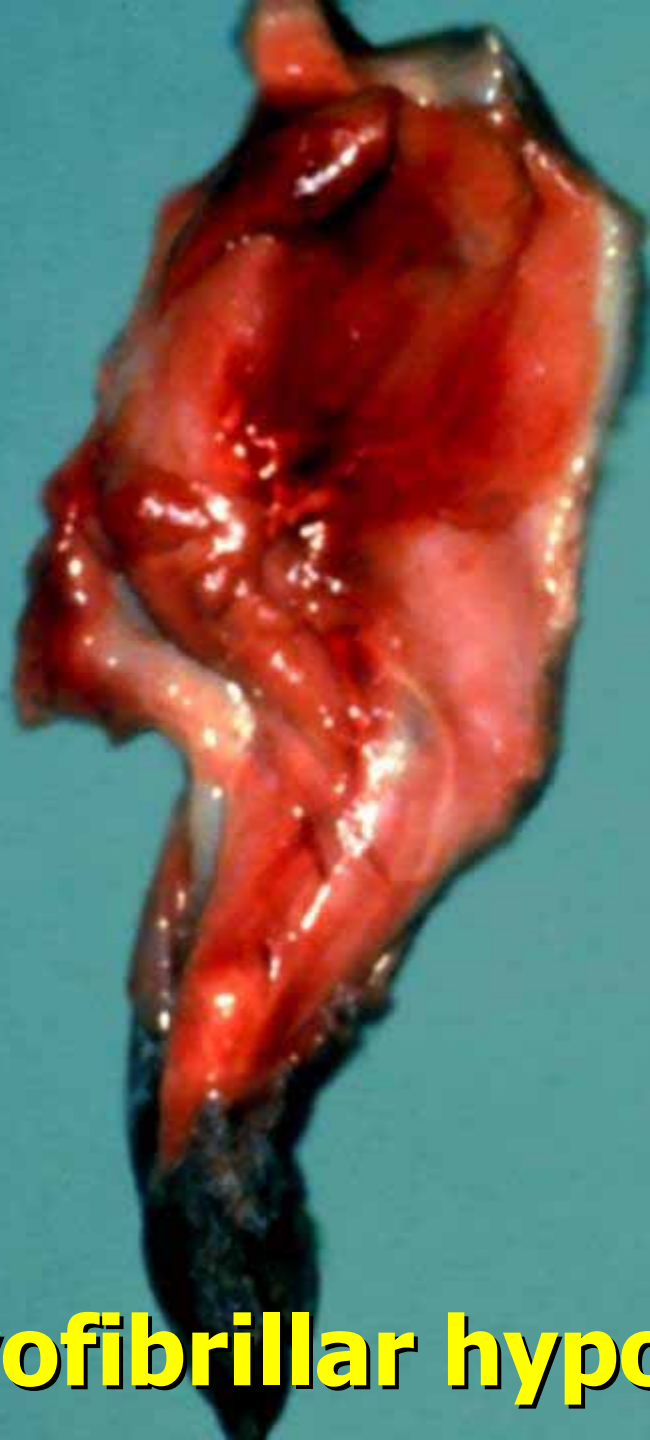**Umbilical hernia**





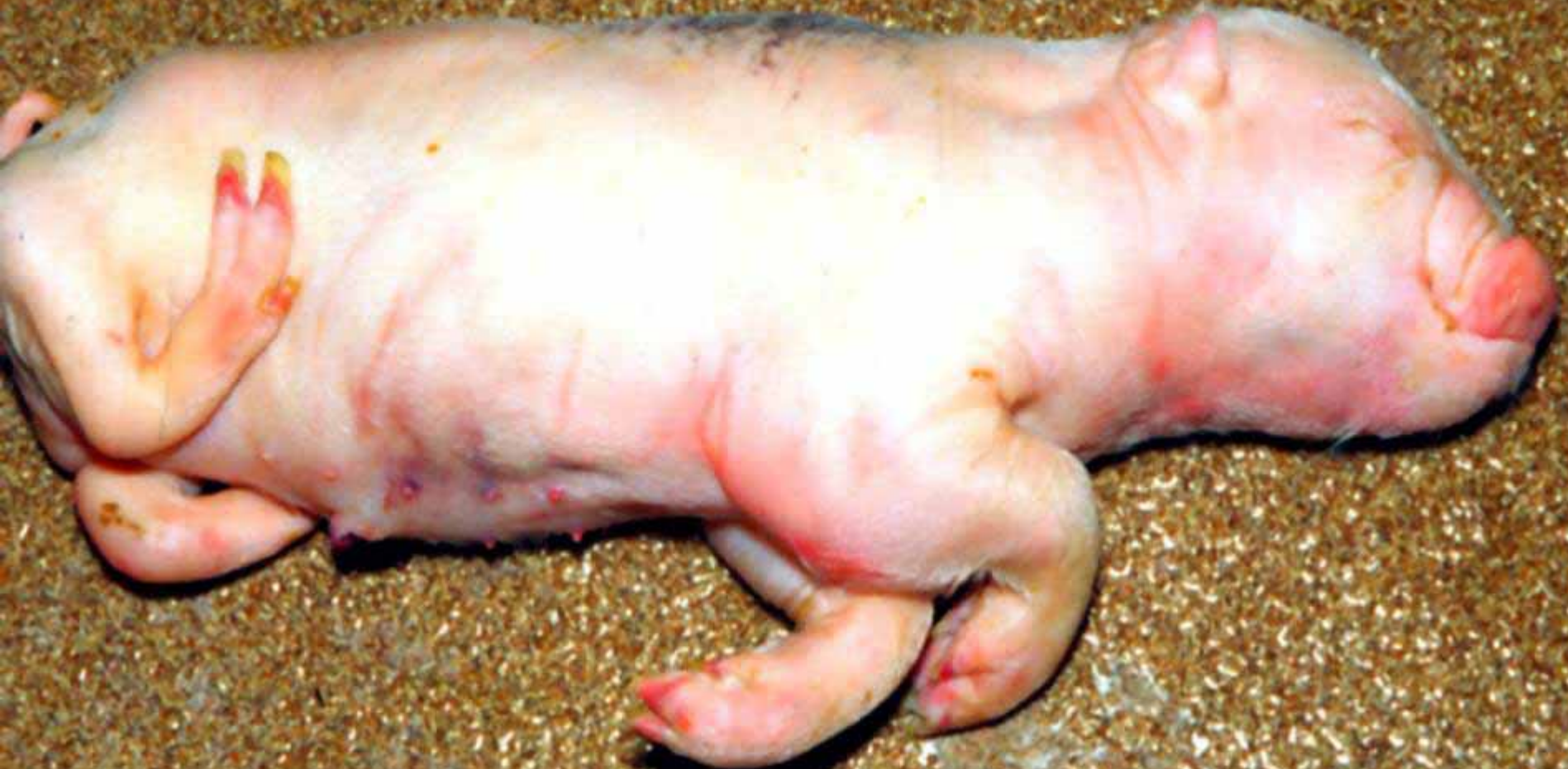**Myofibrillar hypoplasia**





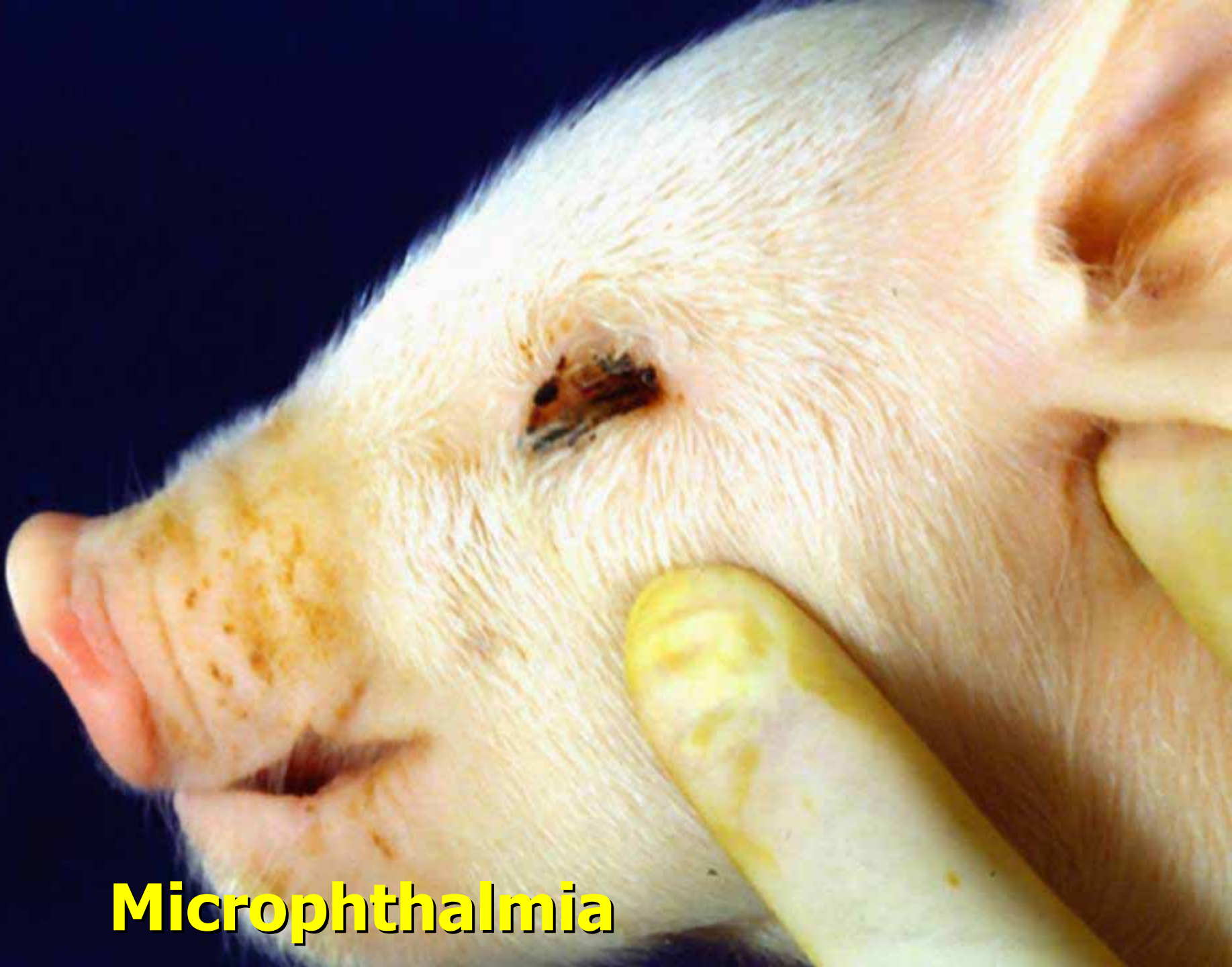**Myofibrillar hypoplasia**





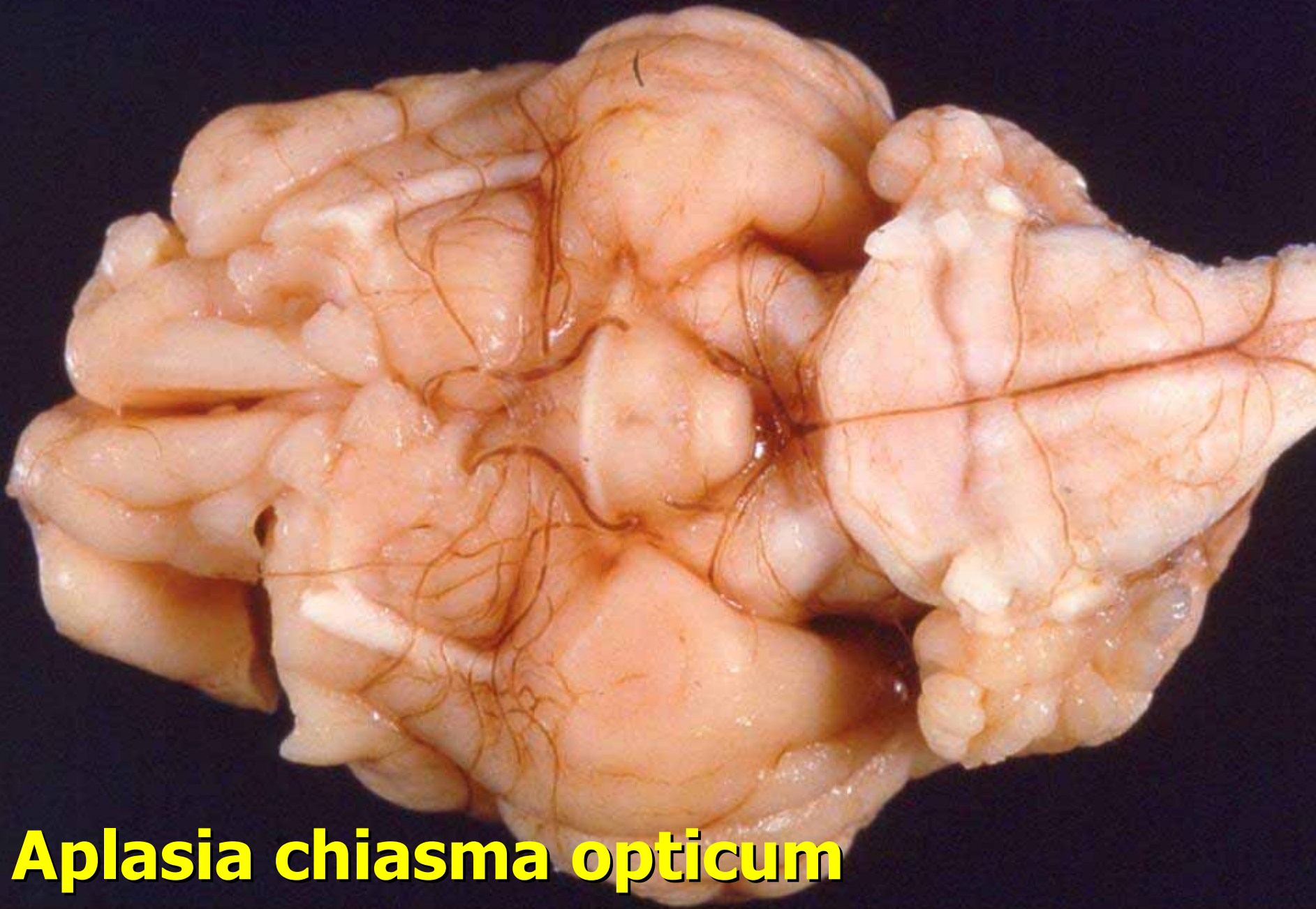**Arthrogryposis**





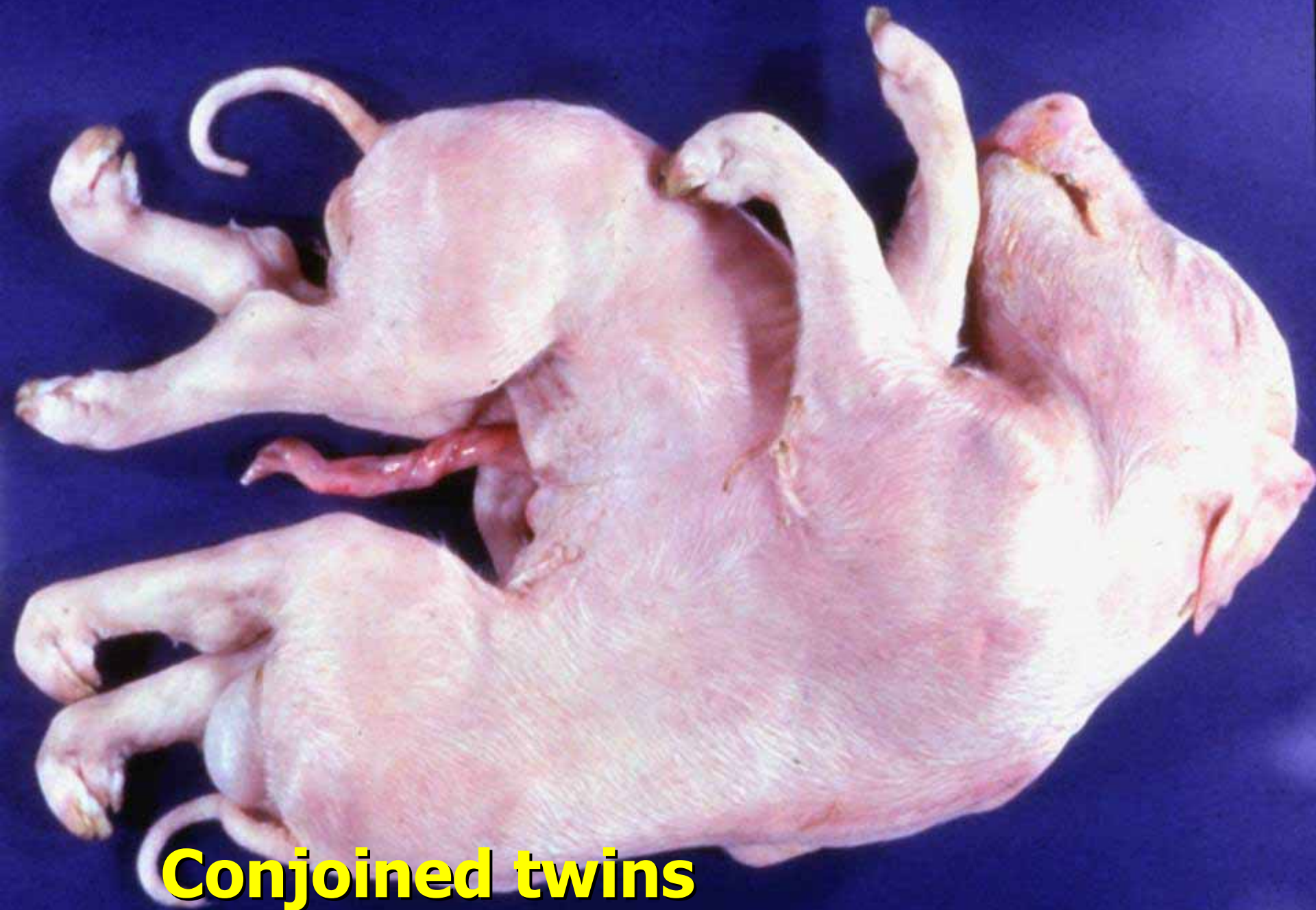**Microphthalmia**





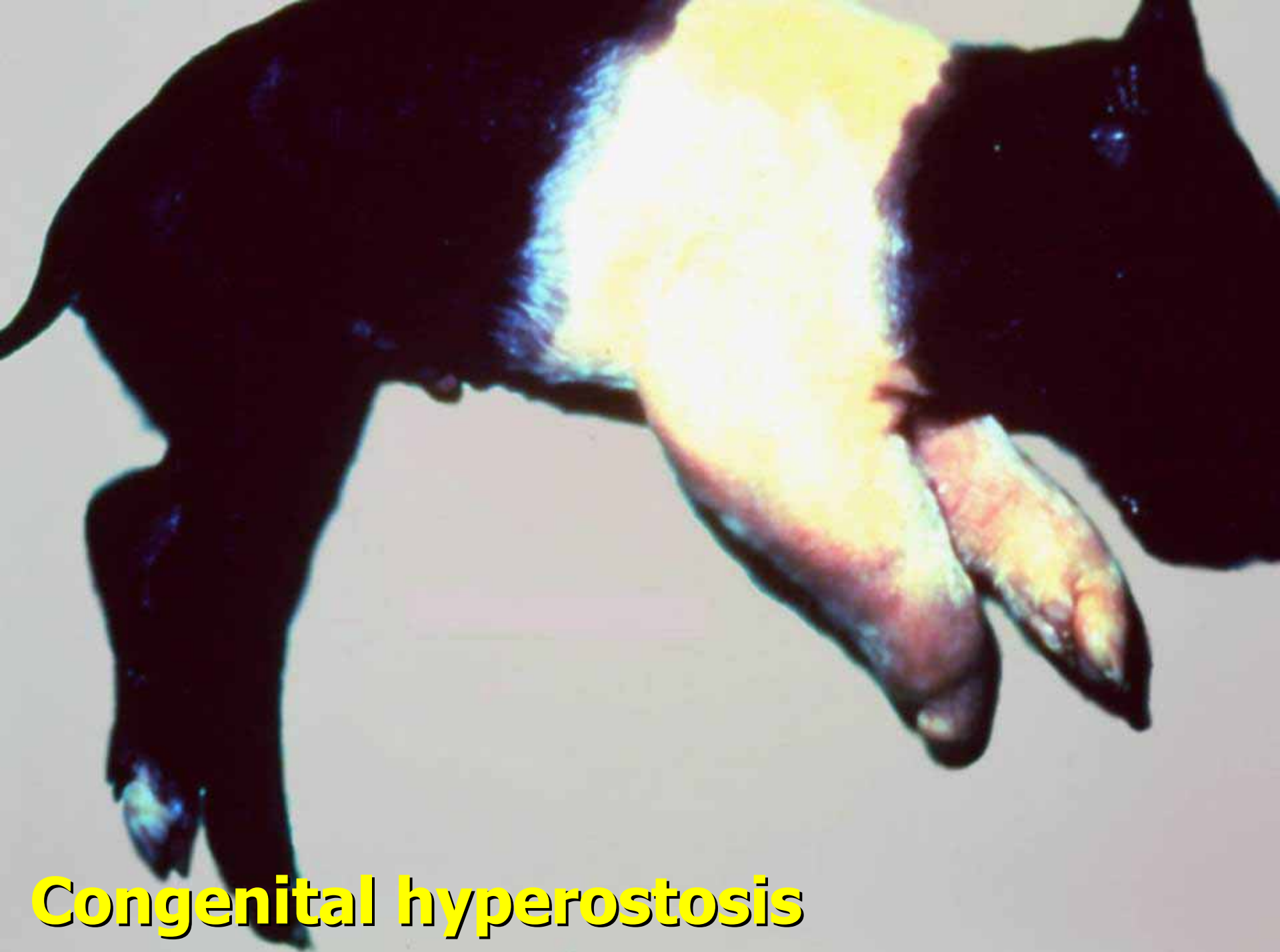**Aplasia chiasma opticum**





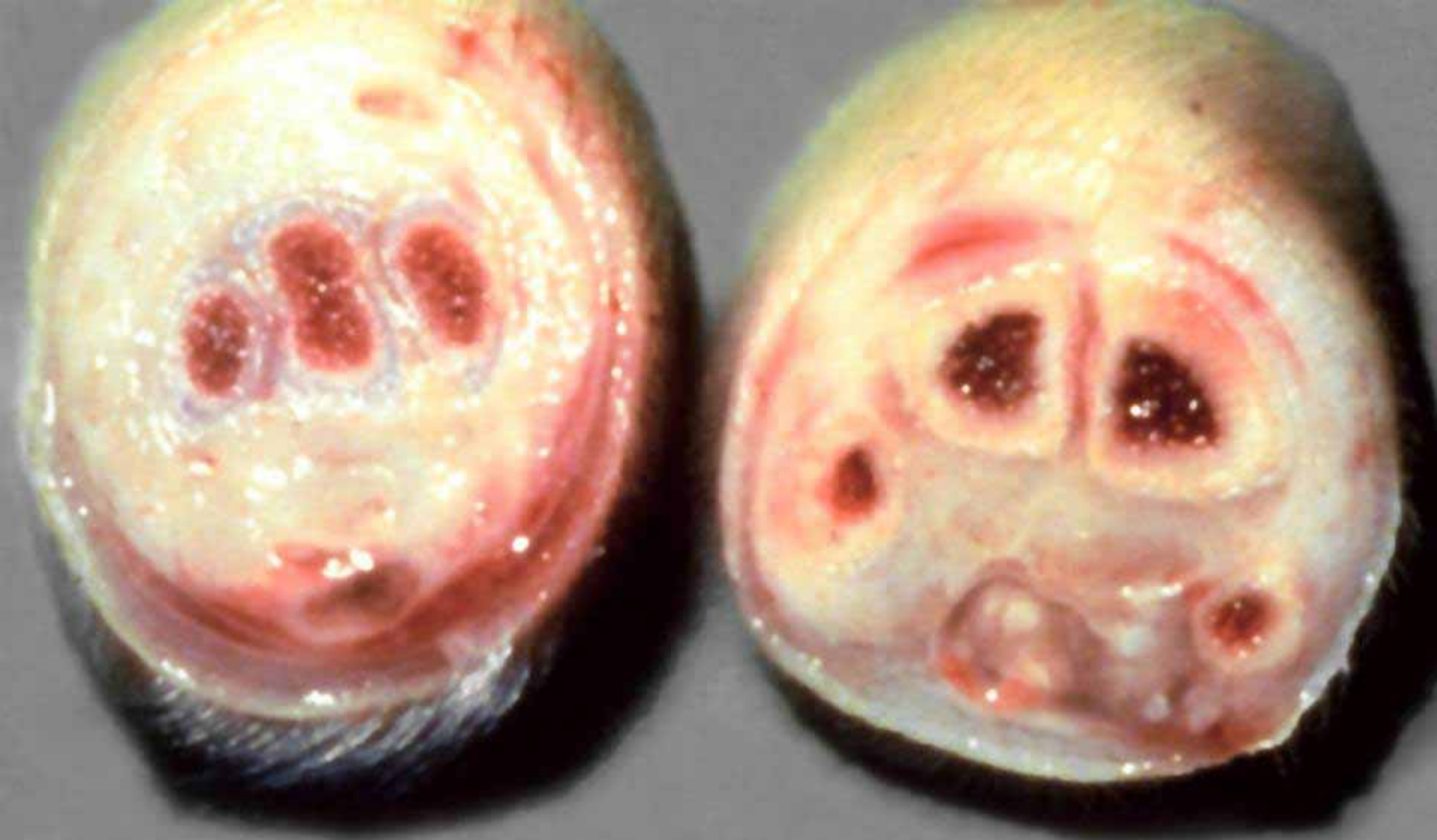**Conjoined twins**





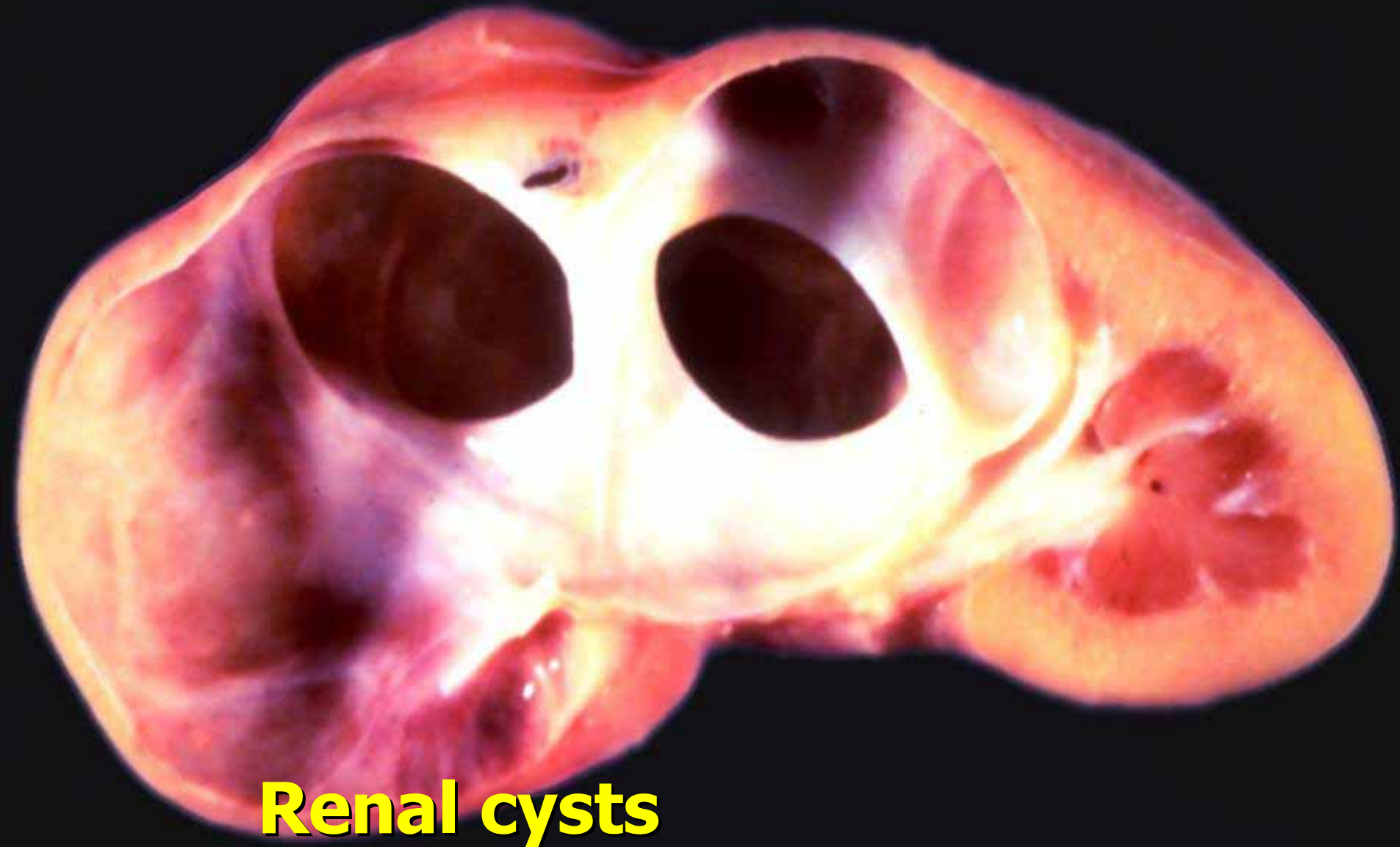
**Congenital hyperostosis**





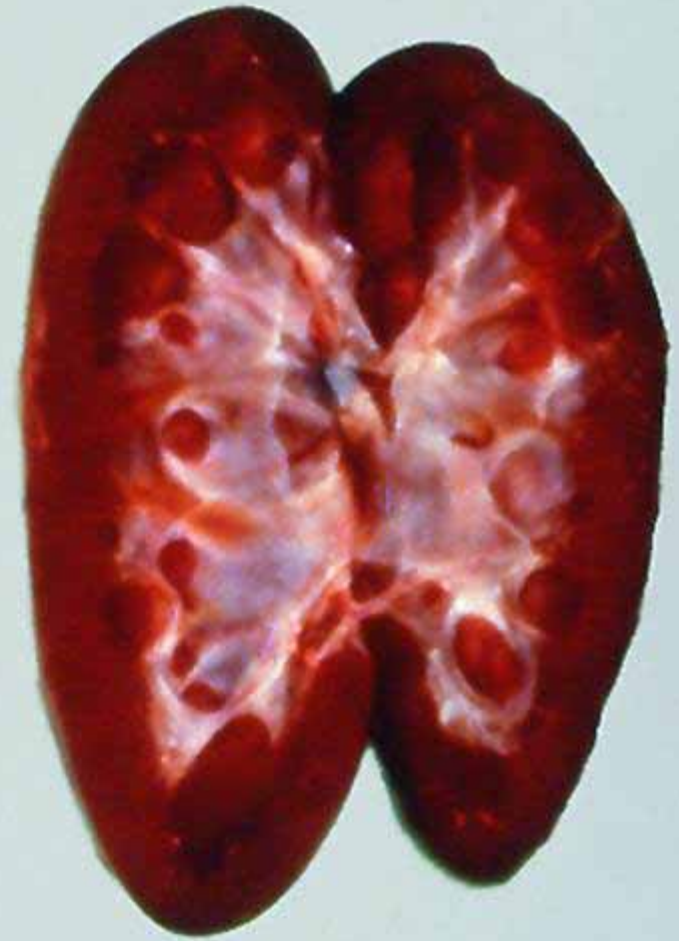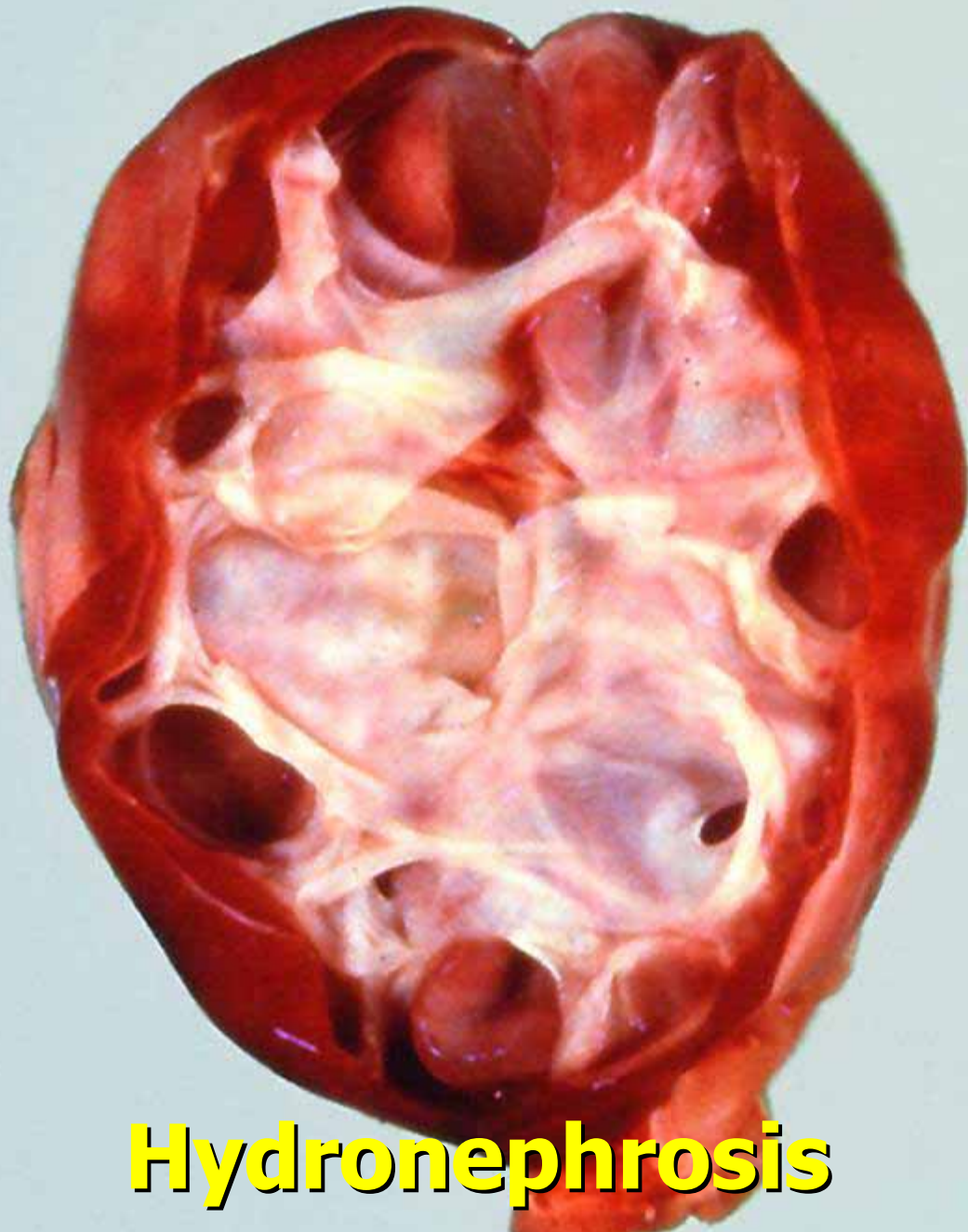
**Congenital hyperostosis**





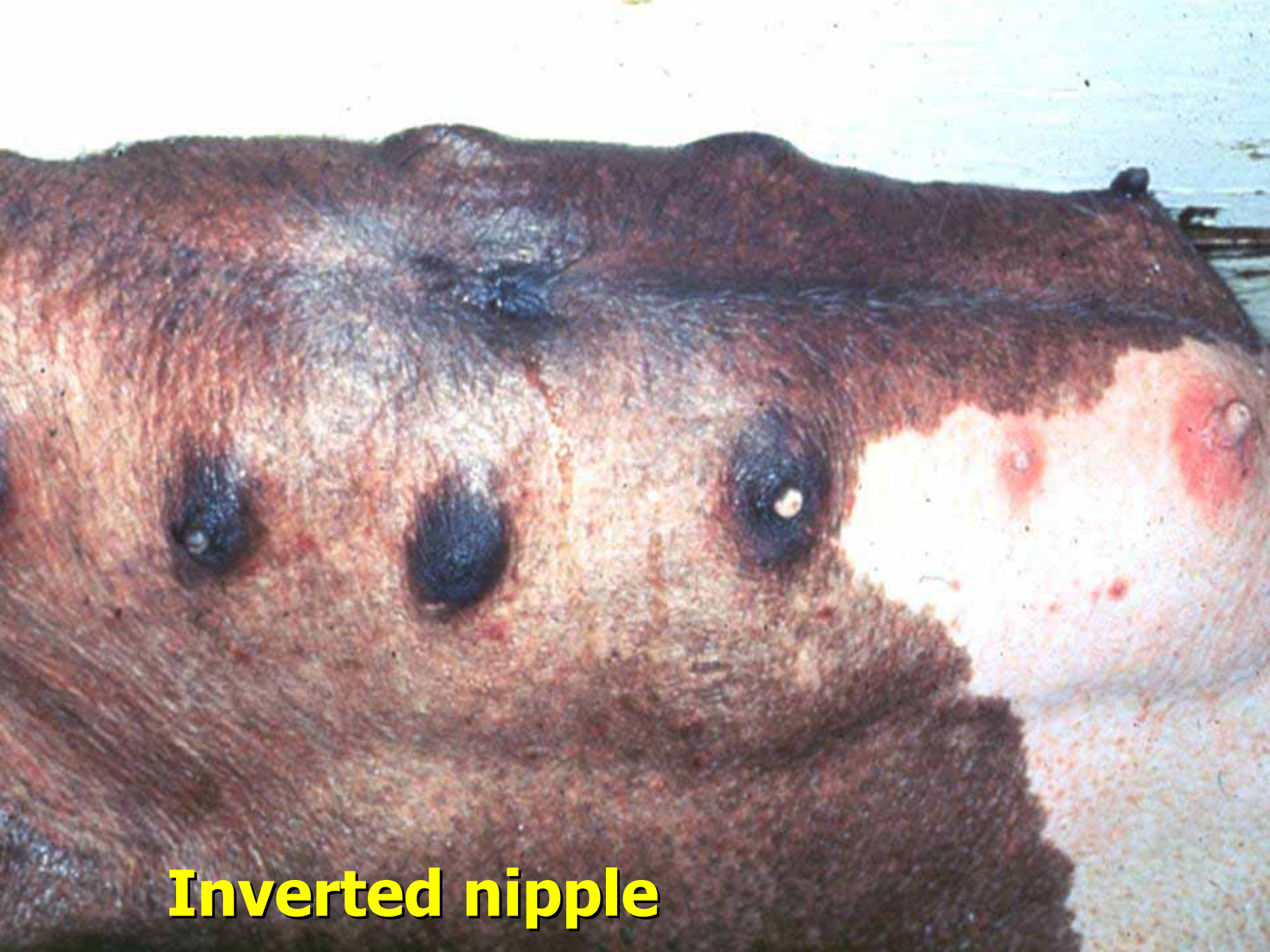
**Renal cysts**





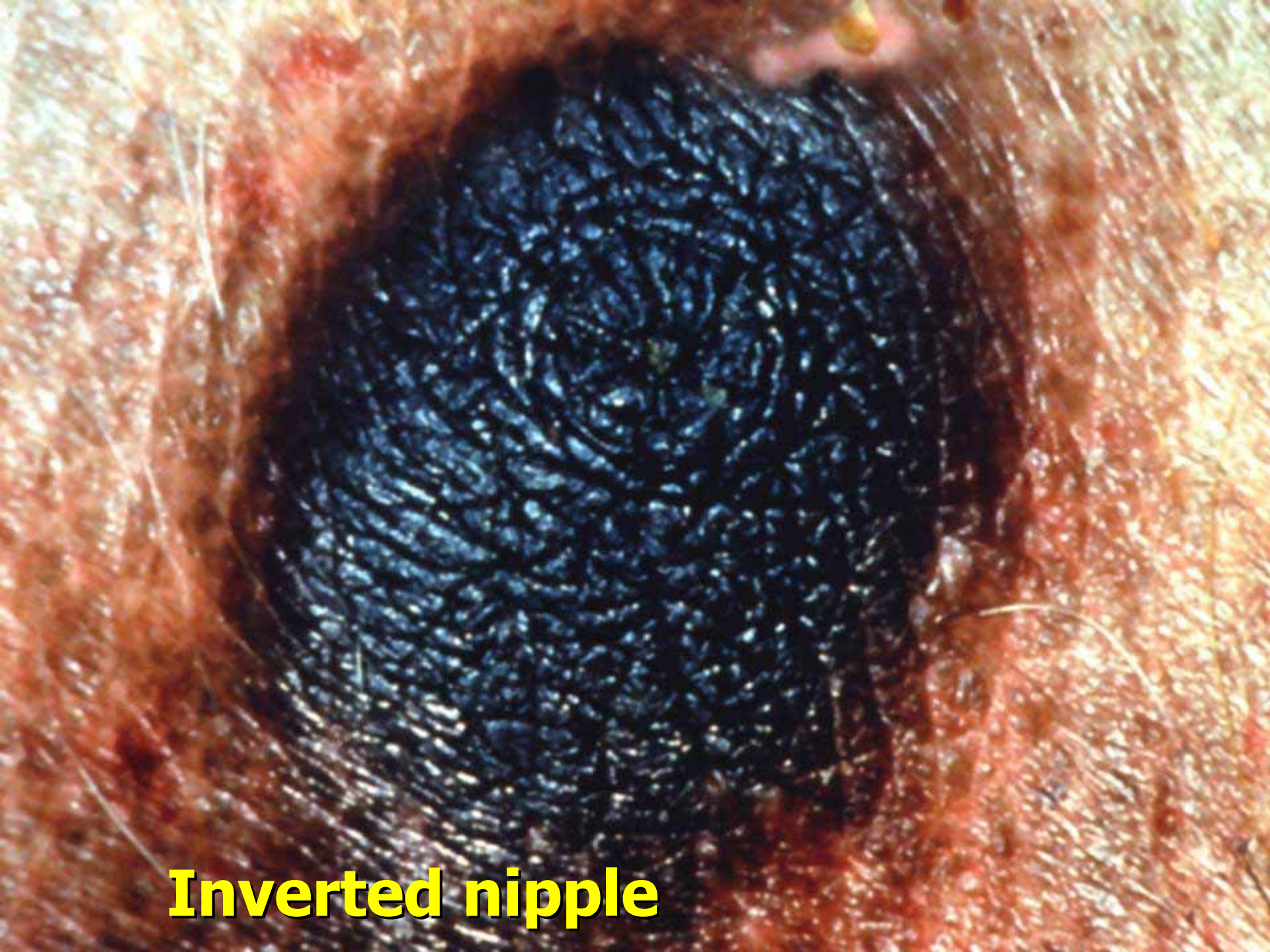**Hydronephrosis**





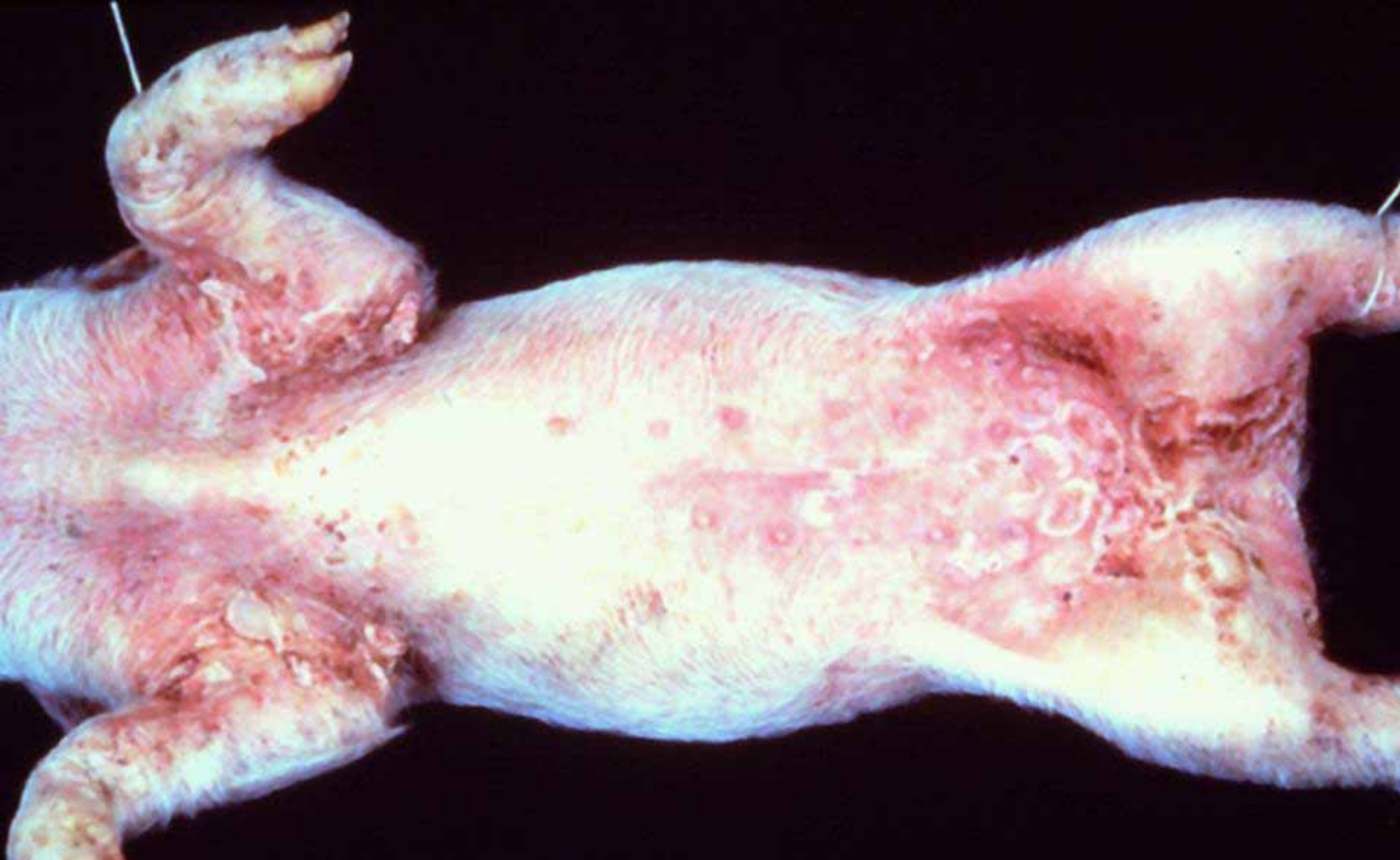**Inverted nipple**





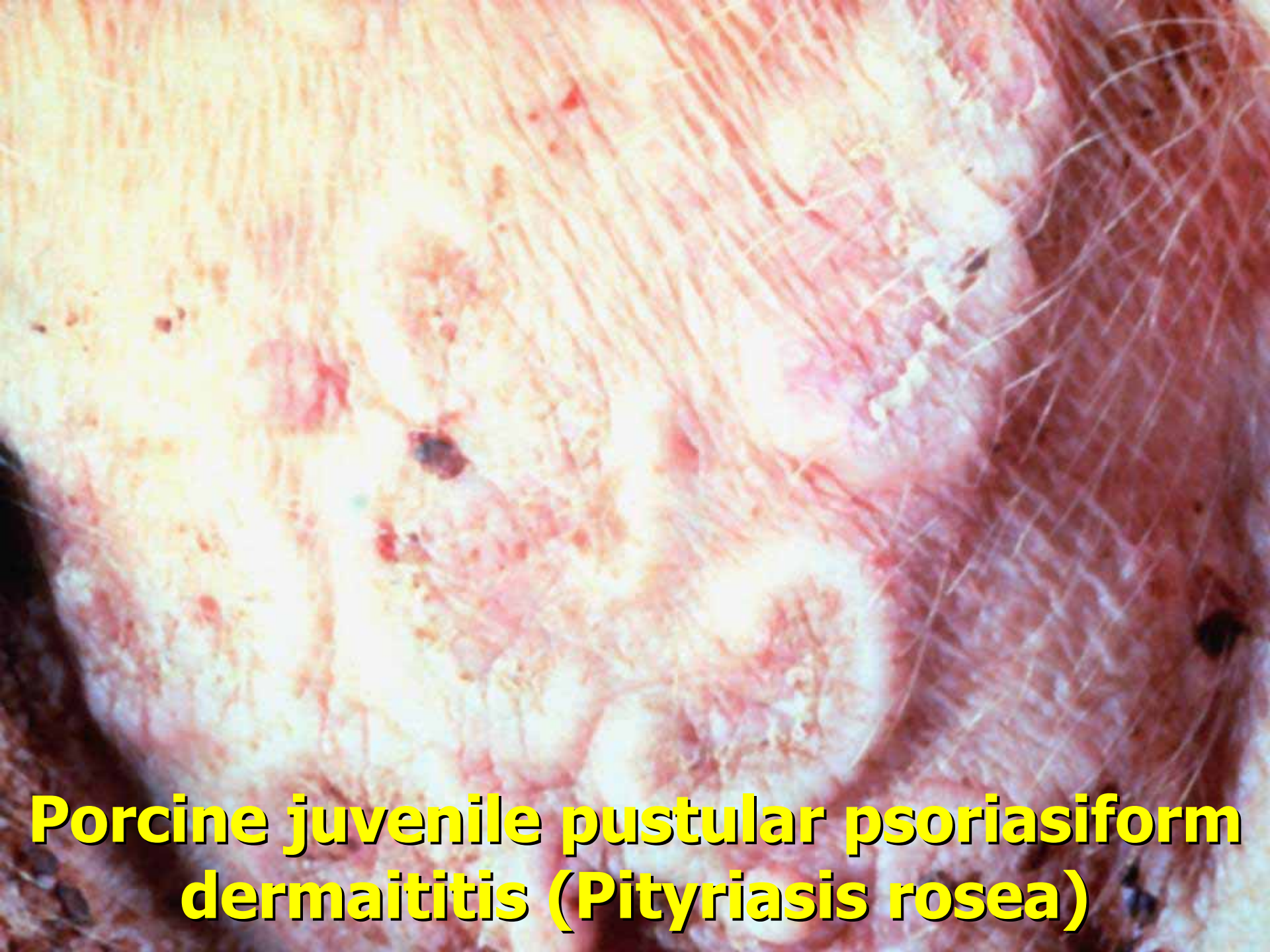**Inverted nipple**





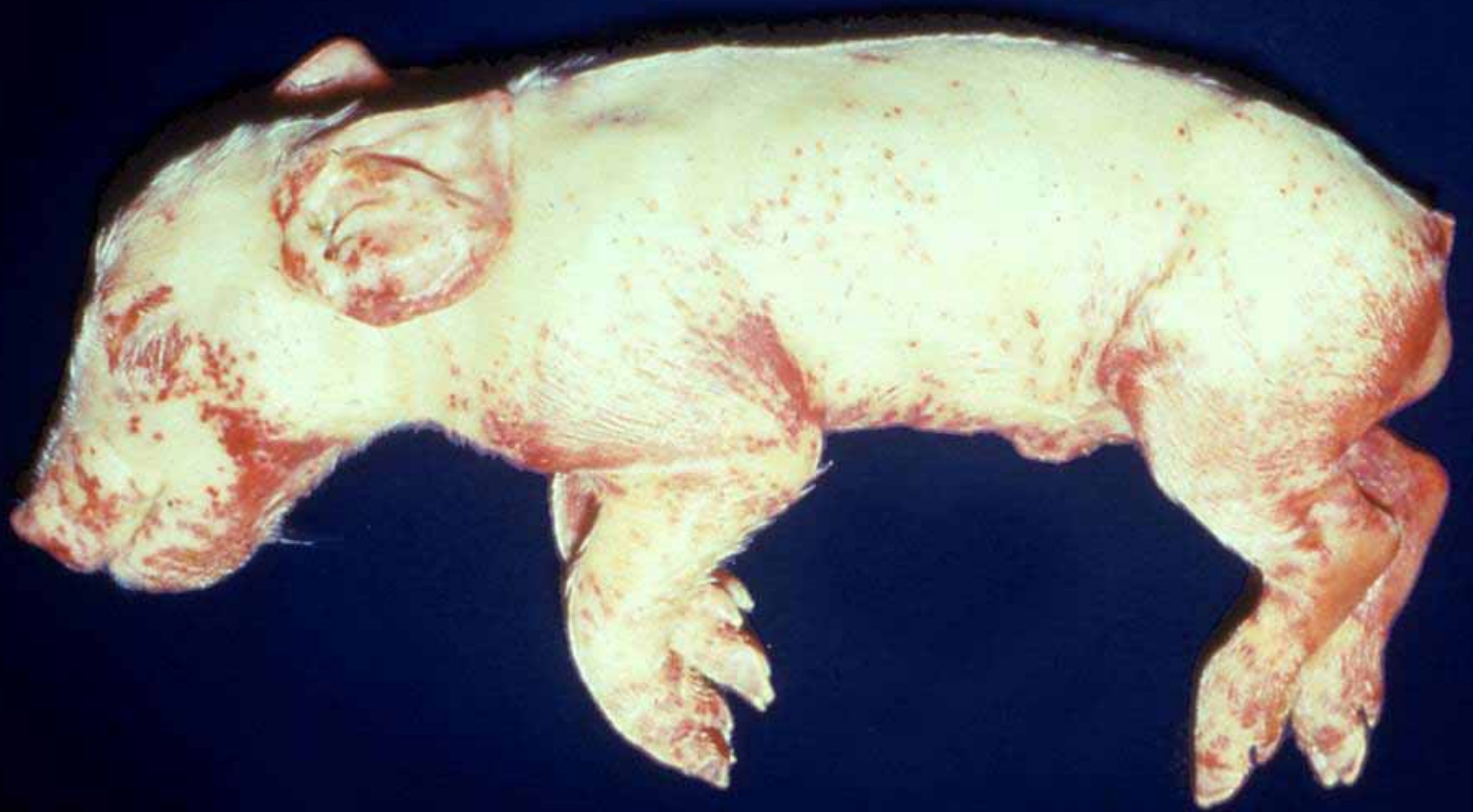**Porcine juvenile pustular psoriasiform dermatitis (Pityriasis rosea)**





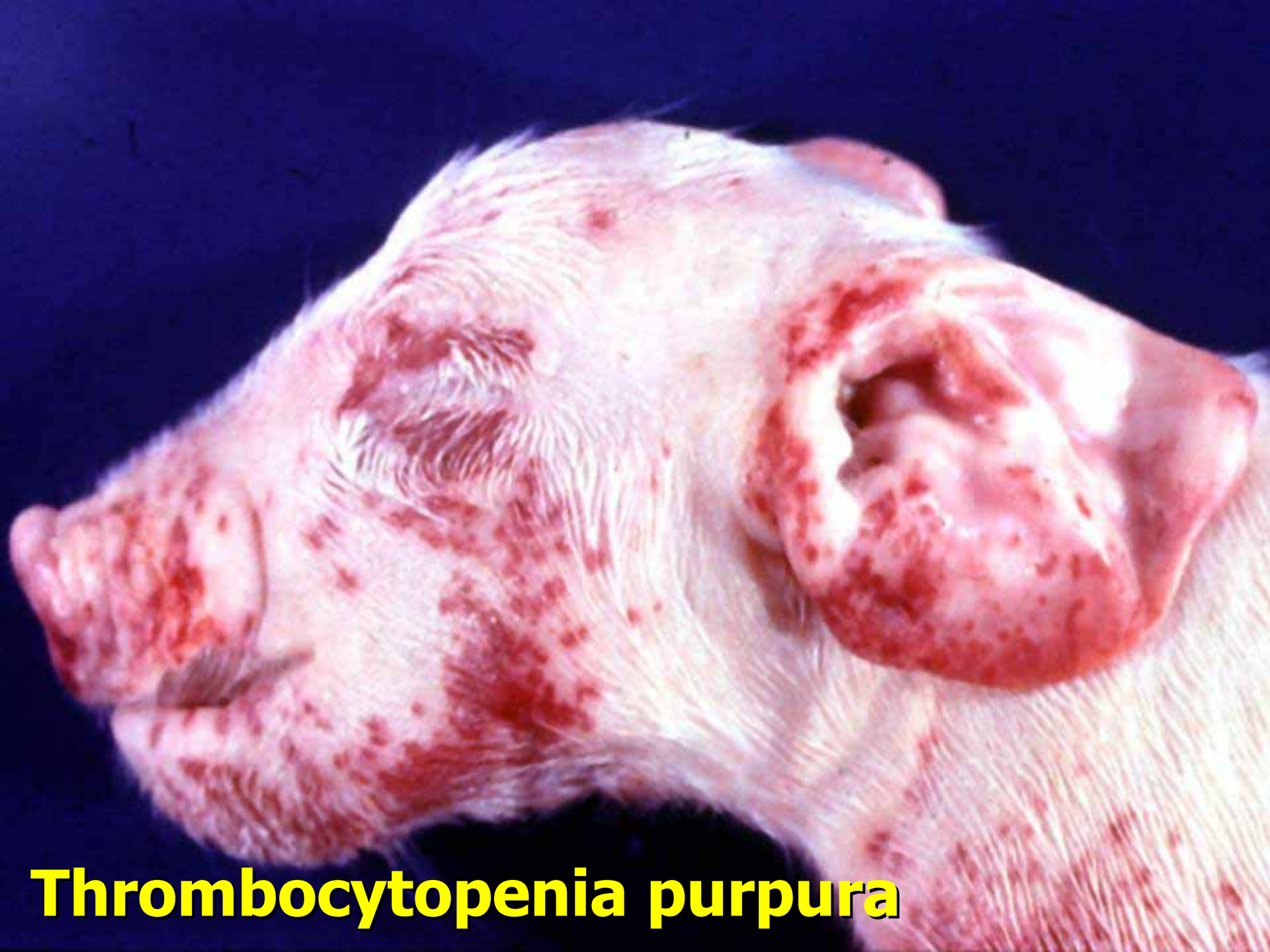**Porcine juvenile pustular psoriasiform dermatitis (Pityriasis rosea)**





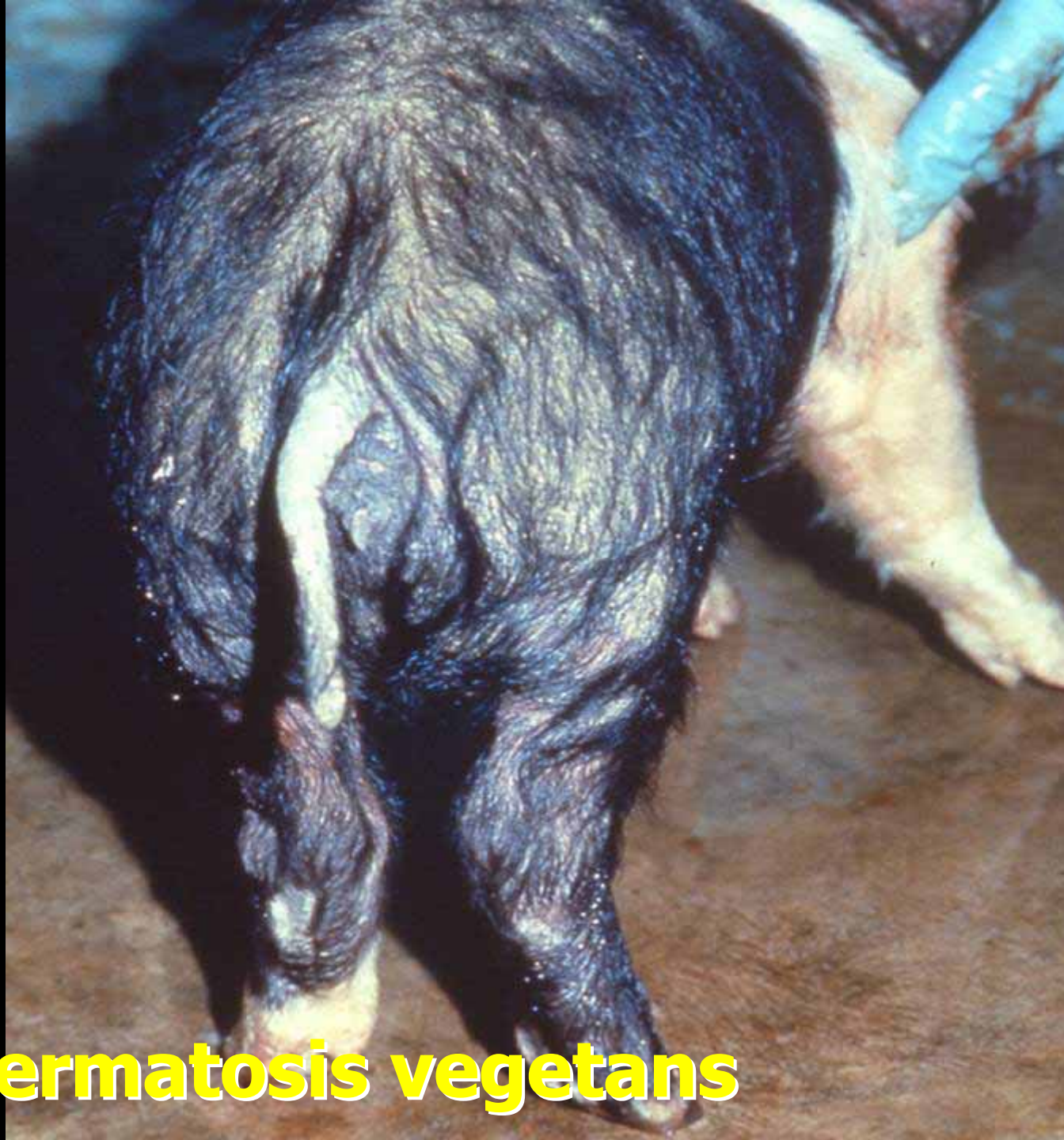**Thrombocytopenia purpura**





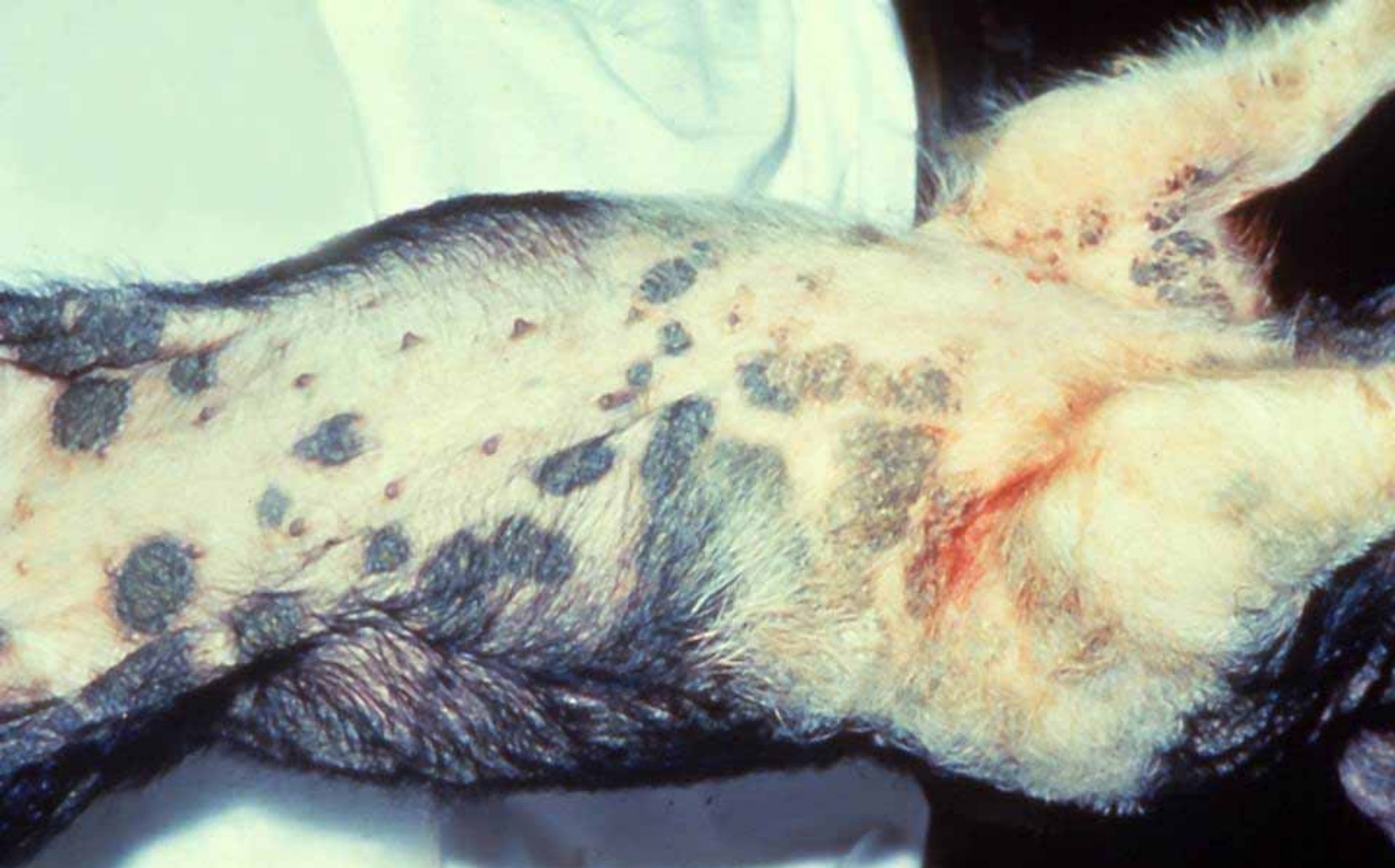**Thrombocytopenia purpura**





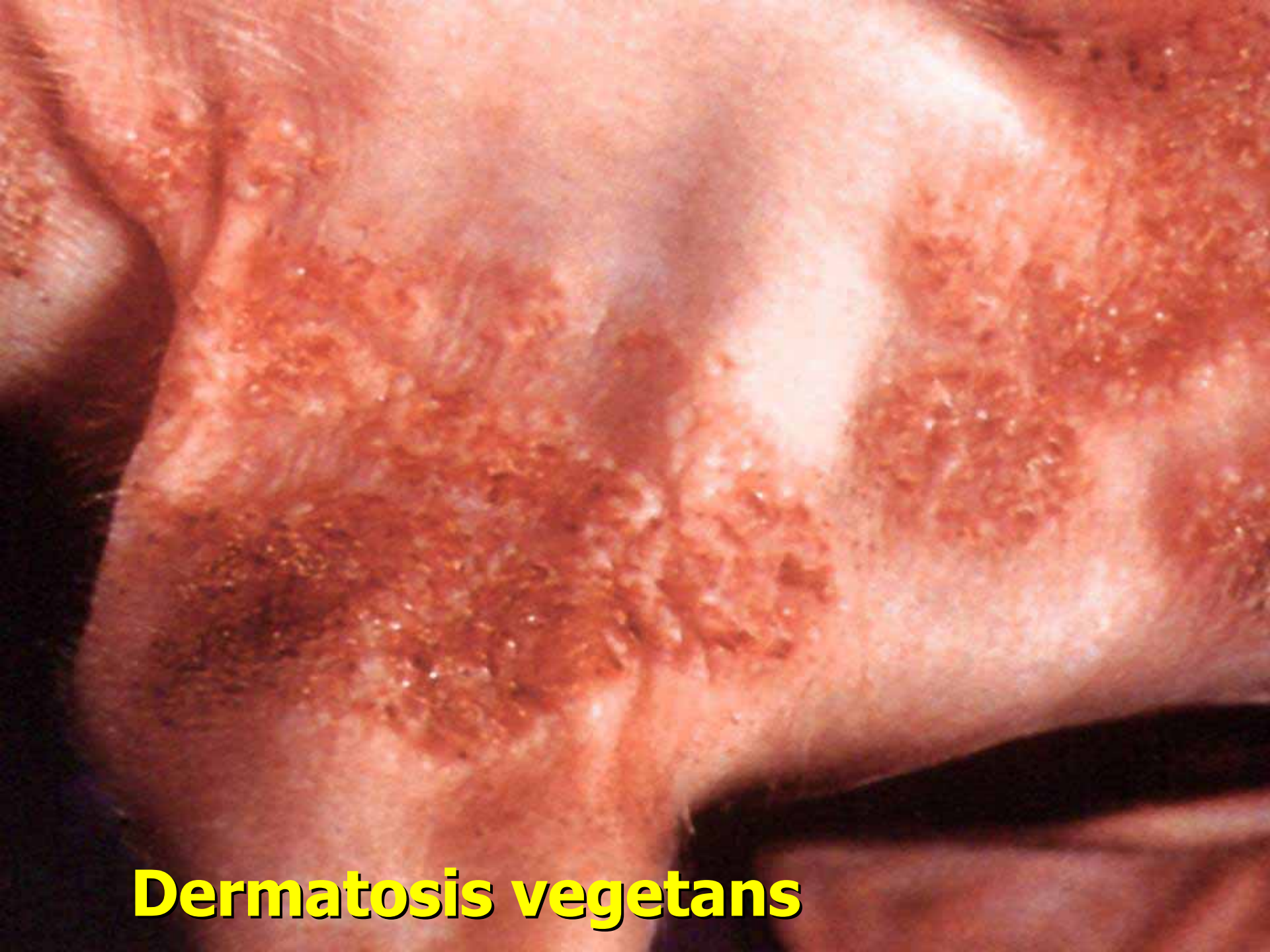**Dermatosis vegetans**





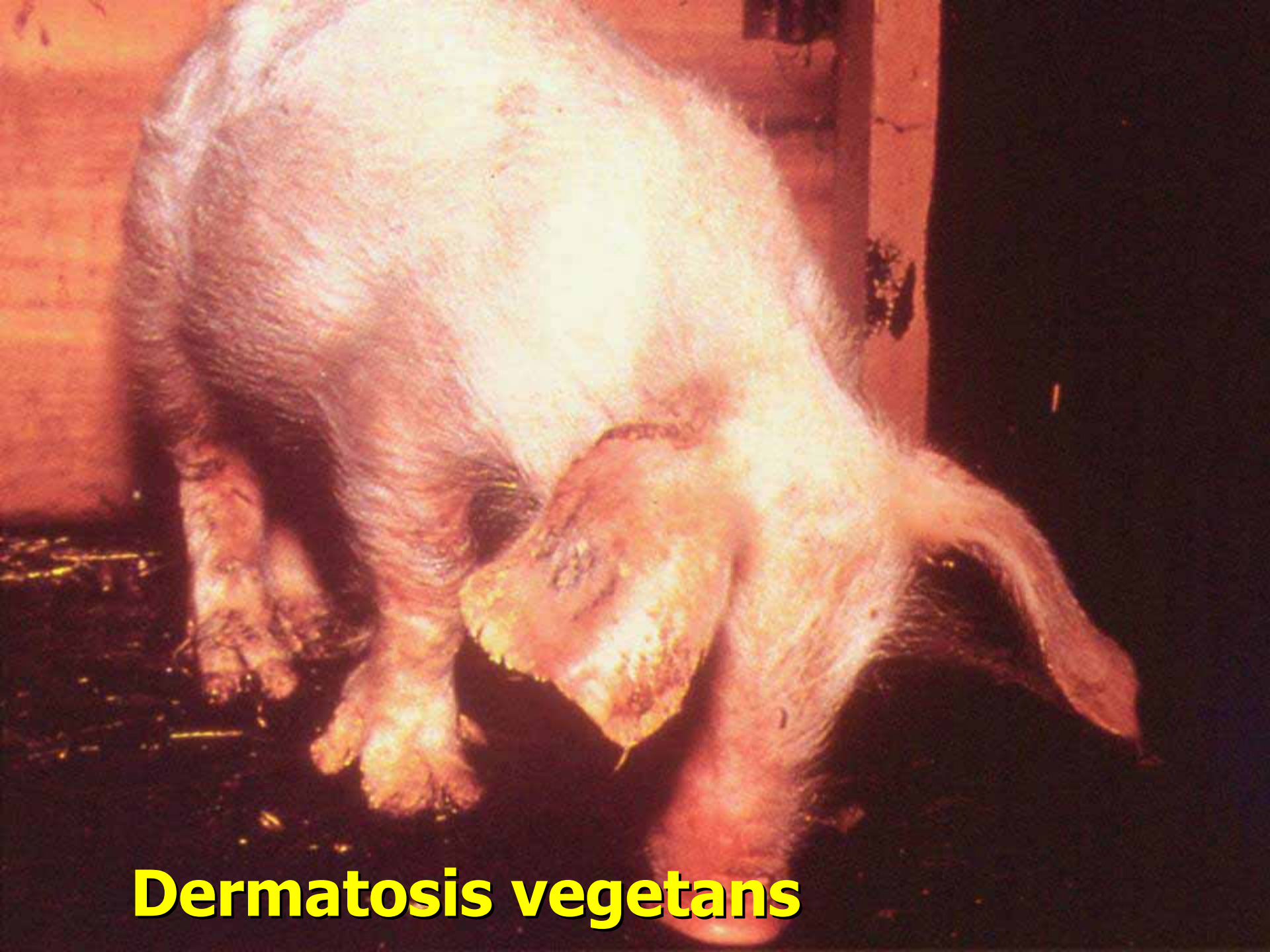**Dermatosis vegetans**





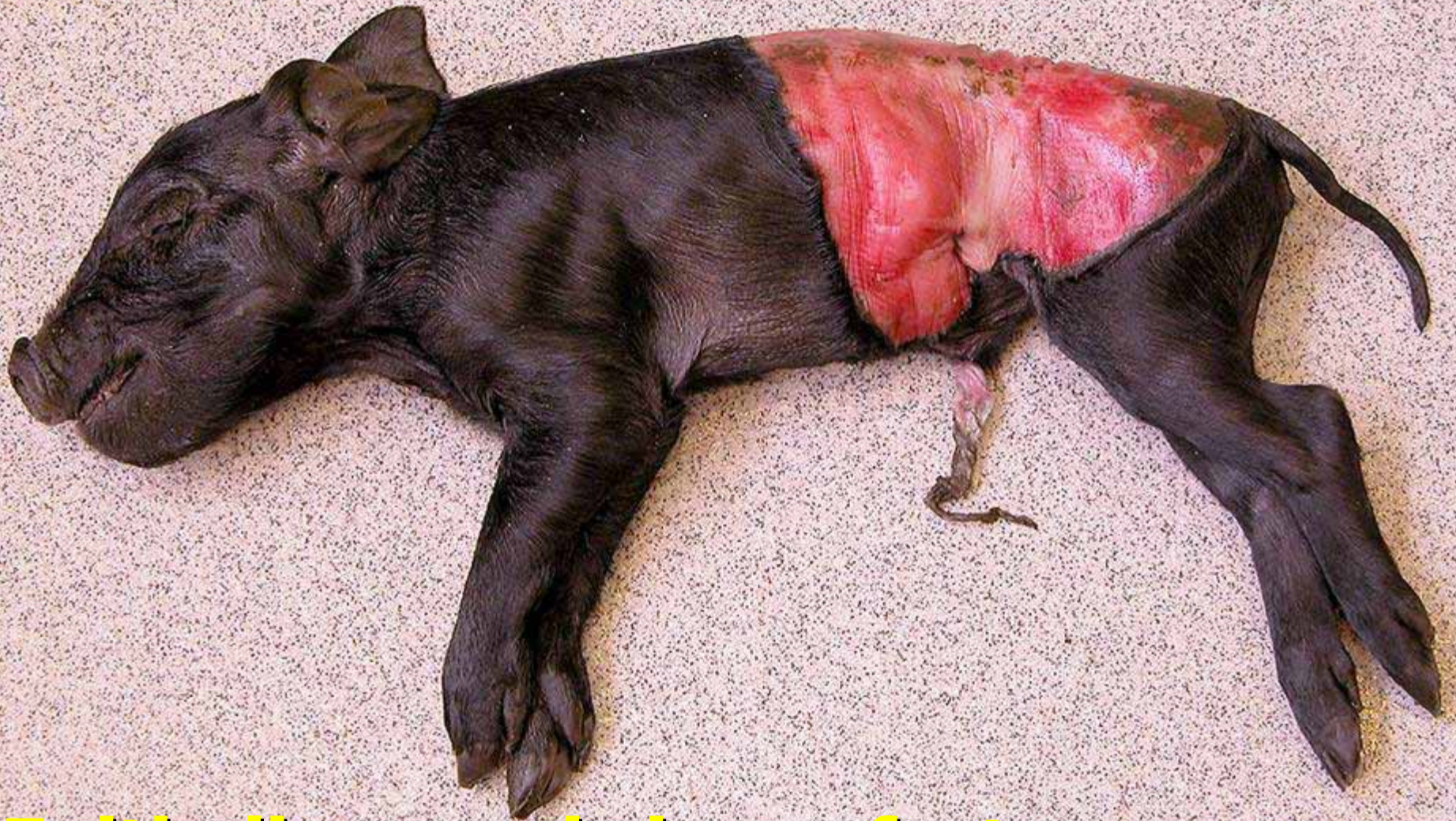**Dermatosis vegetans**





**Dermatitis vegetans**





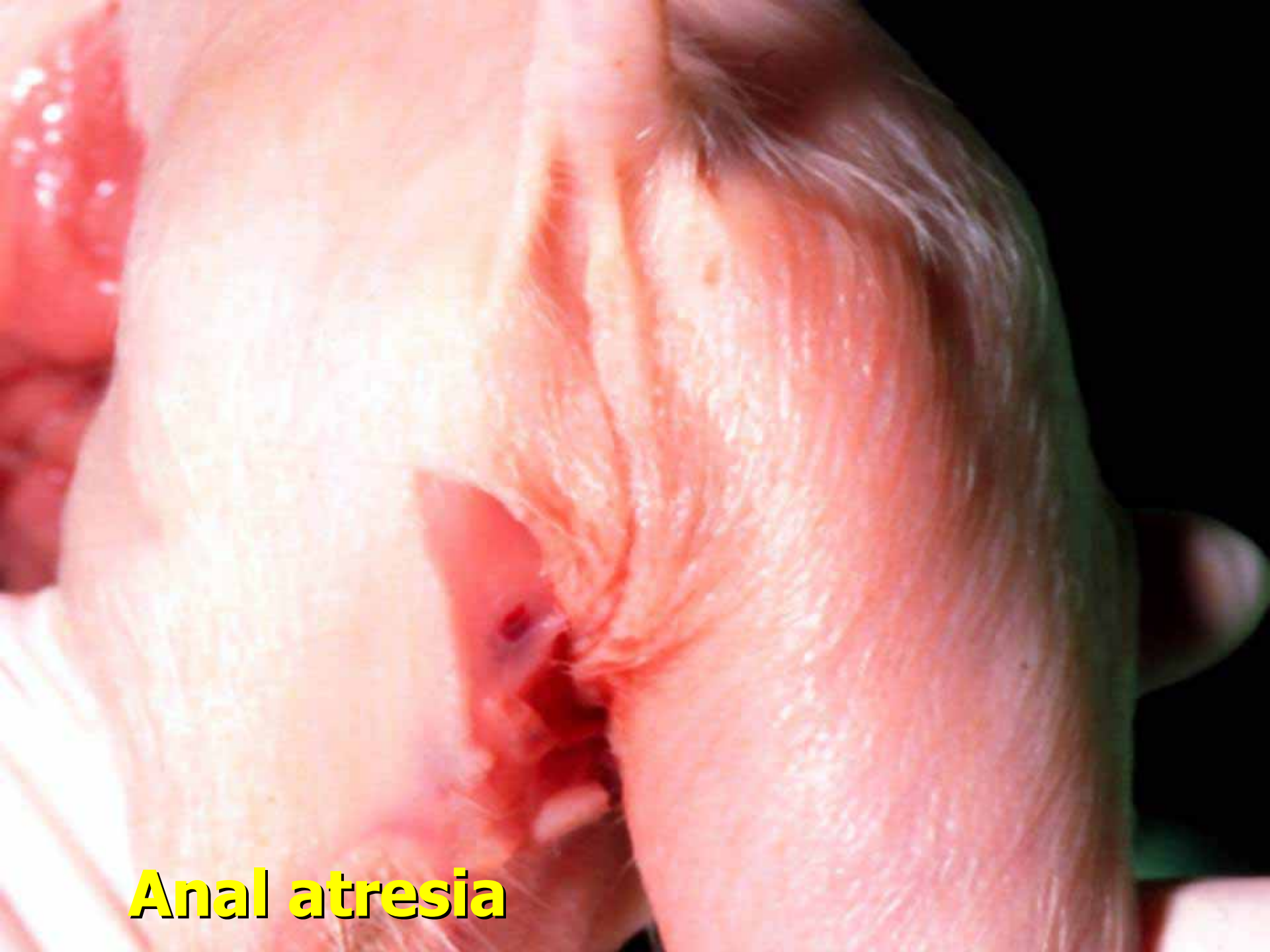**Epitheliogenesis imperfecta**





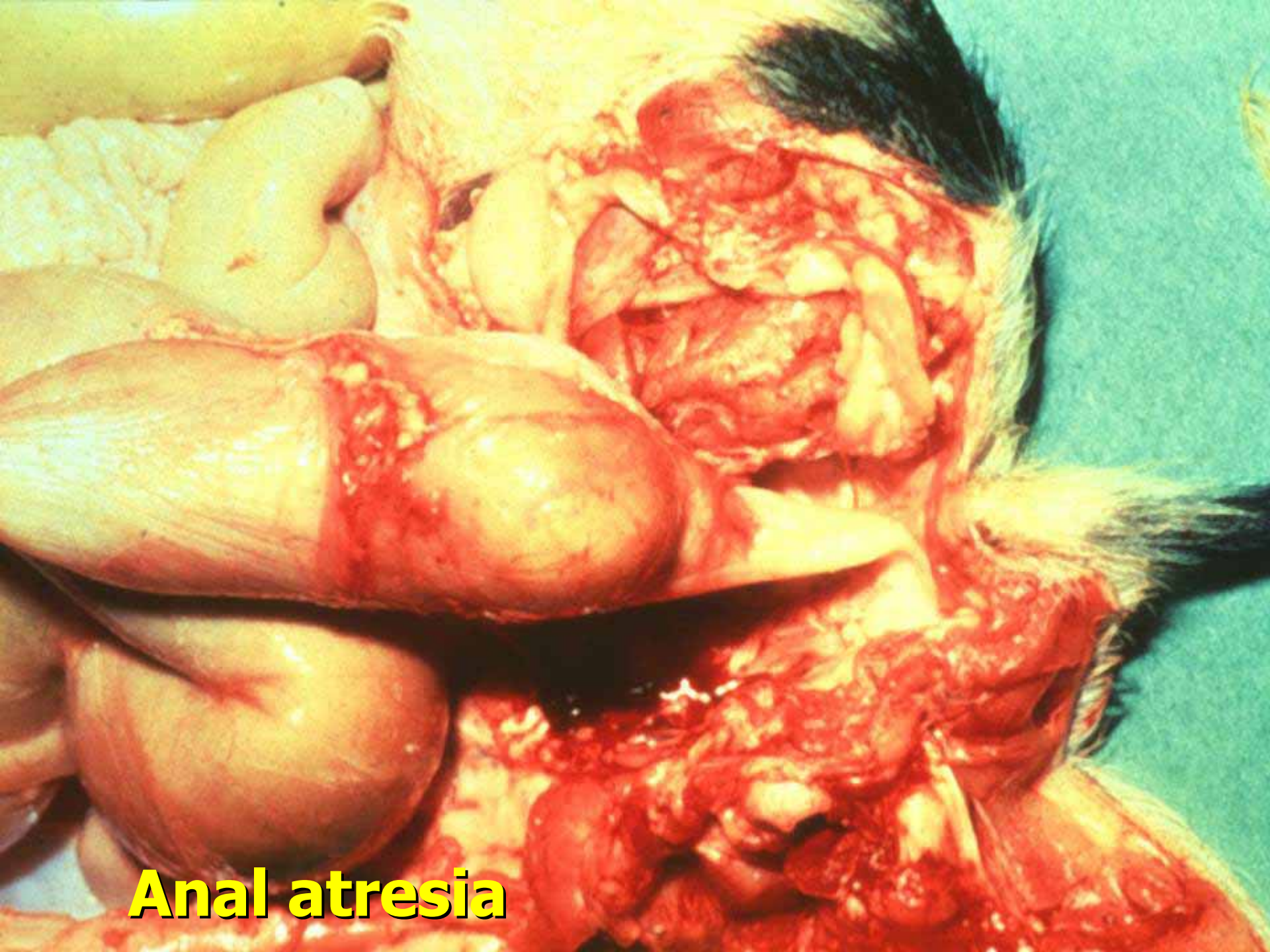**Syndactly**





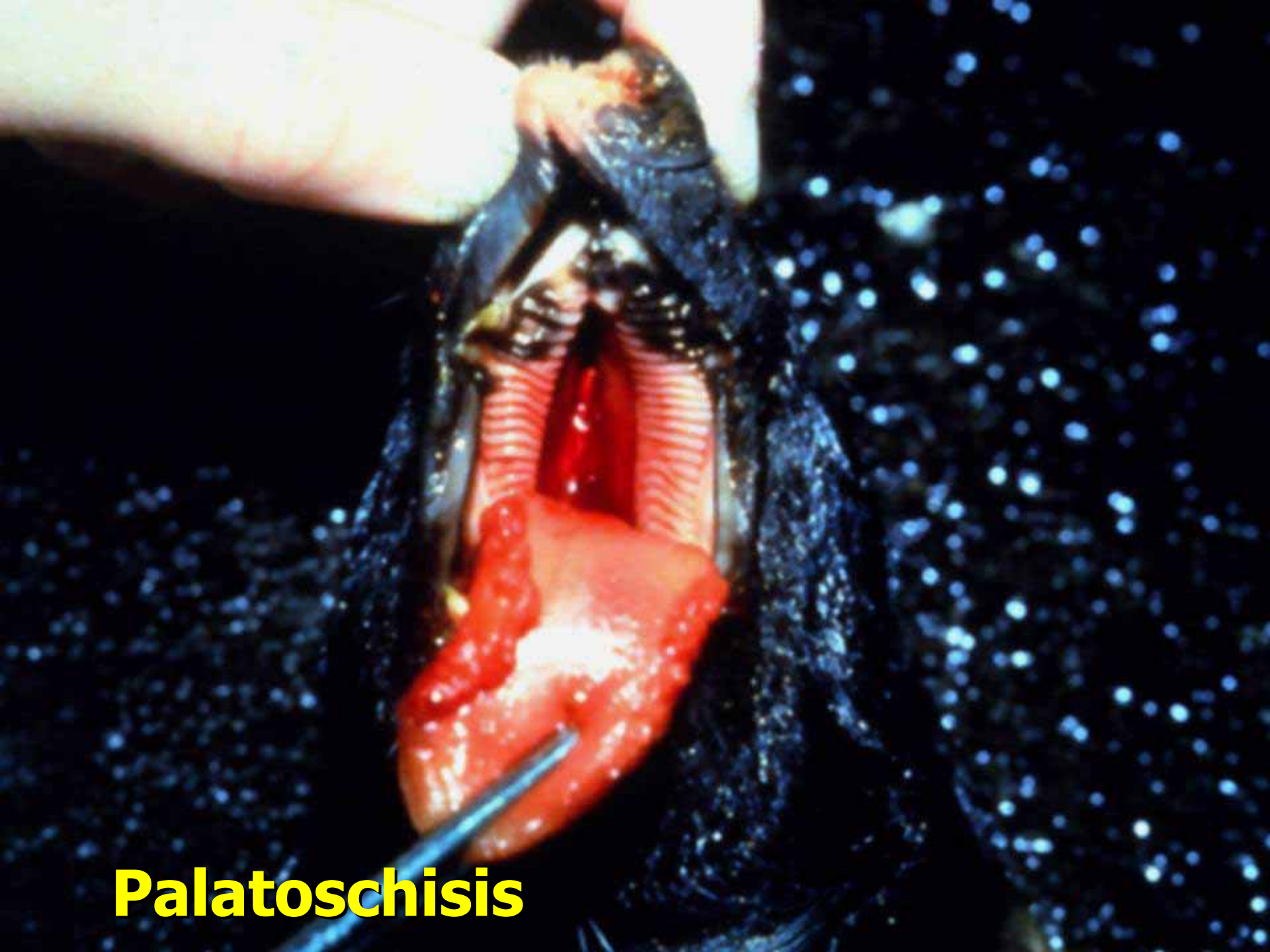**Anal atresia**





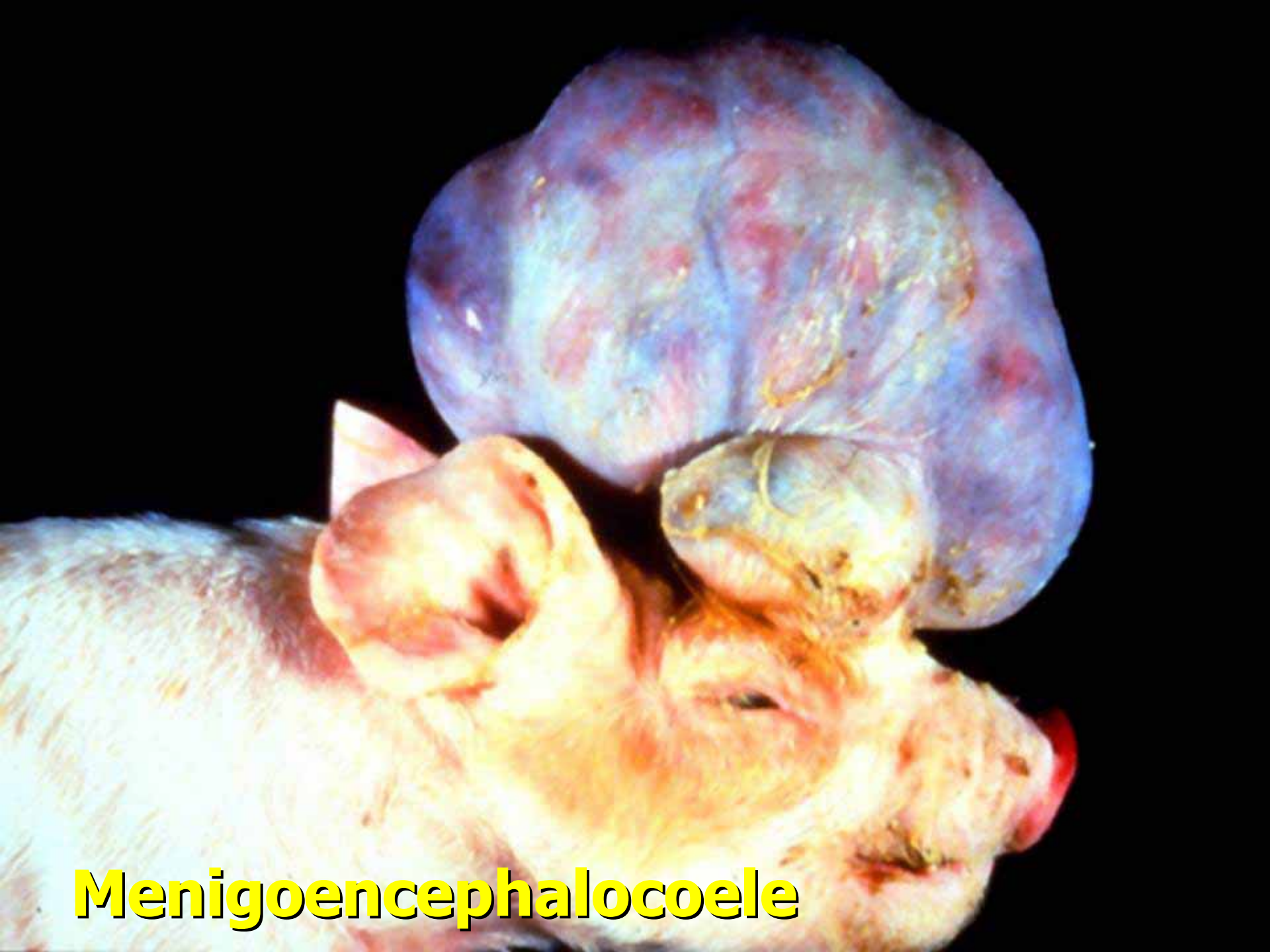**Anal atresia**





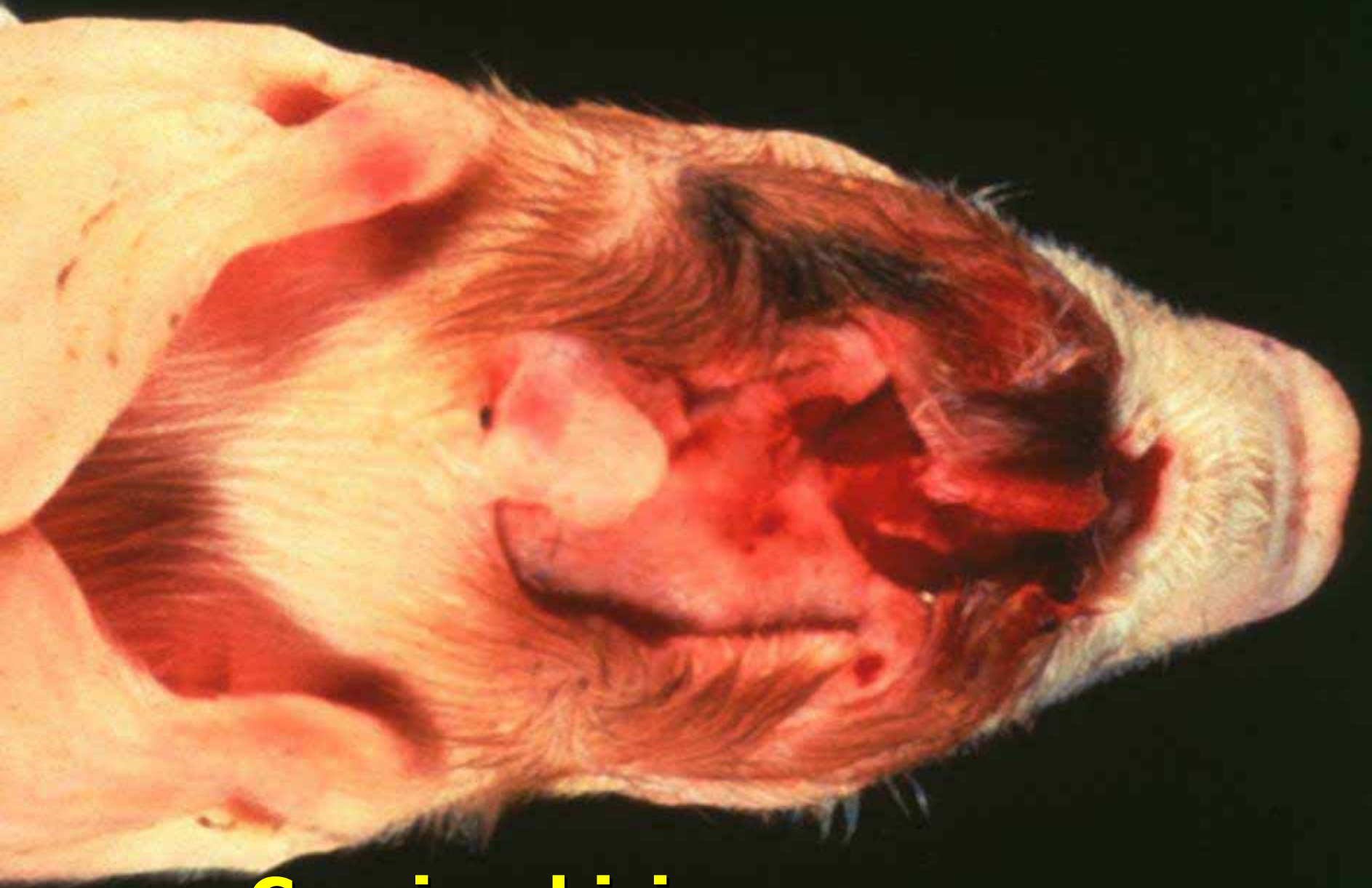**Palatoschisis**





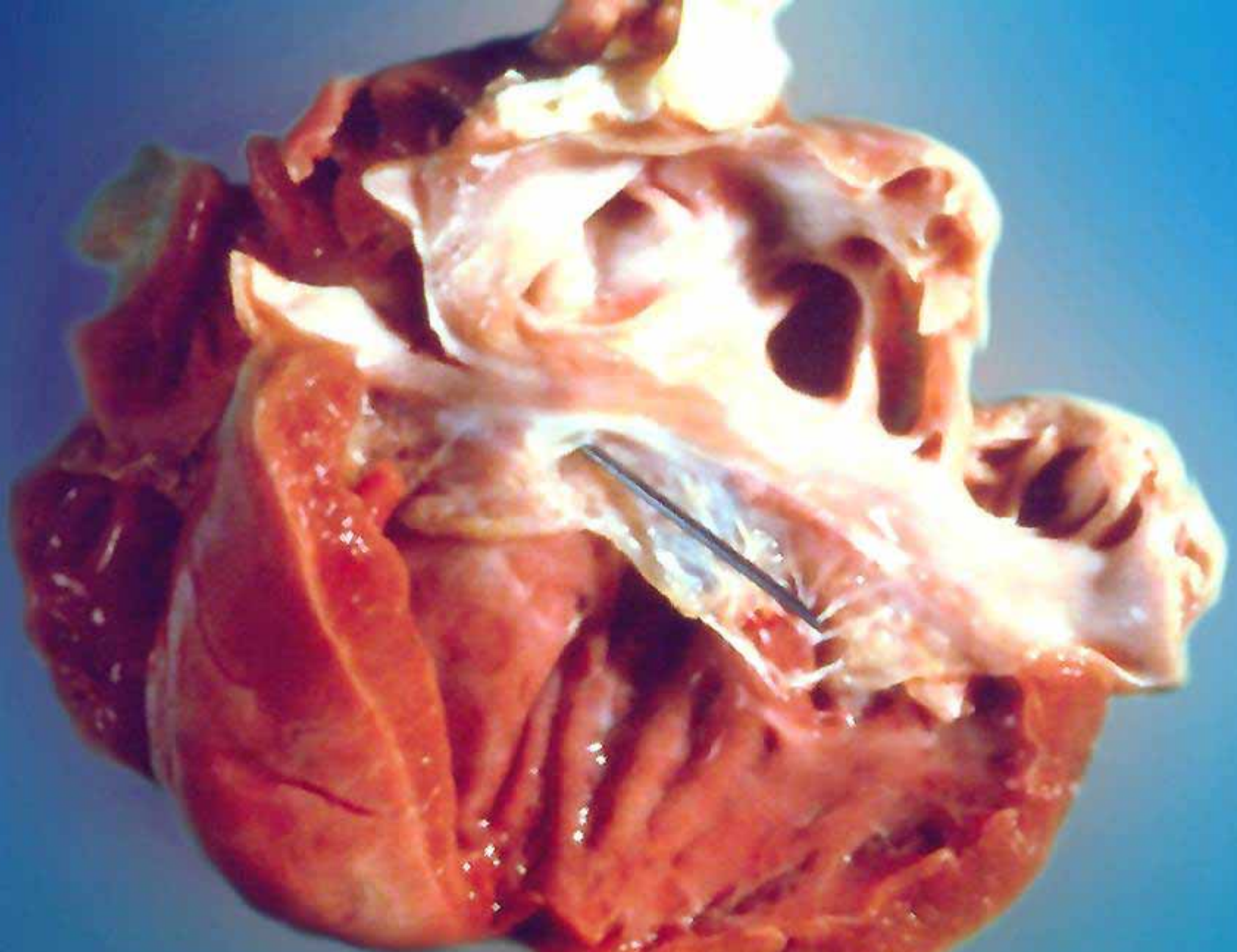
**Meningoencephalocoele**





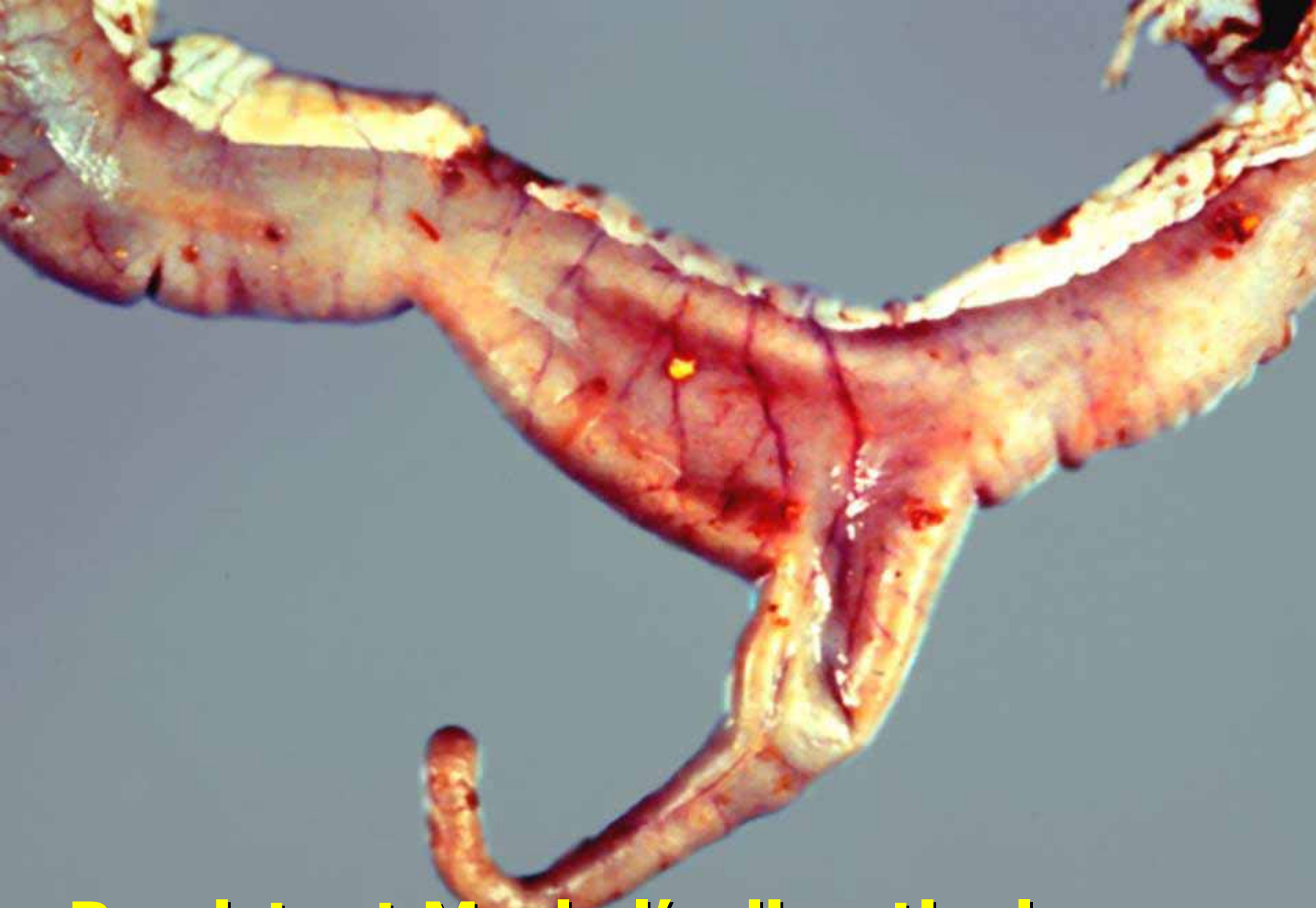**Cranioschisis**





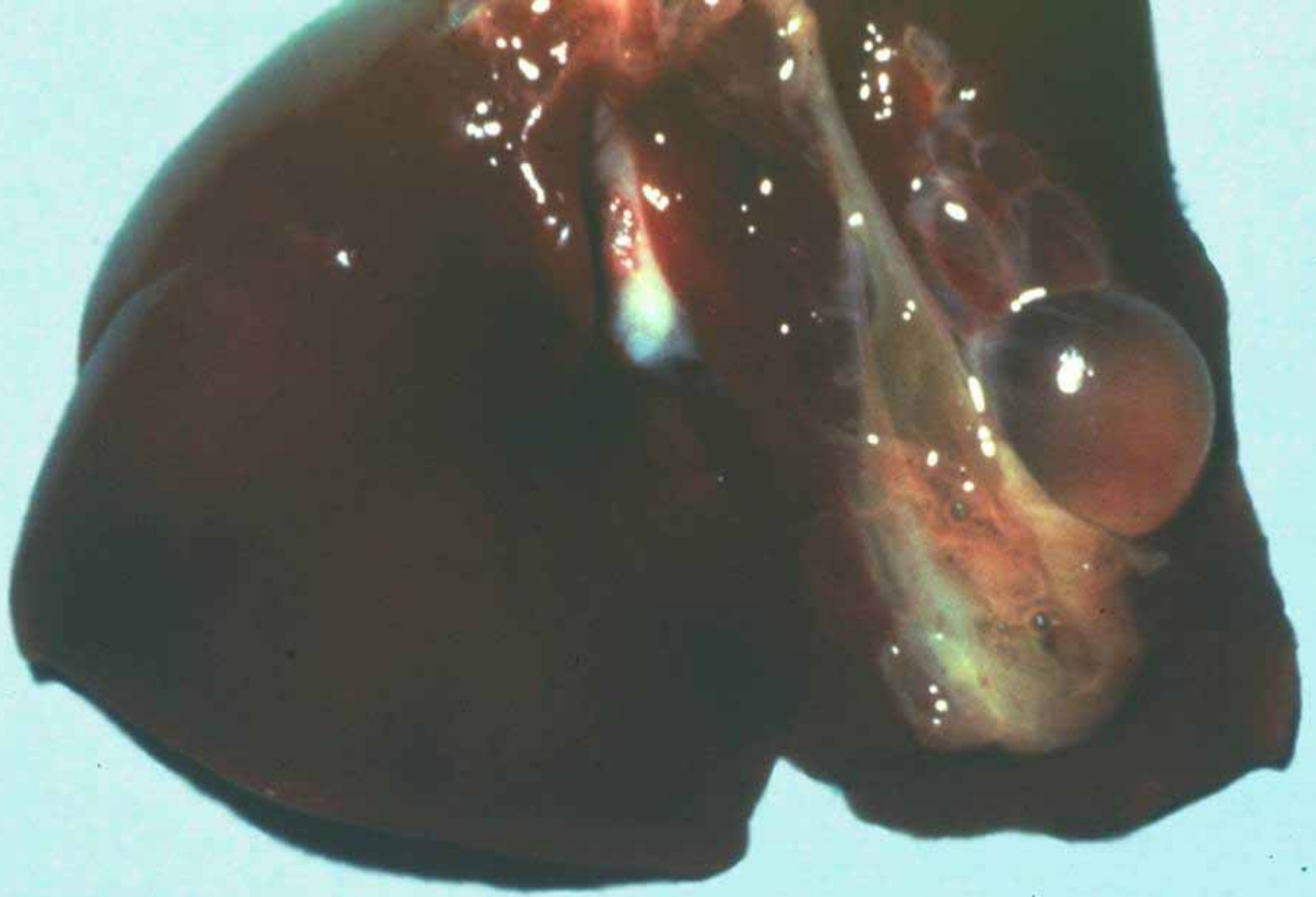**Ventricular septal defect**





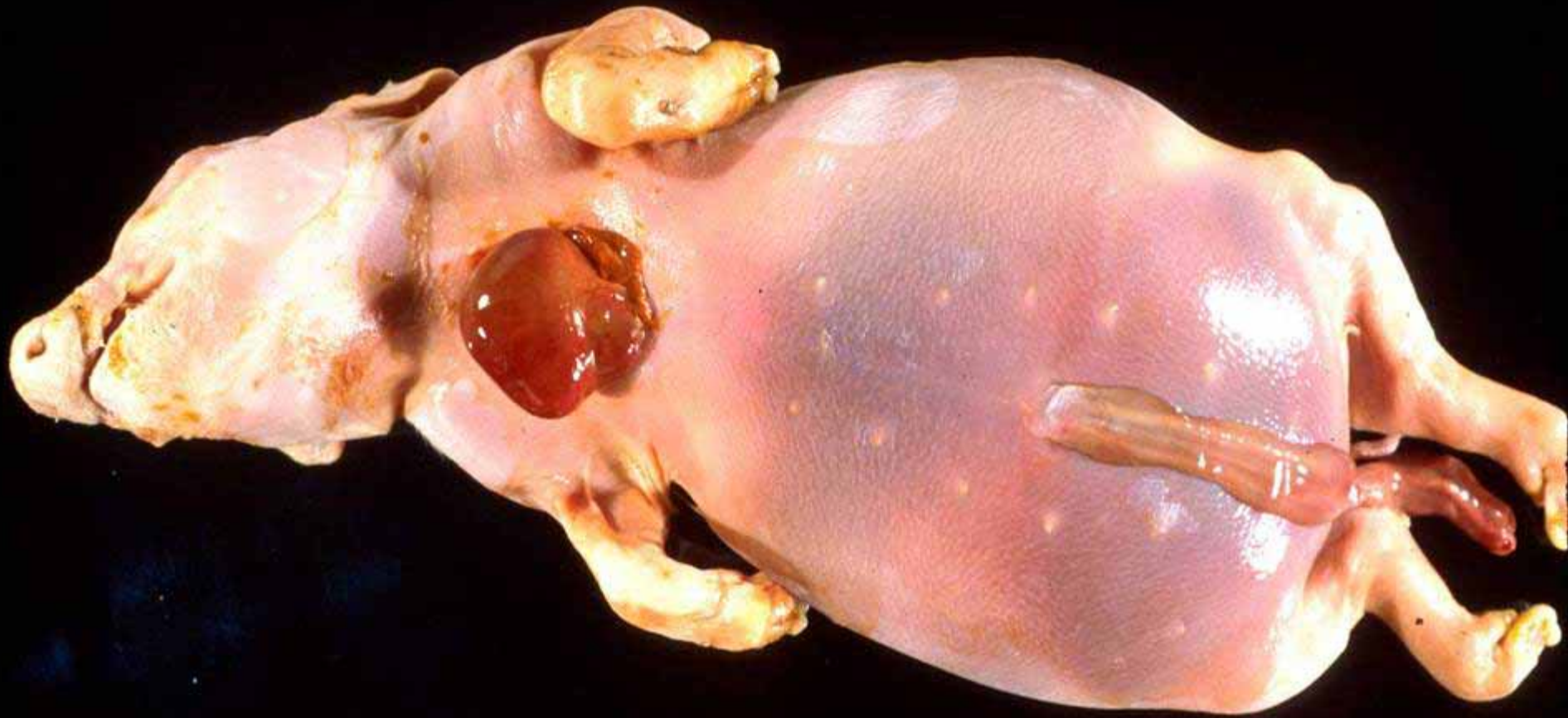**Persistent Meckel's diverticulum**





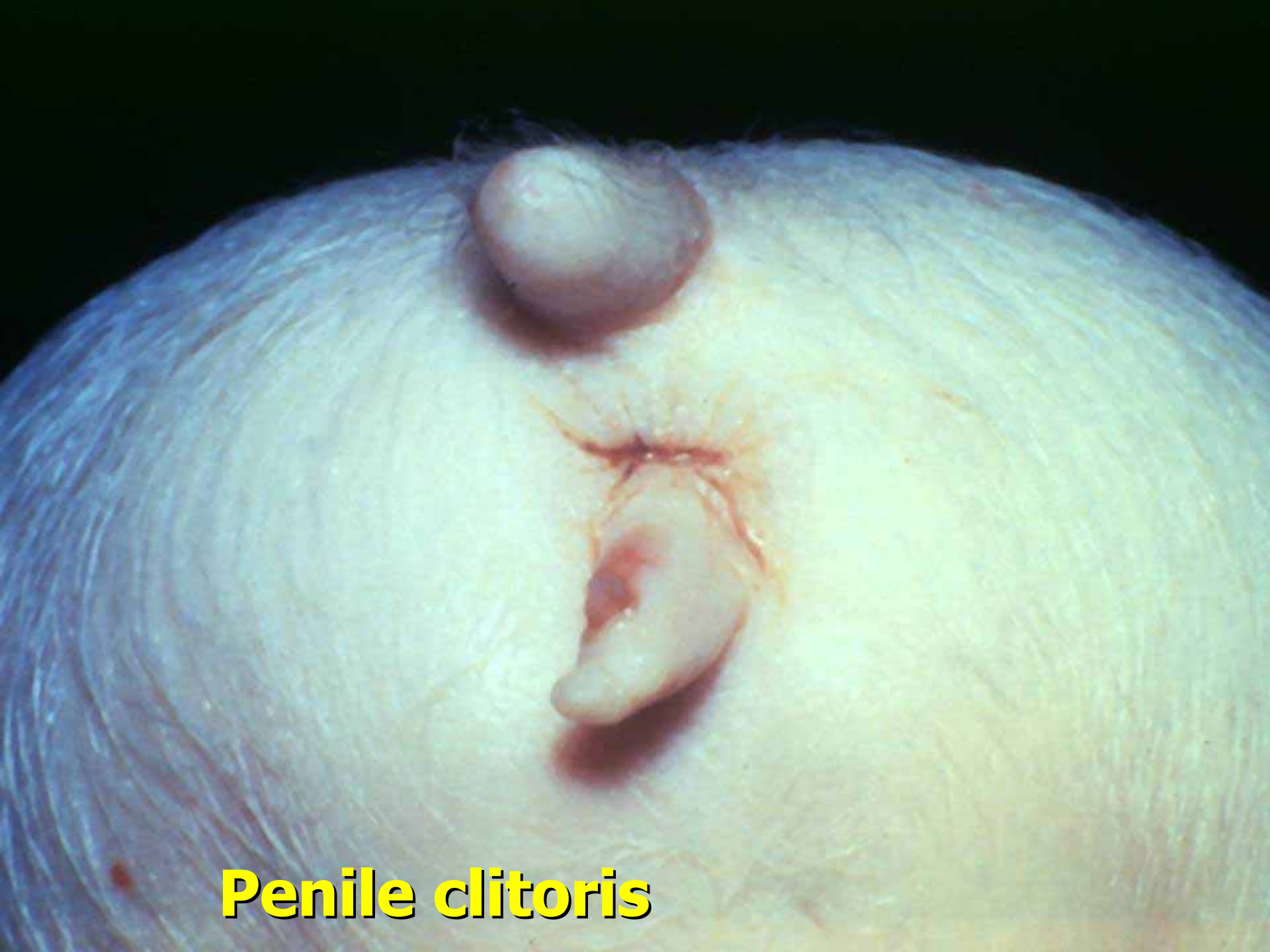**Biliary cyst**





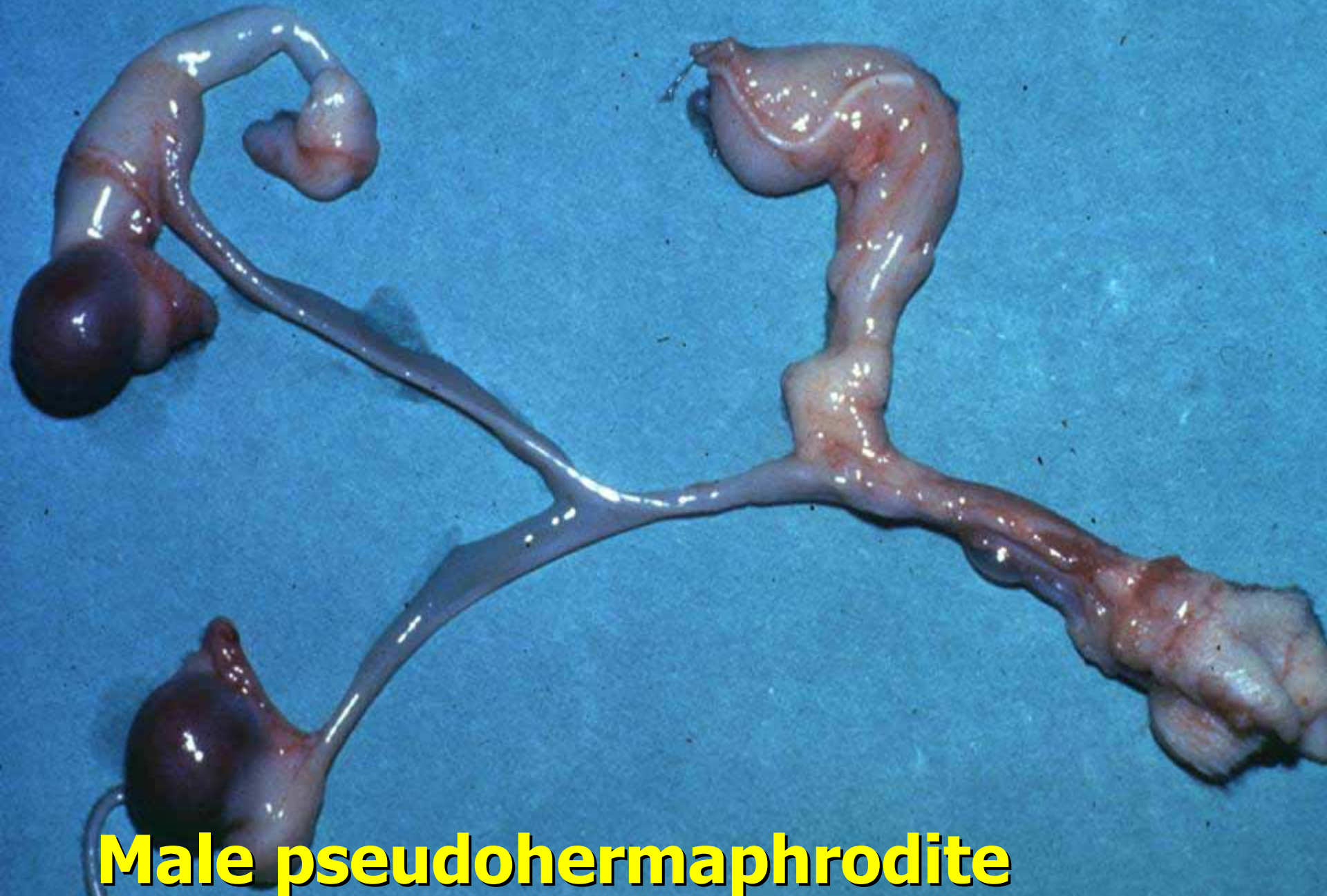
**Ectopia cordis**





**Penile clitoris**





**Male pseudohermaphrodite**