

ASVP DIAGNOSTIC EXERCISE No. 16

submitted by Fraser Hill
Gribbles Veterinary
Palmerston North, New Zealand

Clinical history

A 1-year-old Hereford cross heifer on a small lifestyle block was examined because of a single firm mass over the shoulder. Initially the mass was thought to be an abscess and was treated with long acting penicillin. Two weeks later multiple nodules had developed over the entire body (Figure 1). Fine needle aspirates and a biopsy were collected from the nodules. Nodules ranged in size from 6-20 cm diameter and were covered by a crusty ulcerated surface. On section the nodules contained firm, tan, glistening material (fig. 2). The heifer was killed and photographs taken following laboratory diagnosis.

Fig. 1.

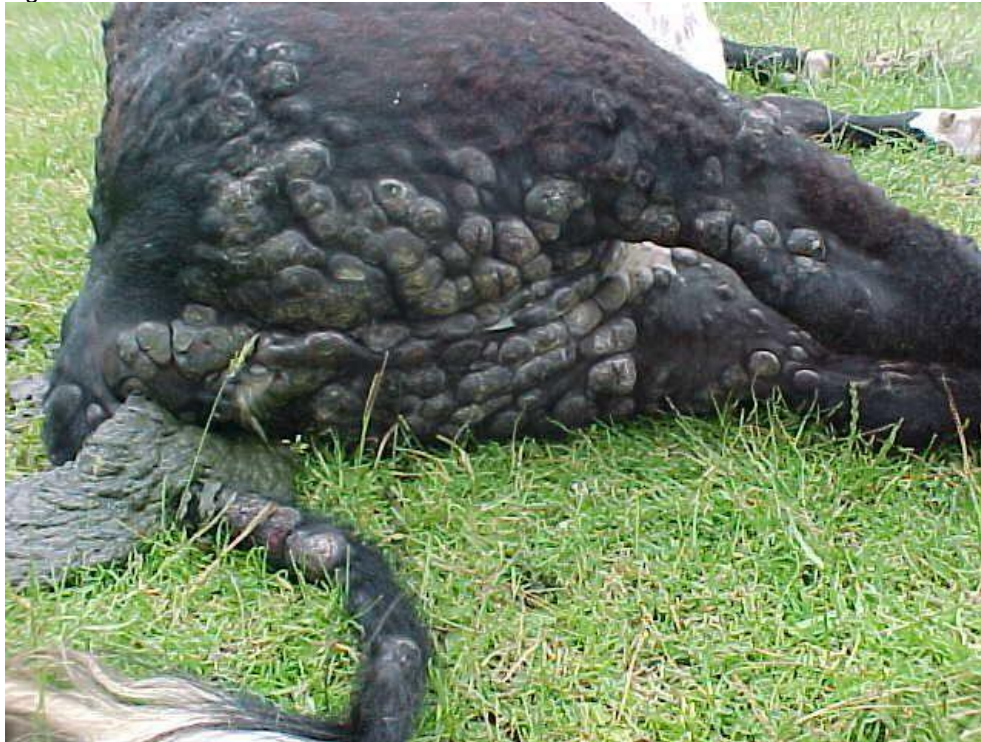
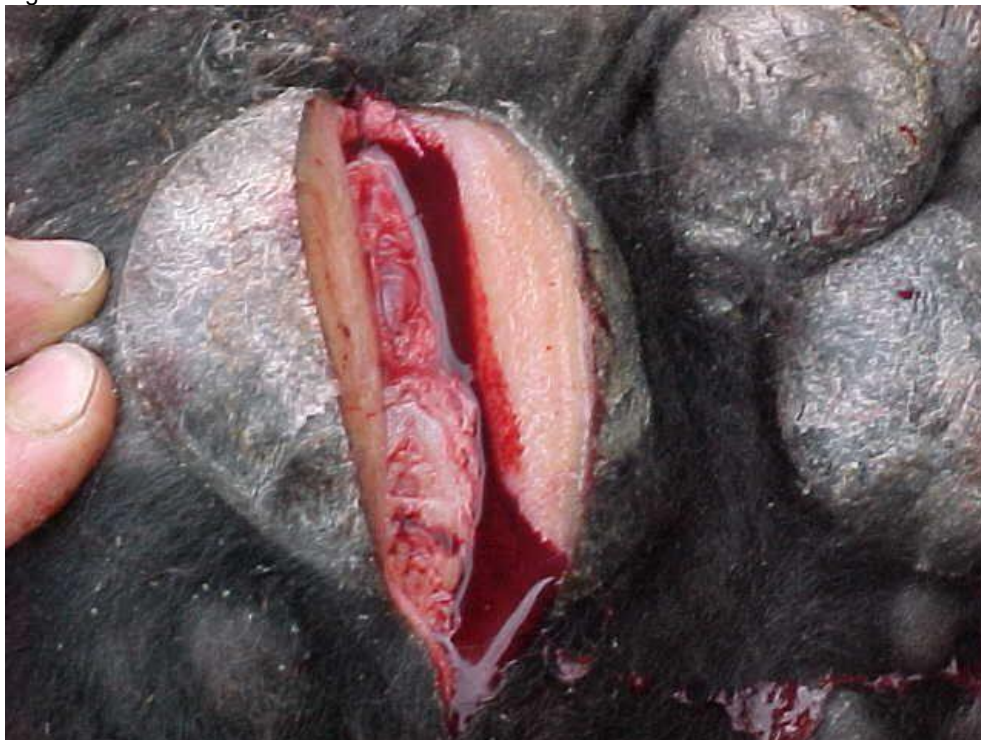
Fig. 2.



Laboratory findings

Fine needle aspirate cytology: there were low numbers of round cells in the smears. They were pleomorphic with deeply basophilic eccentric cytoplasm and round nuclei. Occasional bizarre mitotic figures were visible.

Biopsy histopathology

Sheets of neoplastic lymphocytes multifocally infiltrated the superficial dermis, epidermis and all adnexal structures (fig. 3). The neoplastic cells had moderate anisokaryosis and round to slightly indented nuclei. Nucleoli were prominent (fig. 4). There were up to five mitotic figures per hpf (40x). The epidermis was eroded and sometimes ulcerated, with multifocal serocellular crusts.

Fig. 3

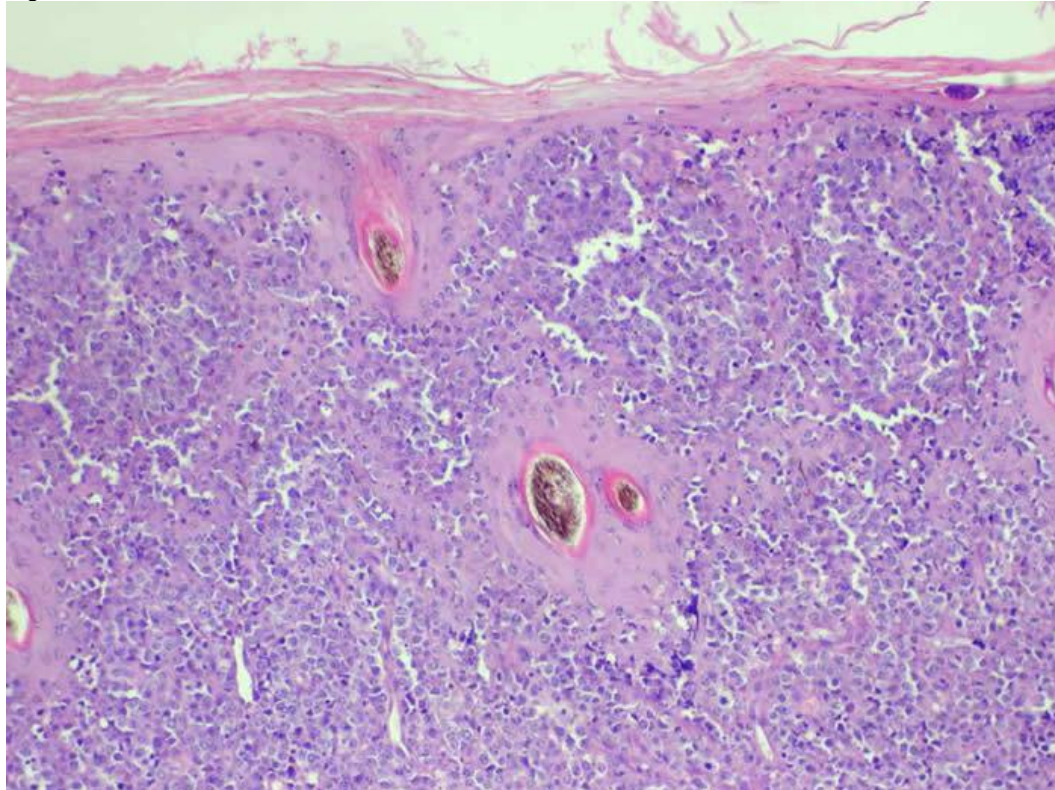
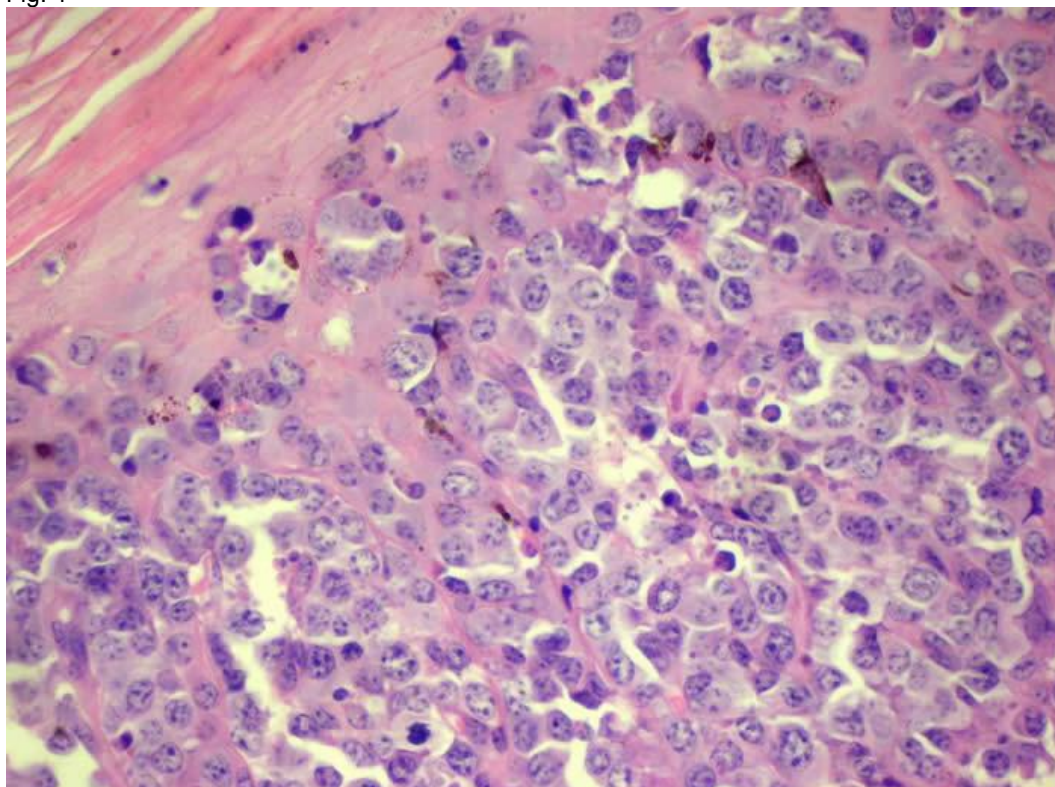


Fig. 4



Diagnosis

Cytology and histopathology findings supported a diagnosis of cutaneous lymphoma.

Discussion

Cutaneous lymphoma is a less common form of lymphoma and not EBL- associated. The course can wax and wane for months before developing node and visceral involvement late in the course of disease. Affected animals are usually less than 3 years old. Lesions in this heifer developed extremely rapidly, indicating euthanasia.

A similar case "Disseminated lymphosarcoma in a heifer with sporadic bovine leucosis" is reported in The Australian Cattle Veterinarian by MJ Deppeler, PJ Dorsett, J. Sandy and PD Mansell 35:8-12 (2005), together with a review of the condition.