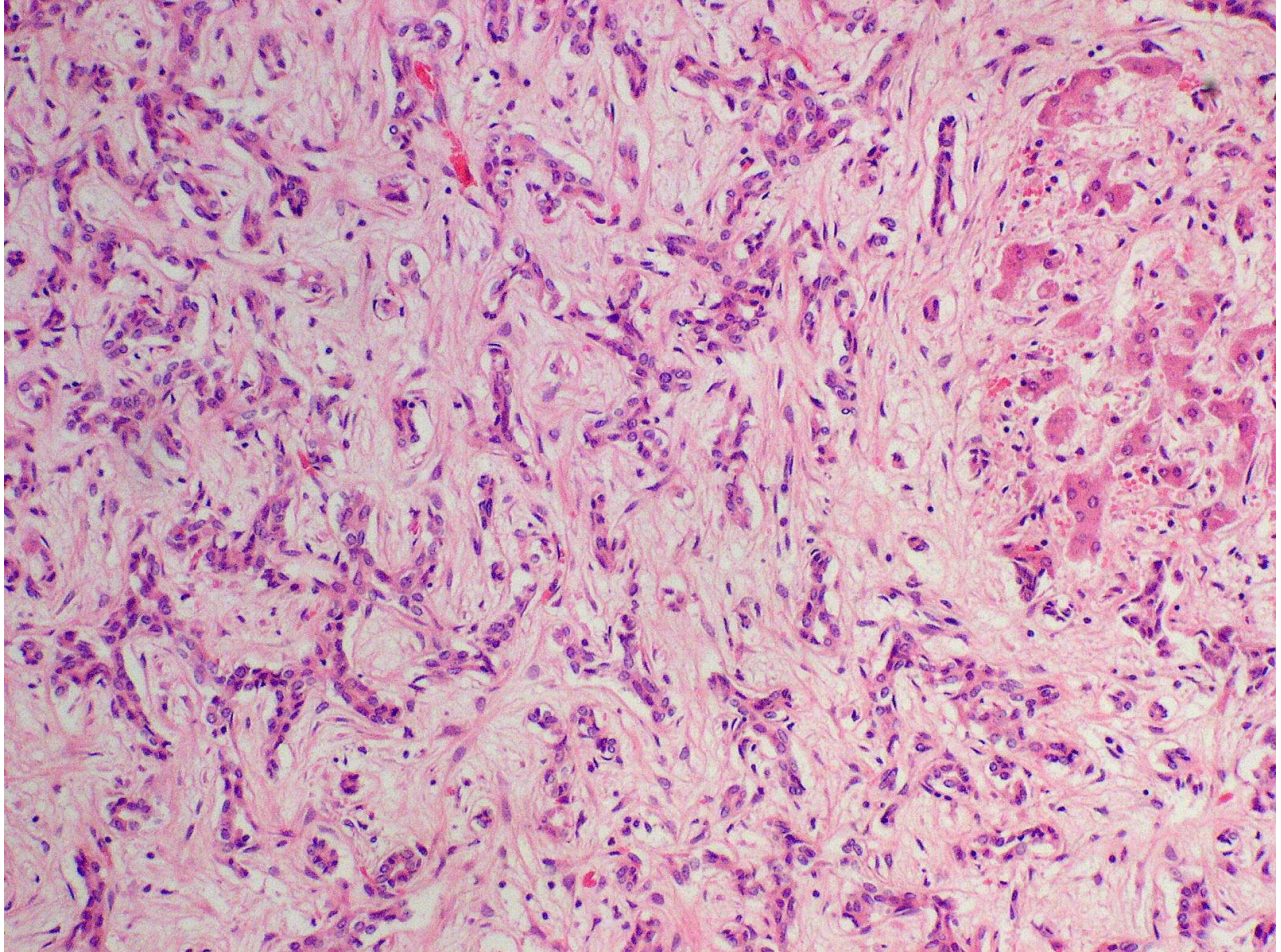


ASVP DIAGNOSTIC EXERCISE NO. 32

Fraser Hill
Gribbles Veterinary
Palmerston North 4440

History:

A 3-year-old female alpaca had been imported as a yearling from Australia to New Zealand to an alpaca stud in Northern Taranaki [location map see <http://en.wikipedia.org/wiki/Onaero>]. The stud is composed of 30 females and 9 males. This animal had developed peeling skin on nose and ears each autumn for the last 2 years. Skin lesions eventually resolved but the alpaca became progressively thinner. In August 2009 the alpaca was circling and showing nervous signs; it was dead by the time the veterinarian arrived. At field necropsy the carcass was in poor condition with few fat reserves, and the liver was described as firm, pale, scarred, and shrunken.



1. Describe the changes present.
2. Suggest the aetiology.

As with previous exercises, I will circulate a description and discussion of this case in a couple of weeks, *via* the Members login pages of the ASVP website <http://www.asvp.asn.au/>

Please advise me at roger-kelly@aapt.net.au or Fraser Hill at fraser.hill@gribbles.co.nz if you have any discussion about this case.