



# Reproductive Pathology

## What is new?

Rob Foster

Department of Pathobiology

[rfoster@uoguelph.ca](mailto:rfoster@uoguelph.ca)

[www.uoguelph.ca/~rfoster](http://www.uoguelph.ca/~rfoster)





# Female Genital Pathology



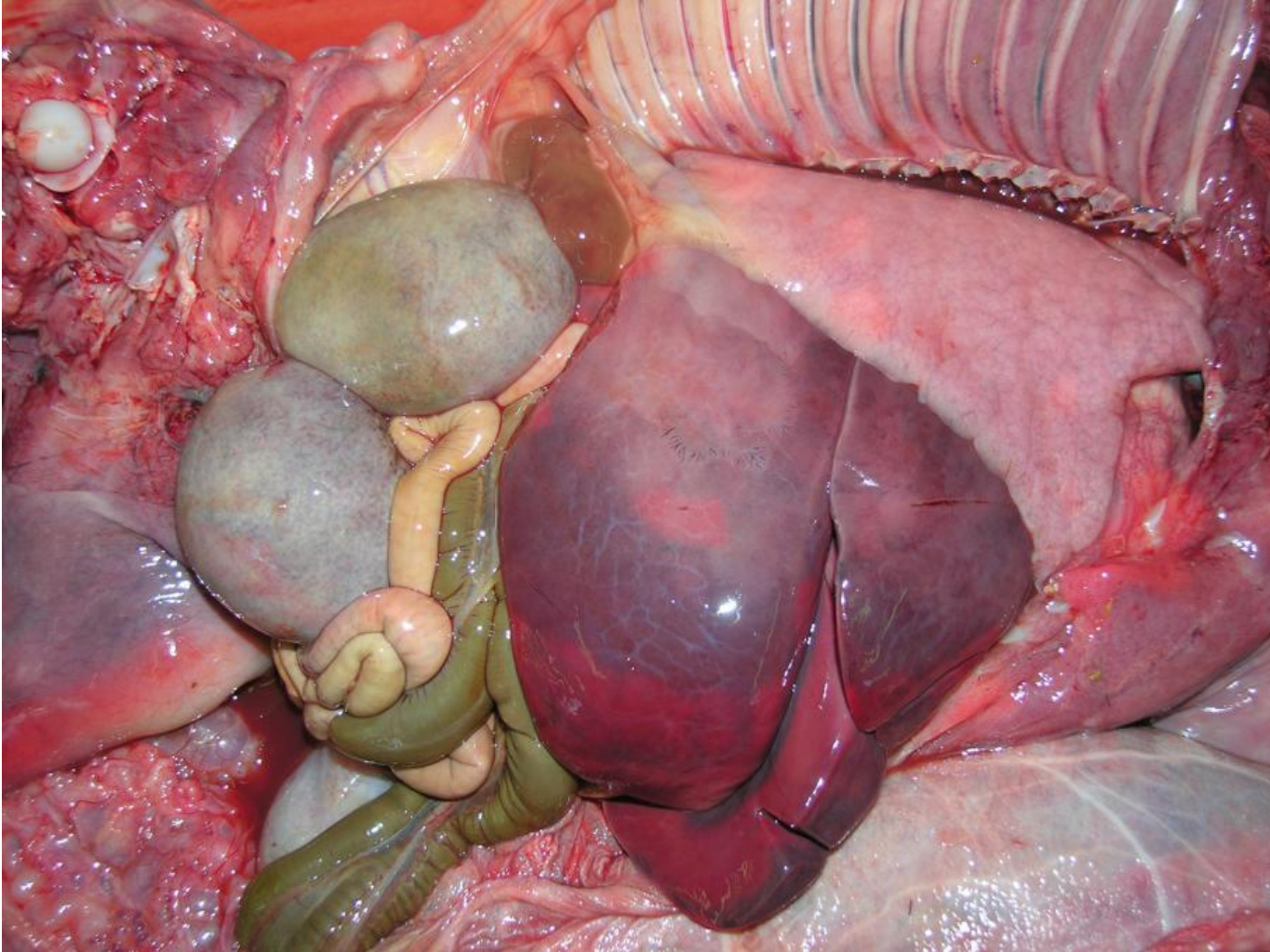


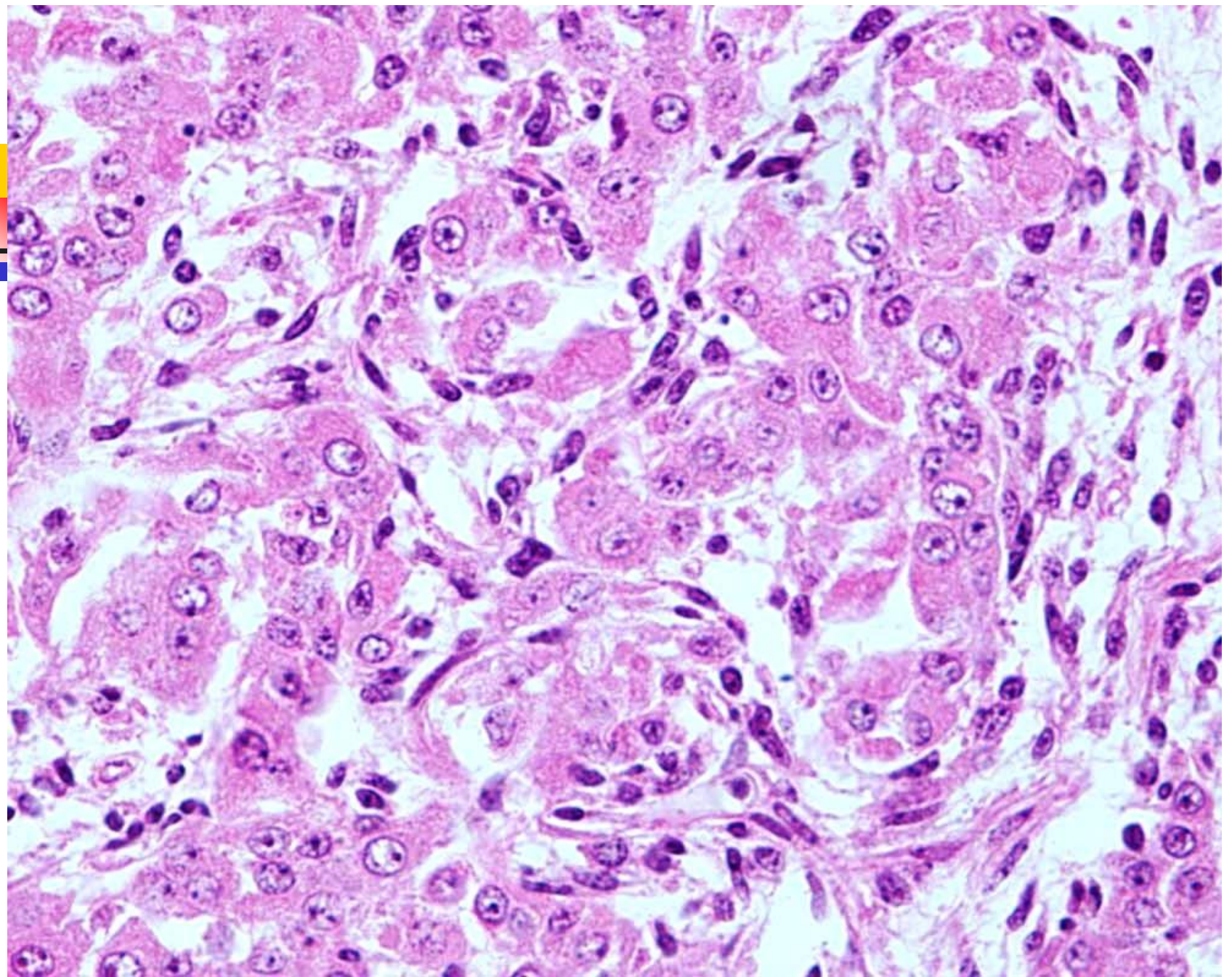
# Ovaries of the (night)mare

---

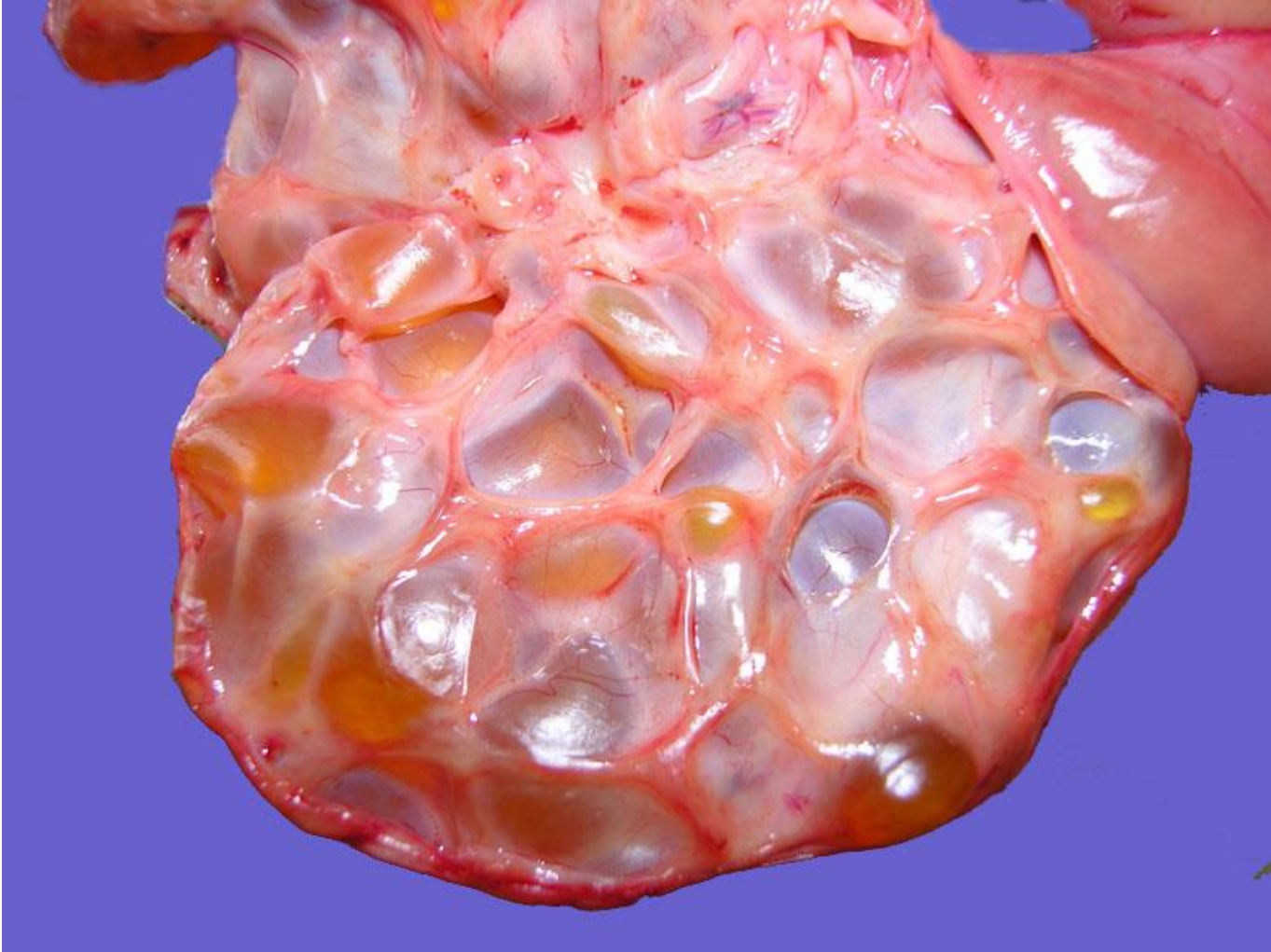
- Hydatid of Morgagni
- Inclusion cysts
- Anovulatory follicles
- Haemorrhagic anovulatory follicles
- Normal follicles and haemorrhage
- Single large cyst
- Cystic Sex Cord Stromal Tumour  
(granulosa cell tumour)

# Gonadal hypertrophy





# Anovulatory follicles



# Haemorrhagic anovulatory follicles

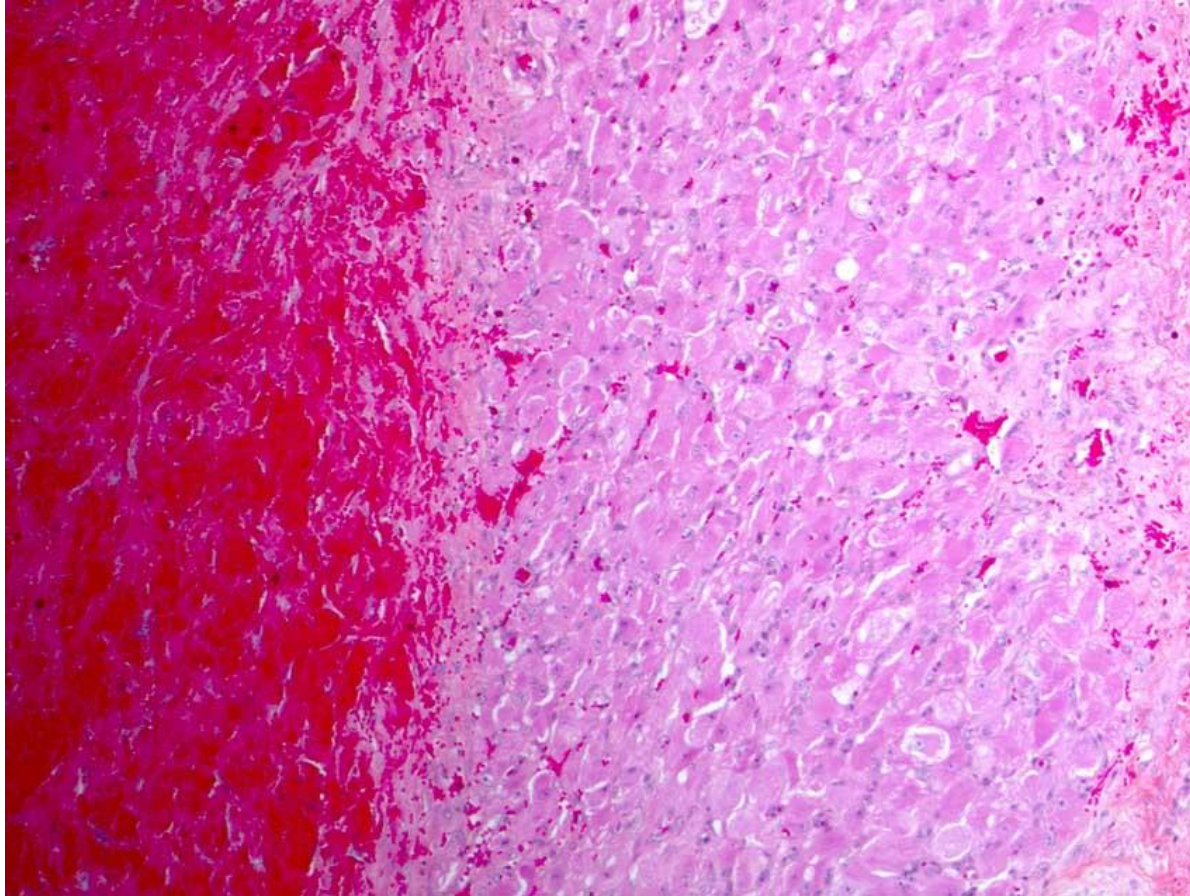
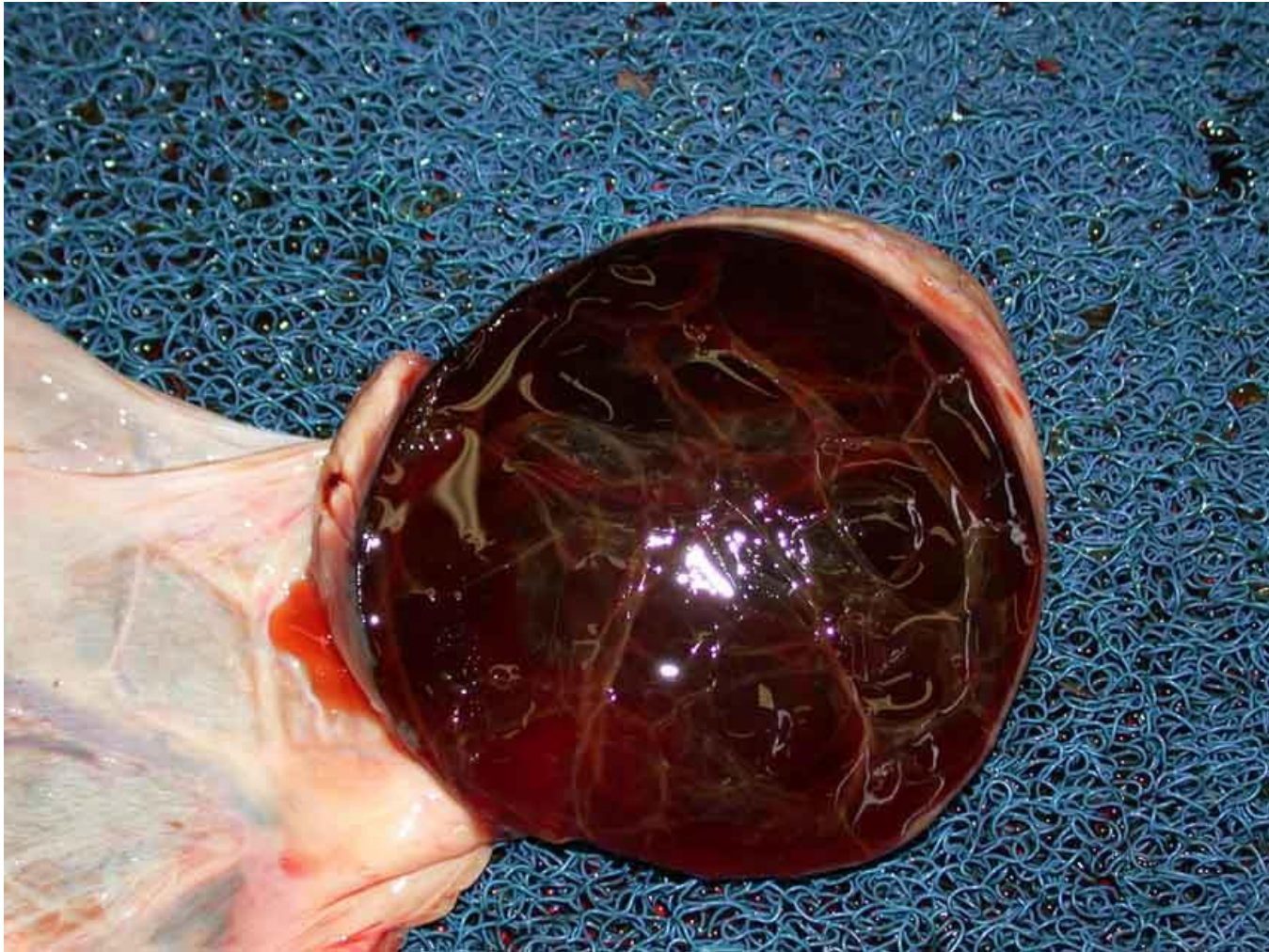

Photo compliments  
of Monique Dore,  
Universite de  
Montreal

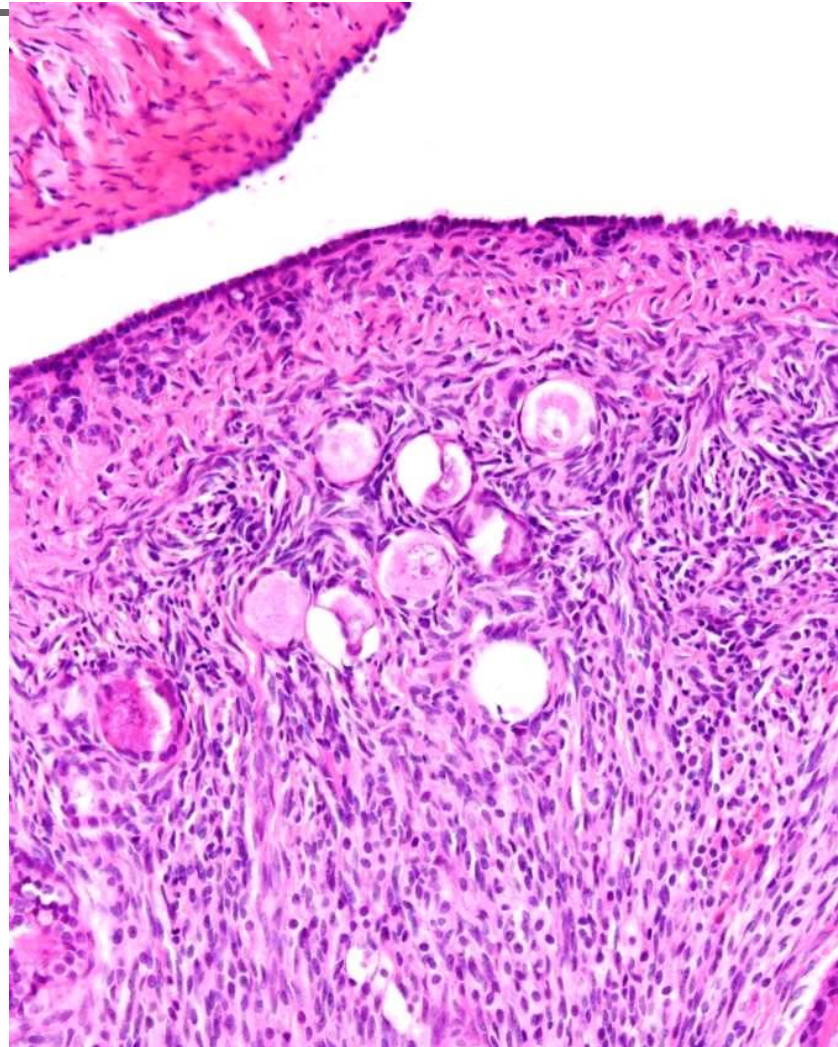
Ellenberger C, Müller K, Schoon HA, Wilsher S, Allen WR. (2009) Histological and immunohistochemical characterization of equine anovulatory haemorrhagic follicles (AHFs). *Reproduction in Domestic Animals* 2009, 44(3): 395–405

# Ovarian haemorrhage

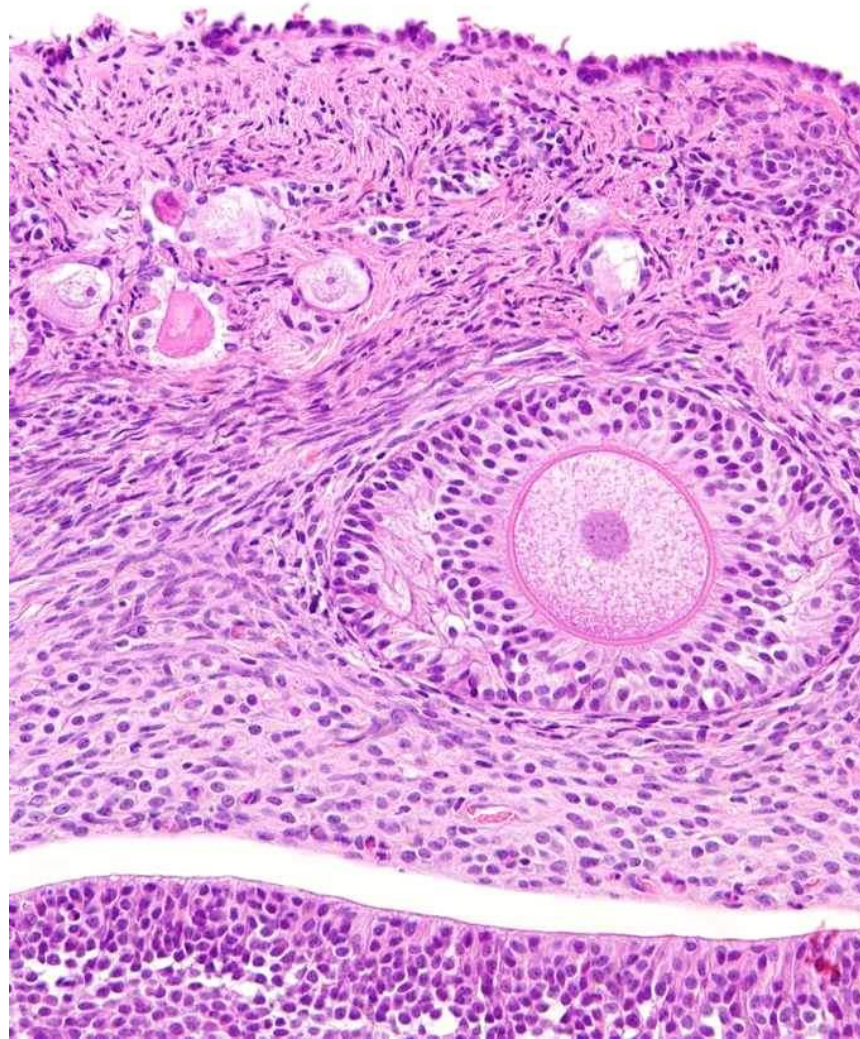




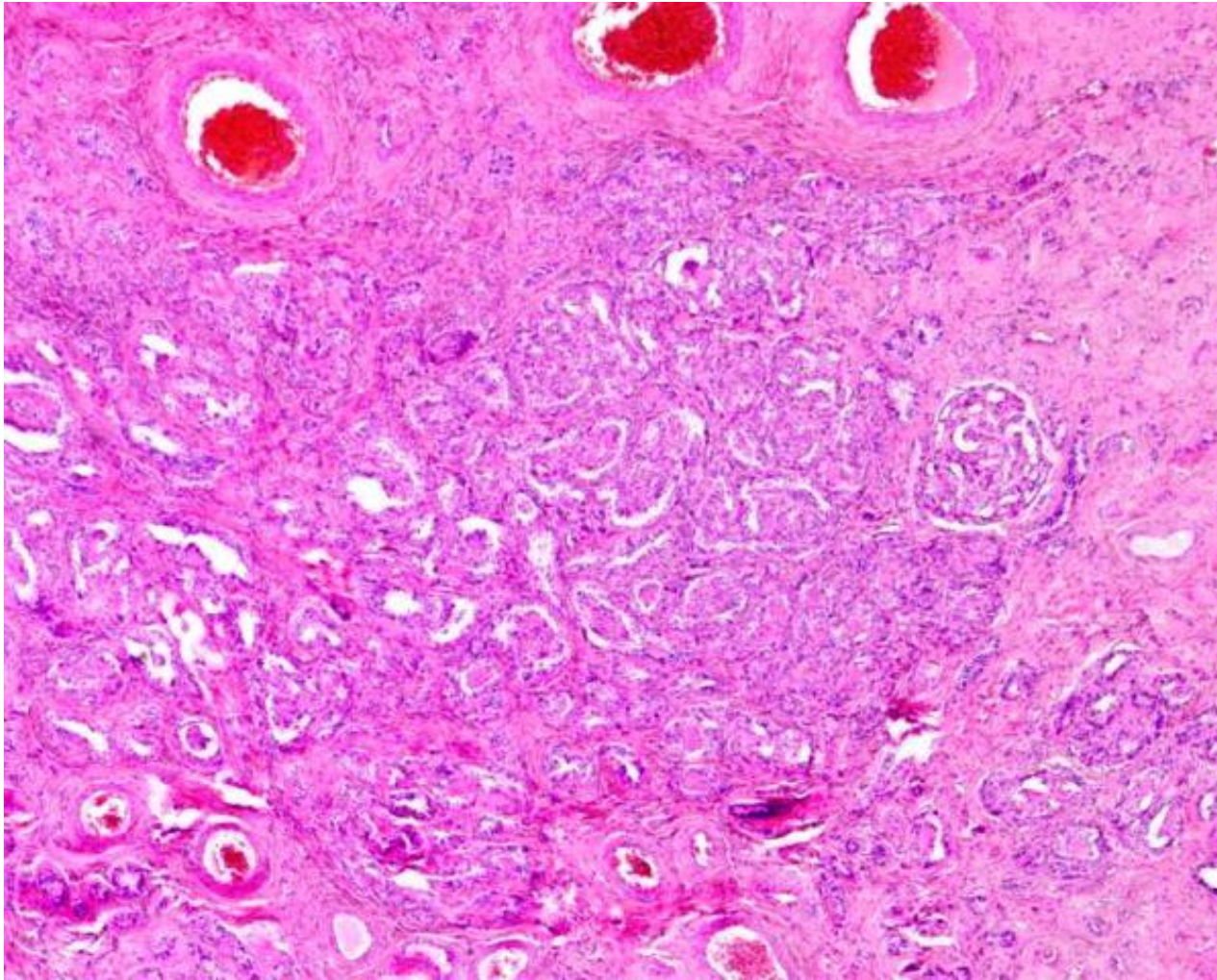
# Canine ovary



# Normal ovary



# Canine ovary - rete





# Canine endometrial lesions

---

- Dog has a prolonged diestrus period.
- 2 cycles per year
- Prone to endometrial hyperplasia/pyometra
- Pseudopregnancy
- FOP – foetal autolysis.



# Cystic endometrial hyperplasia

---

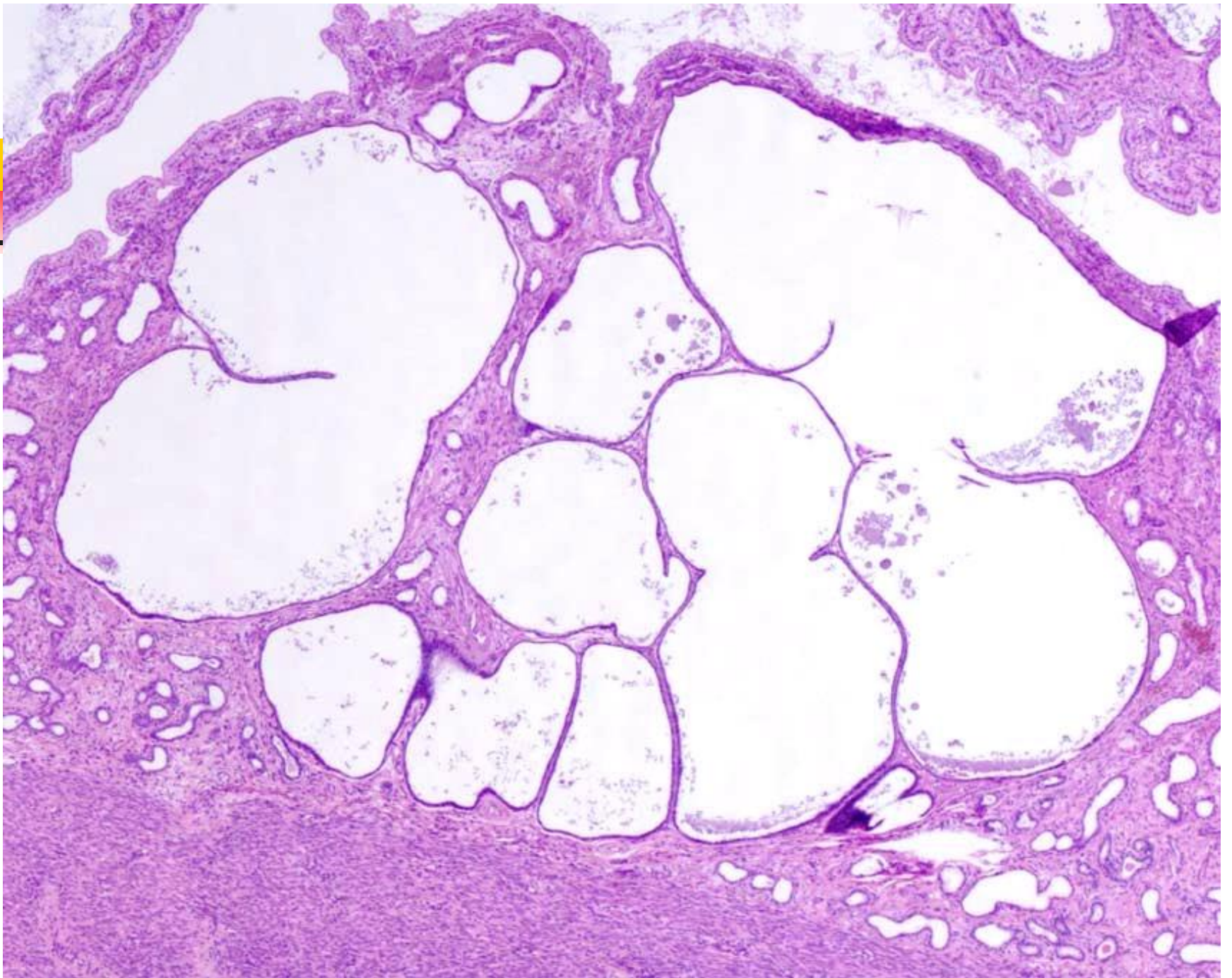
- Chicken or egg
  
- Dogma
  - long dioestral period
  - hormonal cycles without pregnancy
  - bacterial infection
  - pyometra

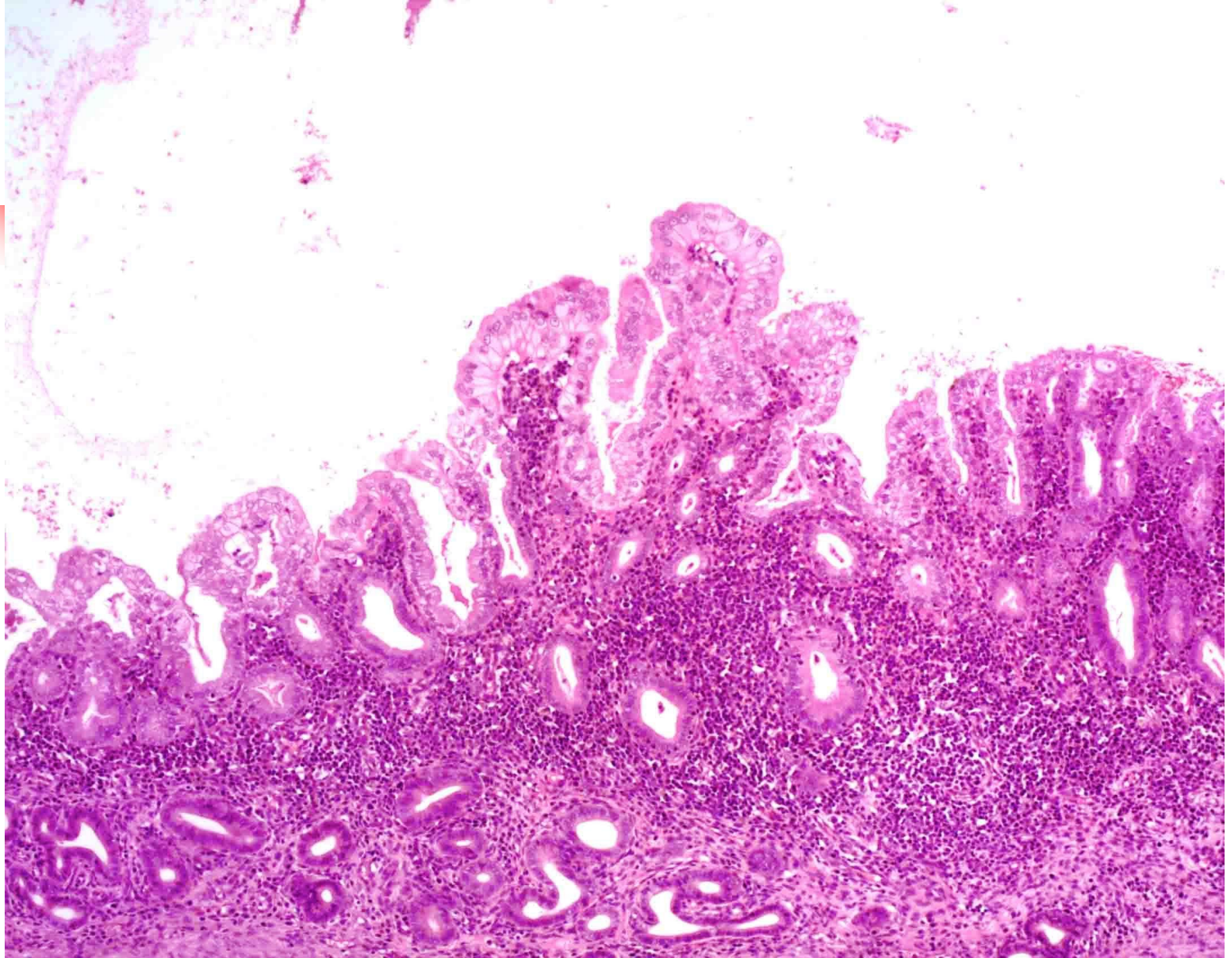


# CEH/Pyometra

---

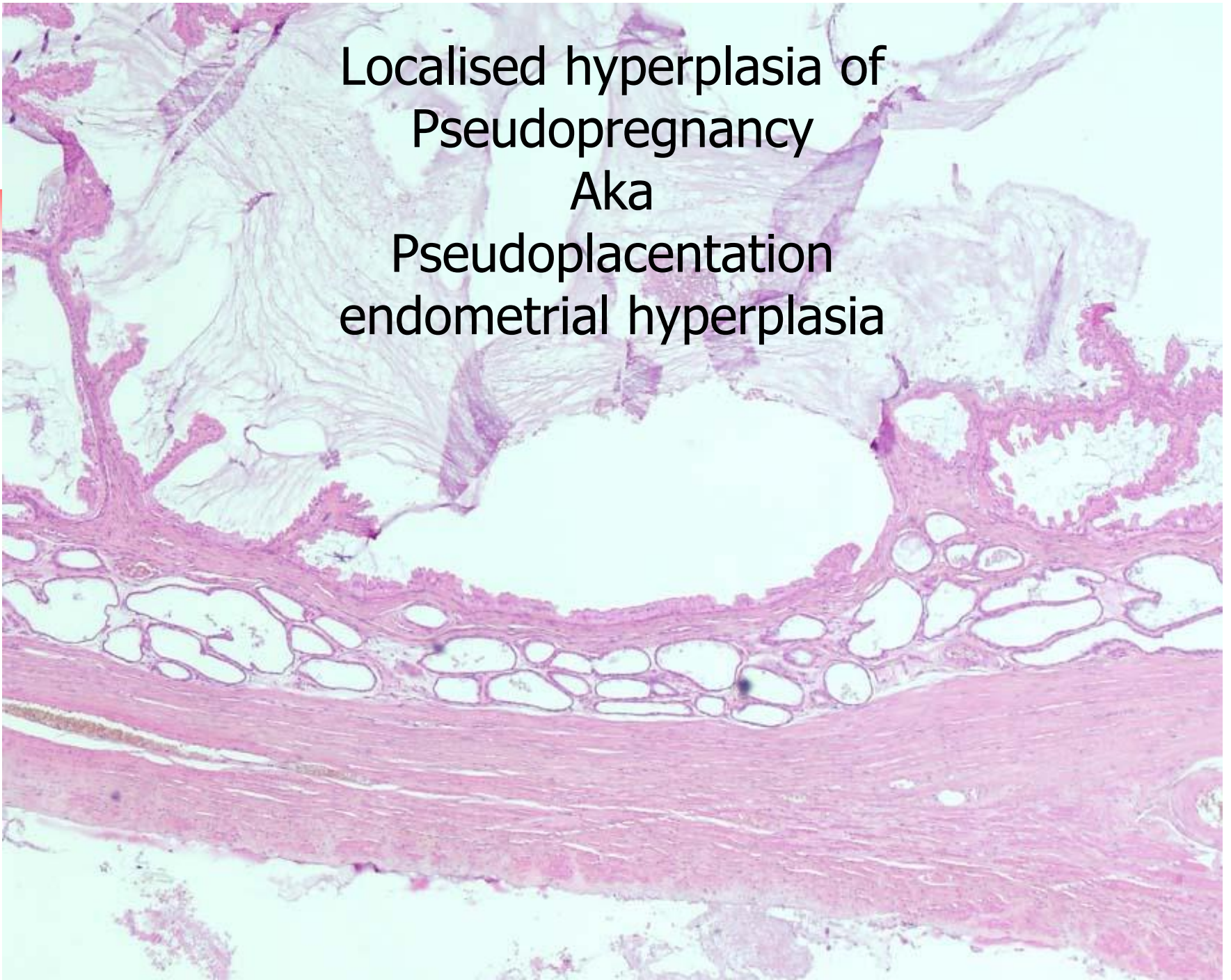
- 'New' scheme
- Canine endometrium is primed for pregnancy
- Bacteria, foreign material, embryo induces hyperplastic changes
- CEH and Pyometra are epiphenomina

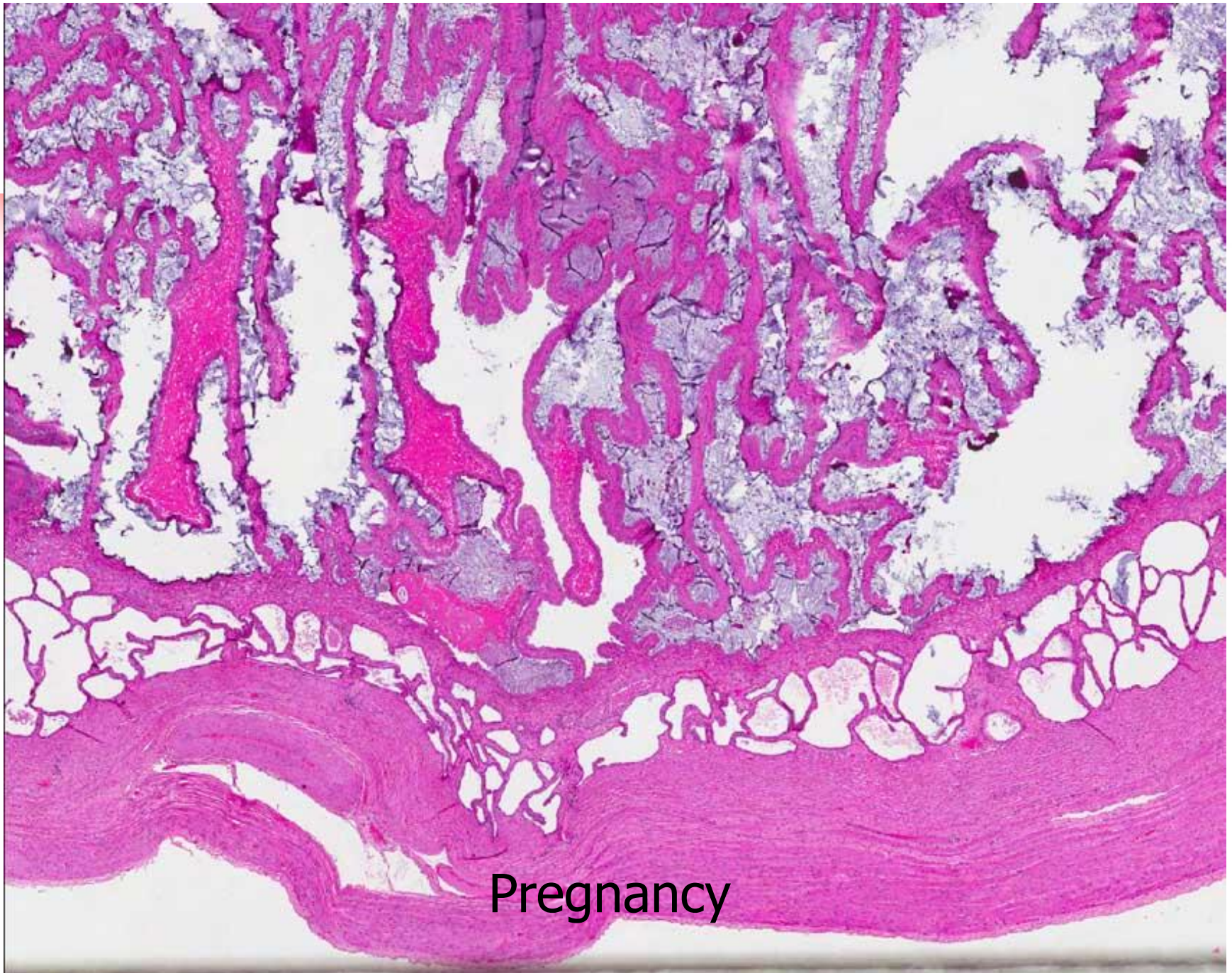



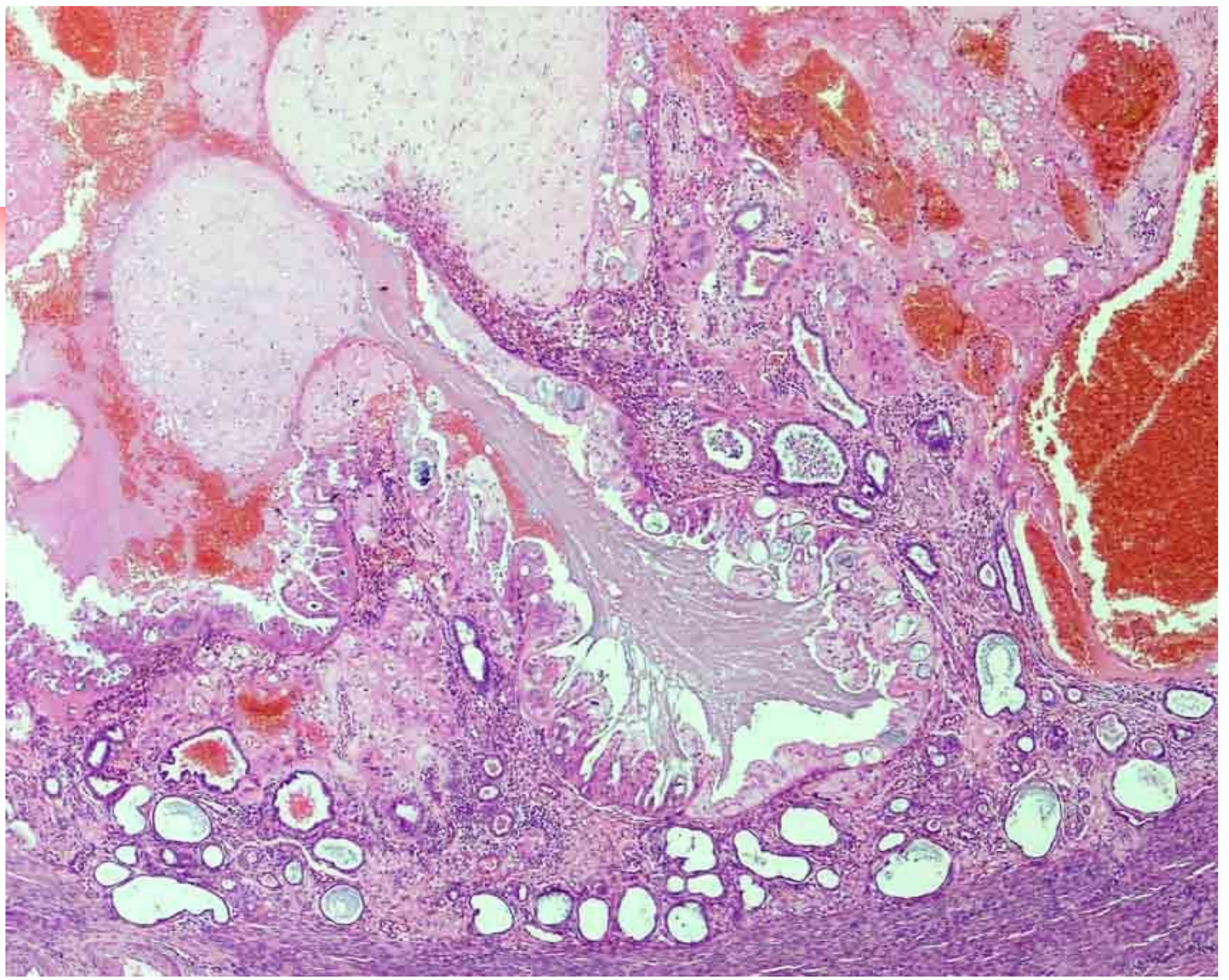


Localised hyperplasia of  
Pseudopregnancy  
Aka  
Pseudoplacentation  
endometrial hyperplasia

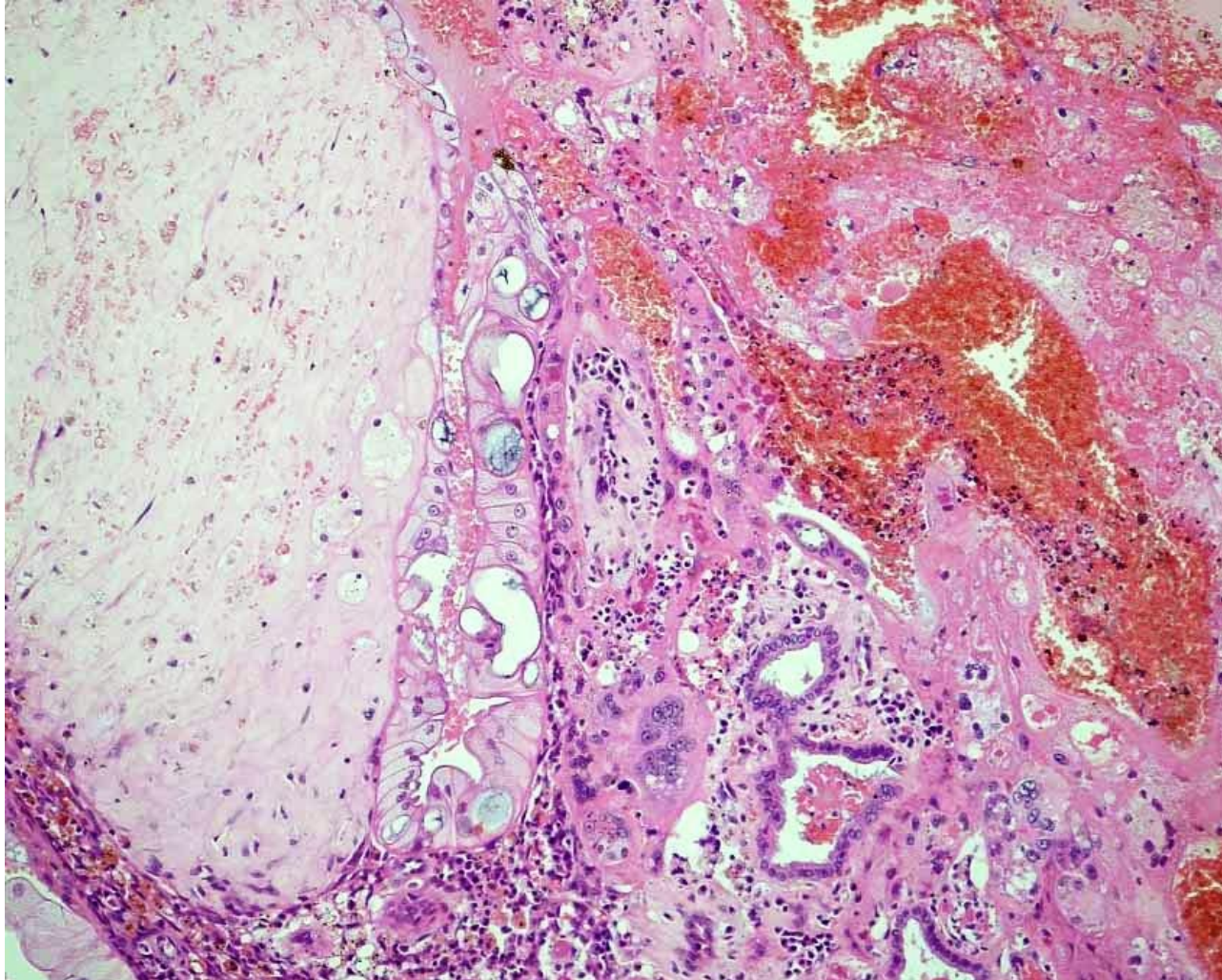




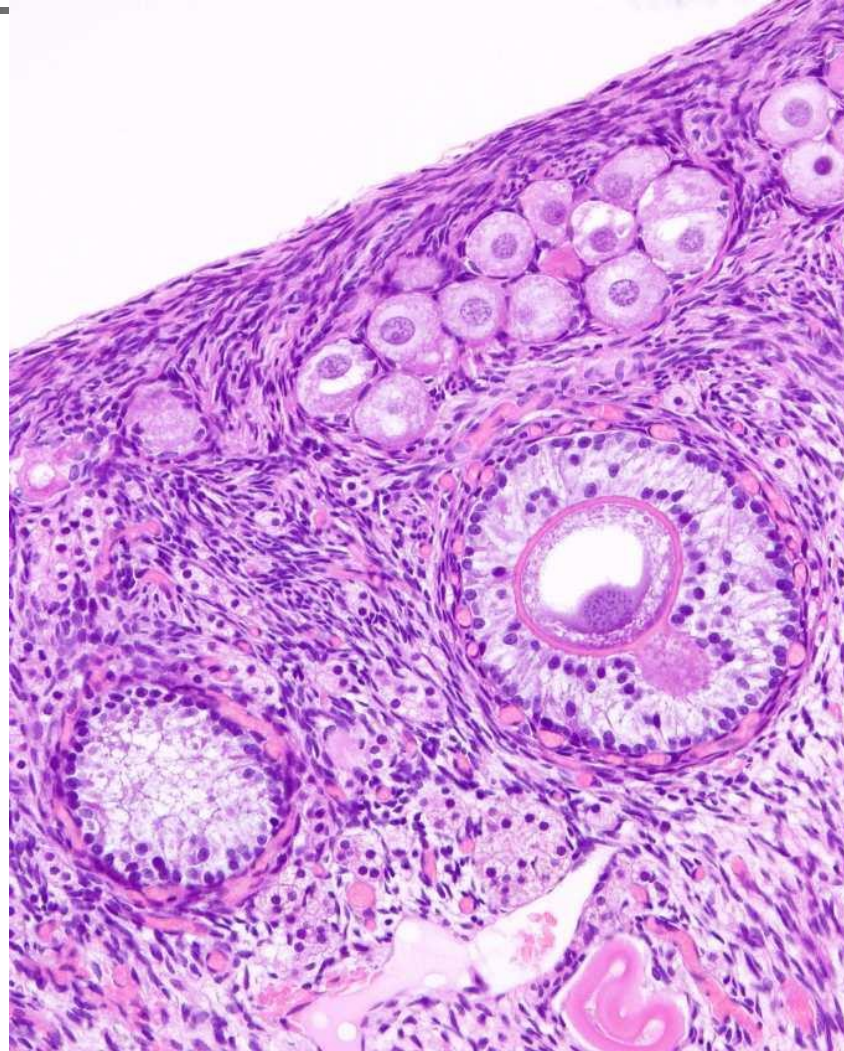
Pregnancy



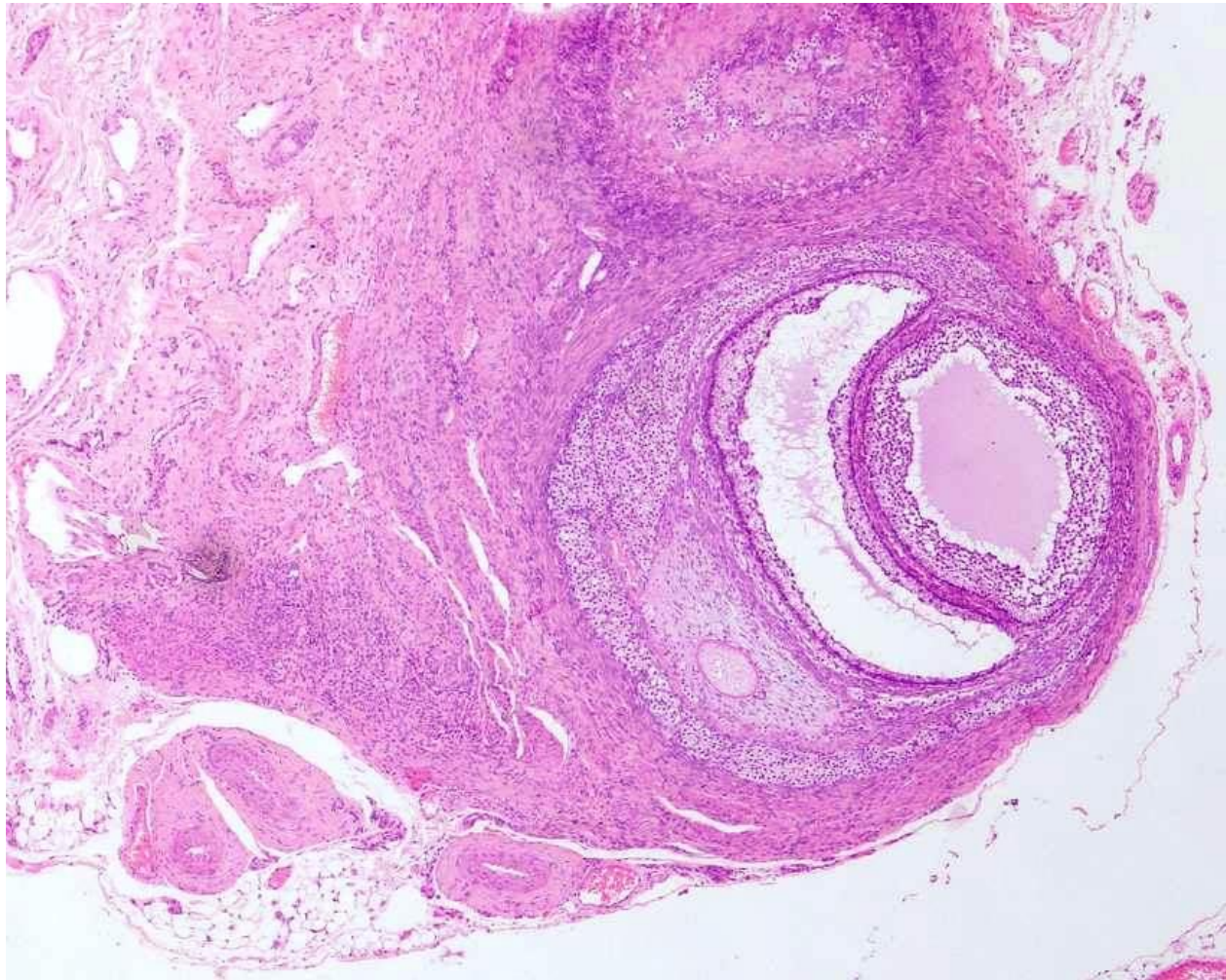
# Subinvolution of placental sites



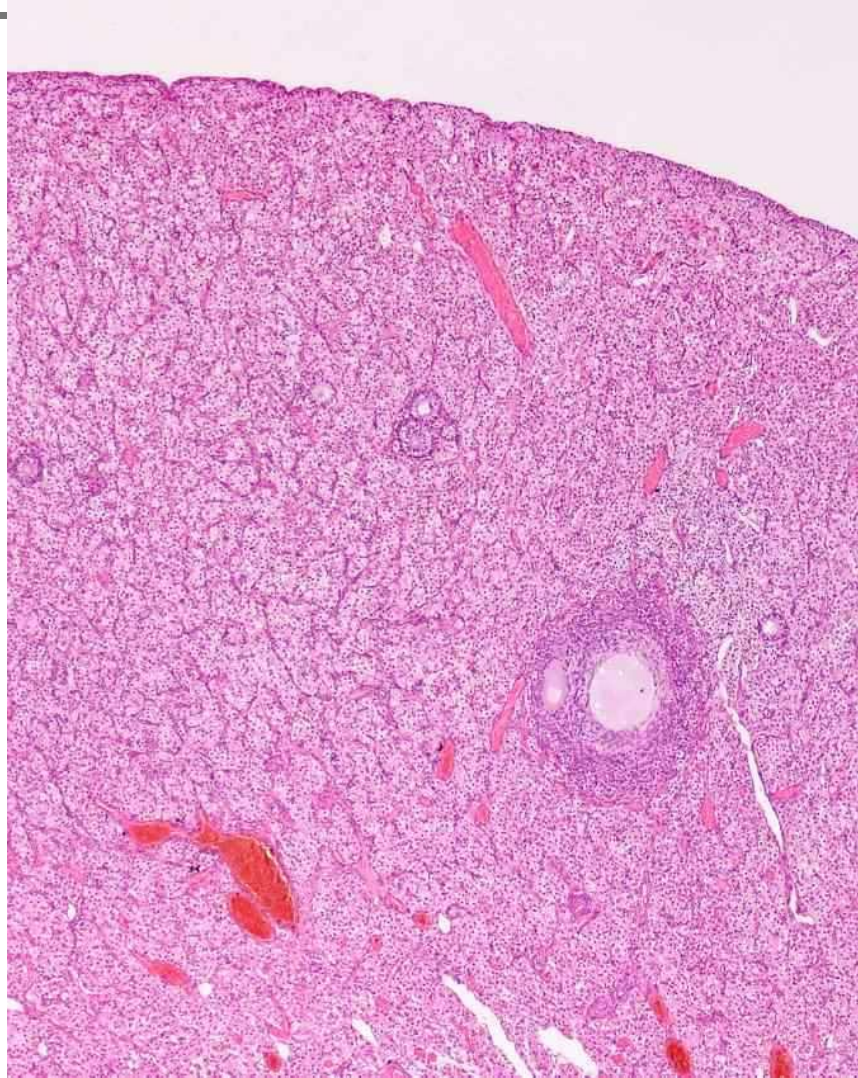
# Normal feline ovary



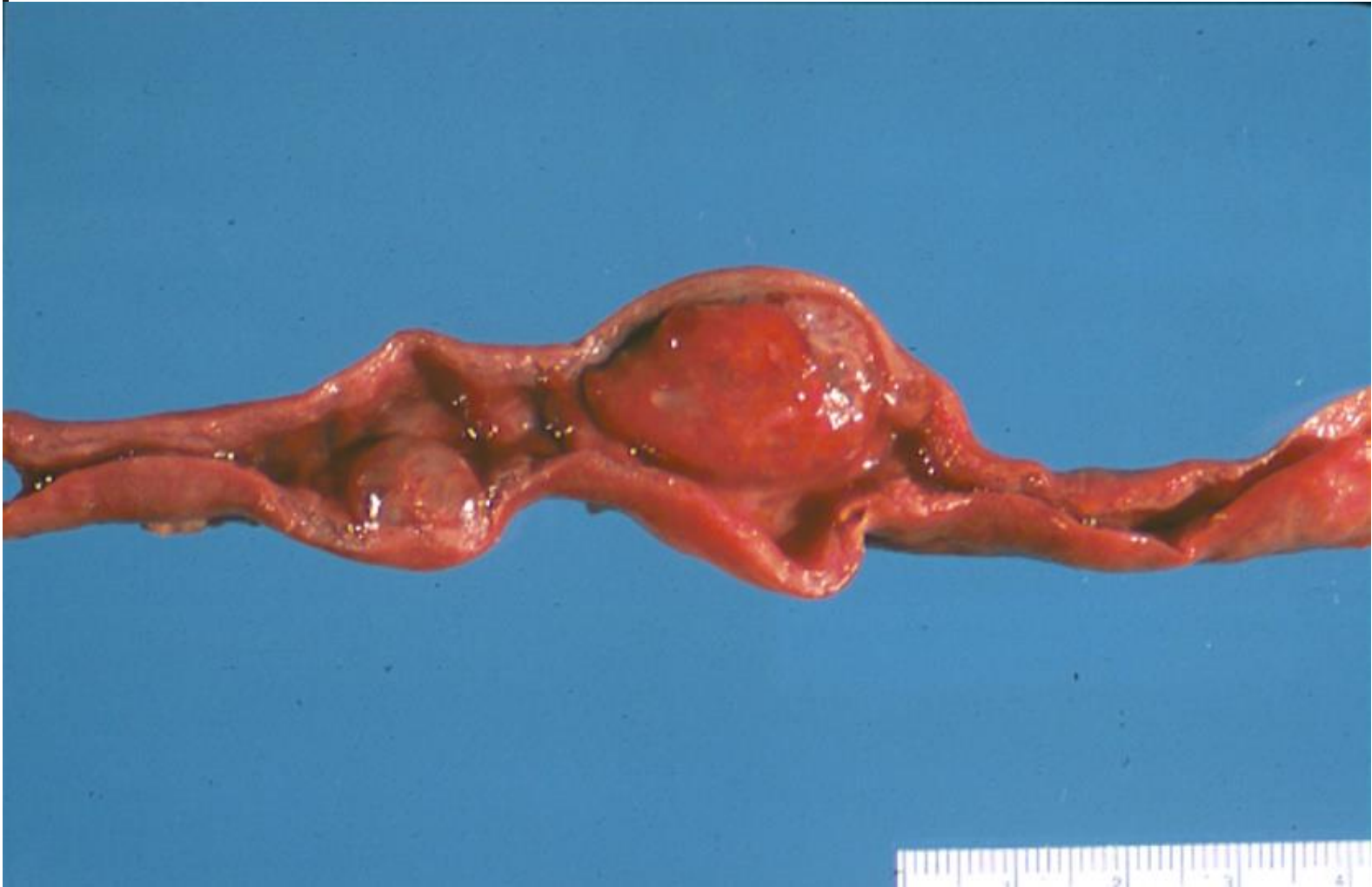# Ovarian remnant



# Interstitial cell hyperplasia

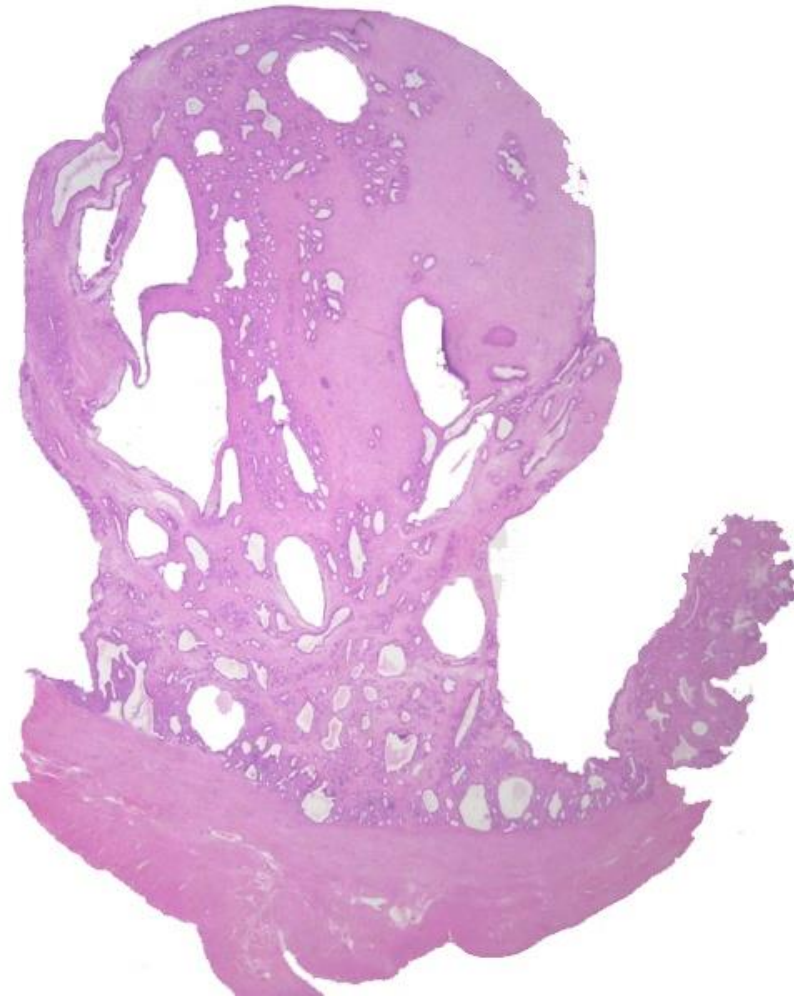


# Uterine Polyp



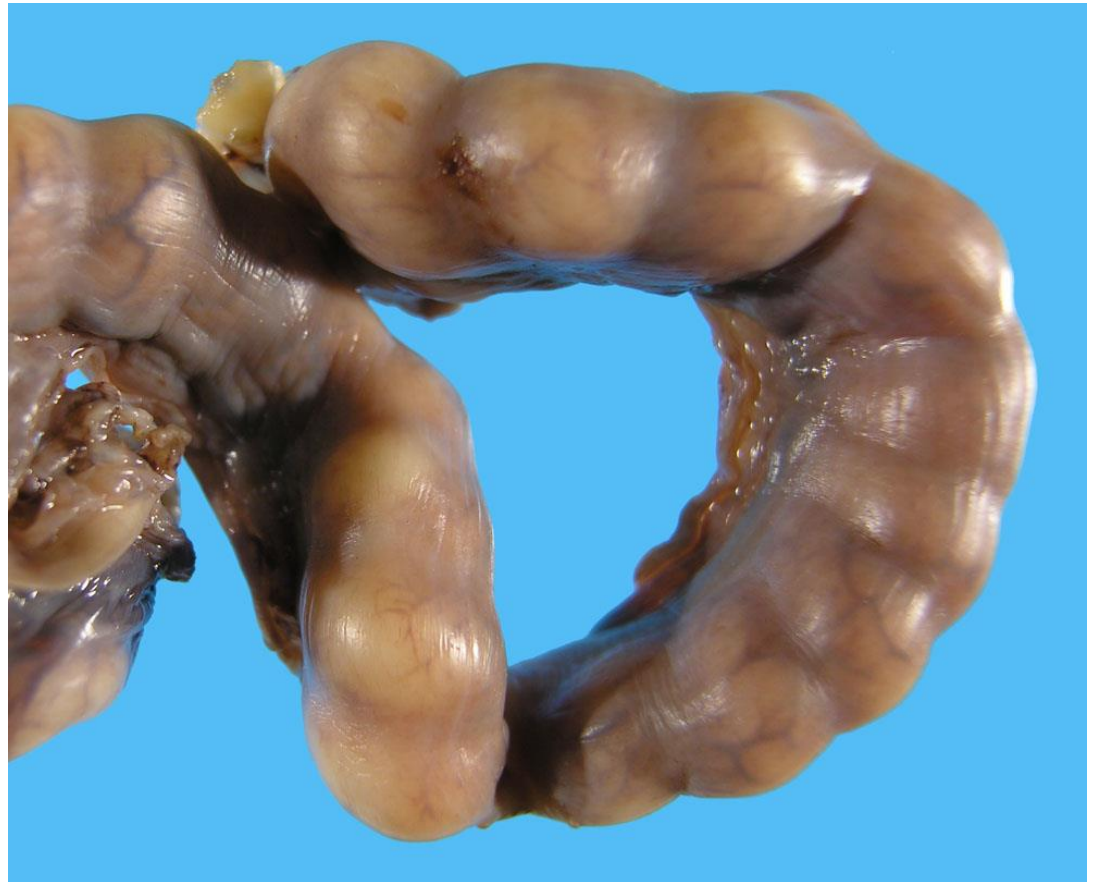

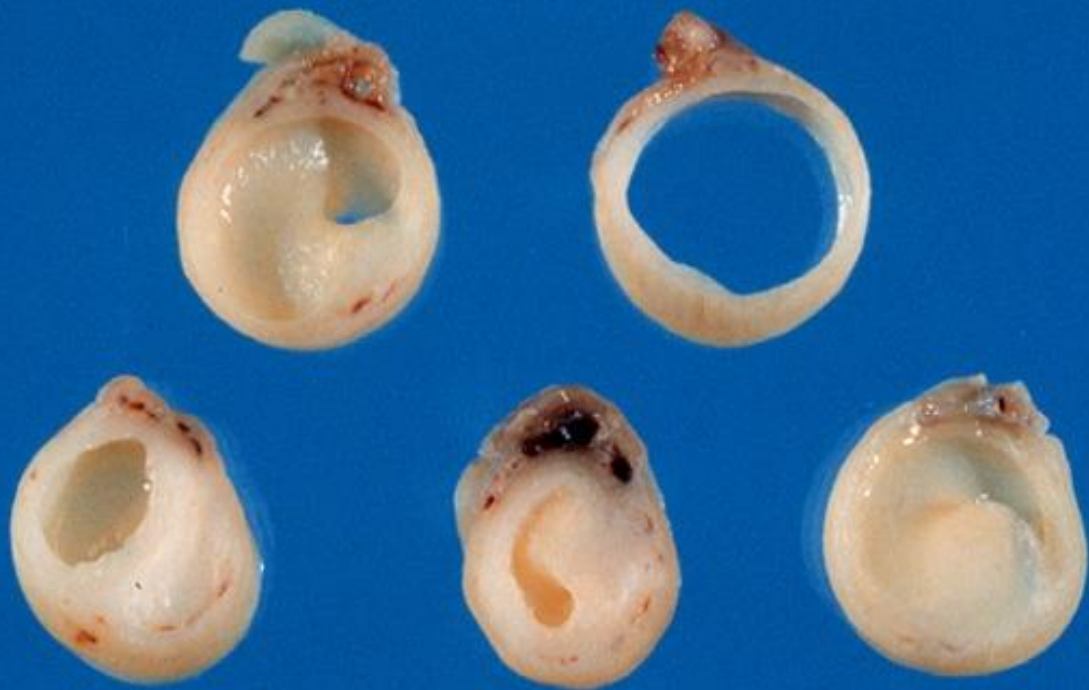# Uterine polyp



# 2 yrs old female cat

- Routine spay
- Uterus 1 cm diameter and looks like a beads of pearls







# Disorders of Sexual Development

Intersex

Sex reversal

Hermaphrodite

Pseudohermaphrodite

Ambiguous development





# Basis of new nomenclature - Pathogenesis

---

- Genetic
  - Chromosomes (XX, XY, X\_ mosaics, chimeras)
  - Genes (*SRY*)
- Gonadal
  - Testis
  - Ovary
  - Ovotestis
  - dysgenesis
- Phenotype



# Chromosomal DSD

---

- Aneuploidy
  - X<sub>0</sub> - Turner
  - XXX – Trisomy X
  - XXY - Klinefelter
- Mosaics and Chimera
  - Chimera (XX/XY) cells of different zygotes fuse –
  - Mosaic – non disjunction in a single zygote



# XX DSD

---

- Abnormal gonads
  - XX Gonadal dysgenesis DSD
  - XX Ovotesticular DSD
  - XX Testicular DSD
- Normal gonads
  - XX ovarian DSD



# XY DSD

---

- Abnormal gonads
  - XY gonadal dysgenesis DSD
  - XY ovotesticular DSD
  - XY testicular regression DSD
- Normal gonads
  - XY testicular DSD (PMDS, cryptorchidism)



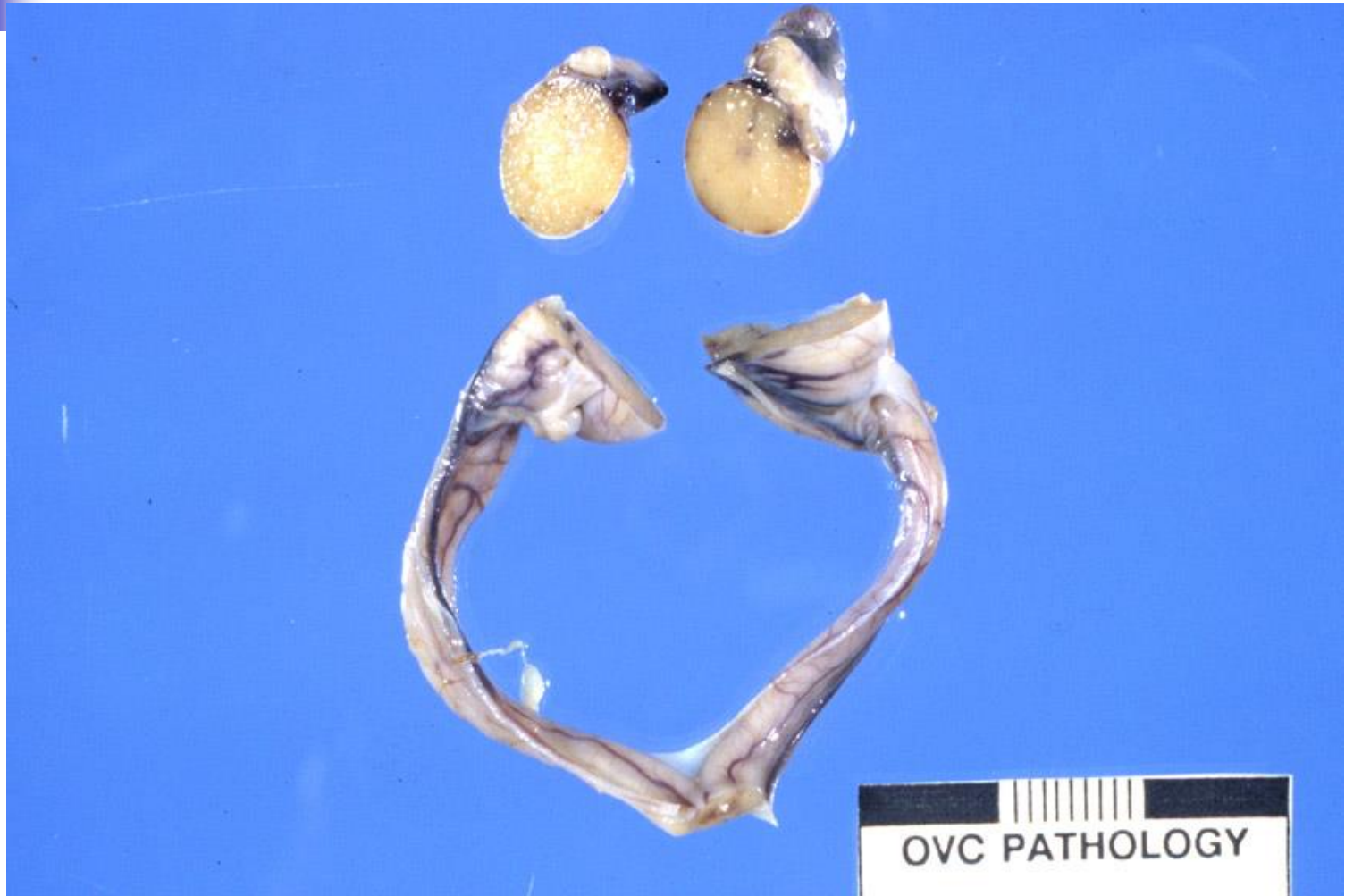


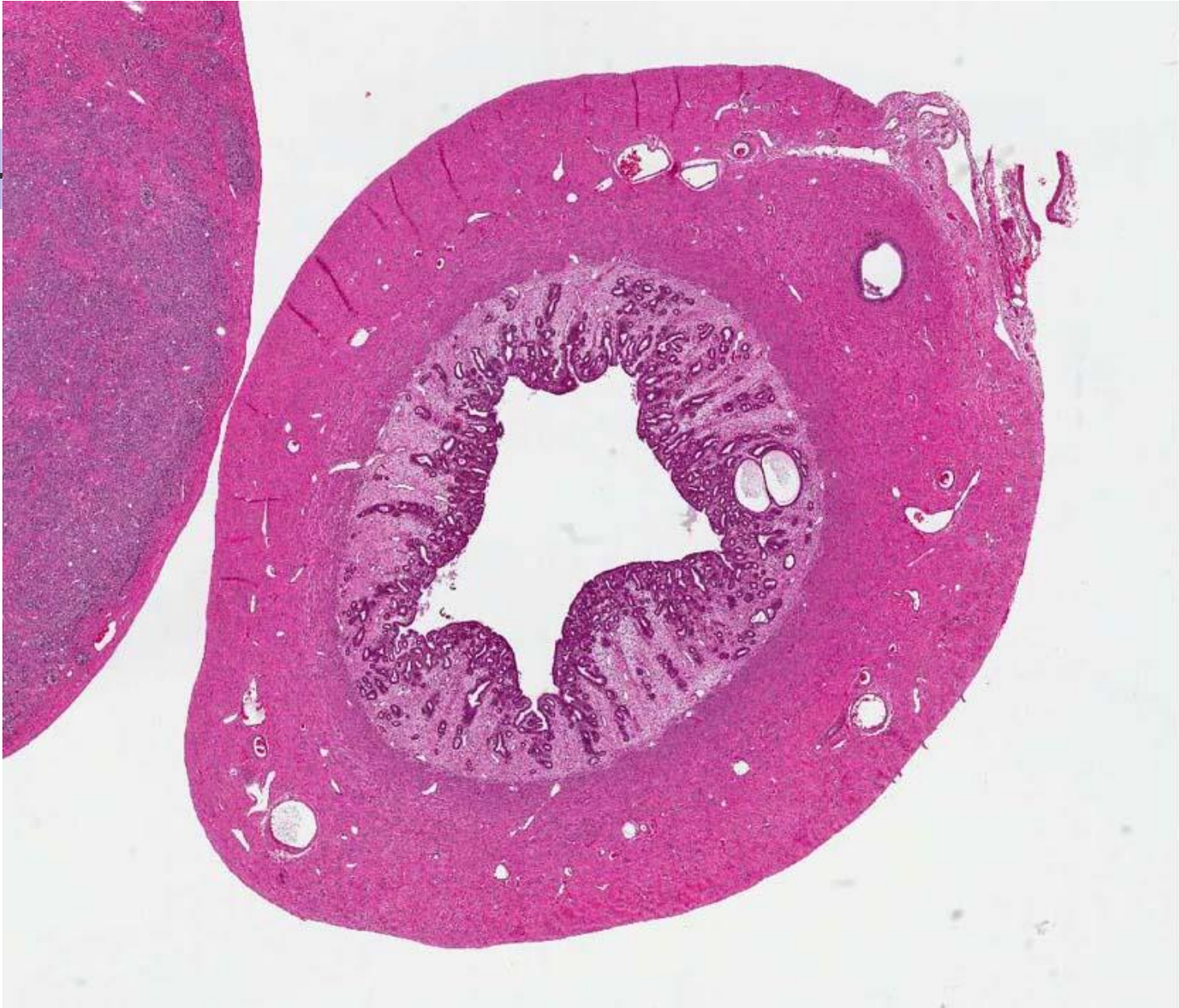# Equine DSD

---

- *XX SRY-* ovotesticular DSD females
  - 6 cases
- *XY SRY-* gonadal dysgenesis females
  - 6 cases
- *XY SRY+* testicular (normal) females
  - 5 cases
- No *XX SRY+* ever been verified

# Thickened deferent duct







# Diagnosis

---

- XY, *SRY* positive, testicular disorder of sexual development, Persistent Müllerian Duct Syndrome (PMDS)
- Anti-Müllerian Hormone receptor
- Paramesonephric duct fails to regress
- Cryptorchidism from resistance to AMH in testicular descent



# Miniature schnauzer PMDS

---

- Autosomal recessive inherited disorder
- Mutation in AMH receptor gene
  
- Cryptorchidism – Sertoli cell tumours
- Hydrometra and pyometra occur



# Cryptorchidism

---

- Migration

- Abdominal translocation

- Insulin-like protein 3, Anti Müllerian hormone (AMH; MIS)

- Transinguinal migration

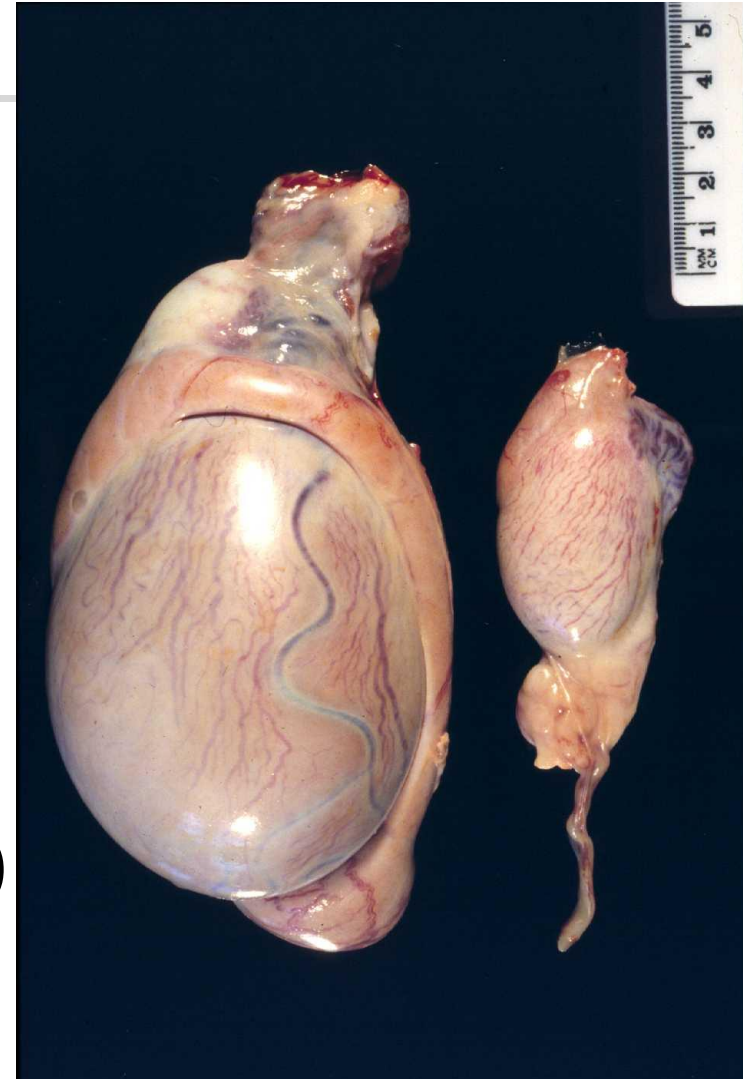
- Gubernaculum dilates inguinal canal and intraabdominal pressure

- Inguinoscrotal migration

- androgen
- calcitonin gene related protein
- genitofemoral nerve

# Testis - too small

- Cryptorchidism
  - XY *SRY*+ testicular DSD
- Maldescent
  - genetic
  - hormonal
  - structural
  - environmental (outbreaks)



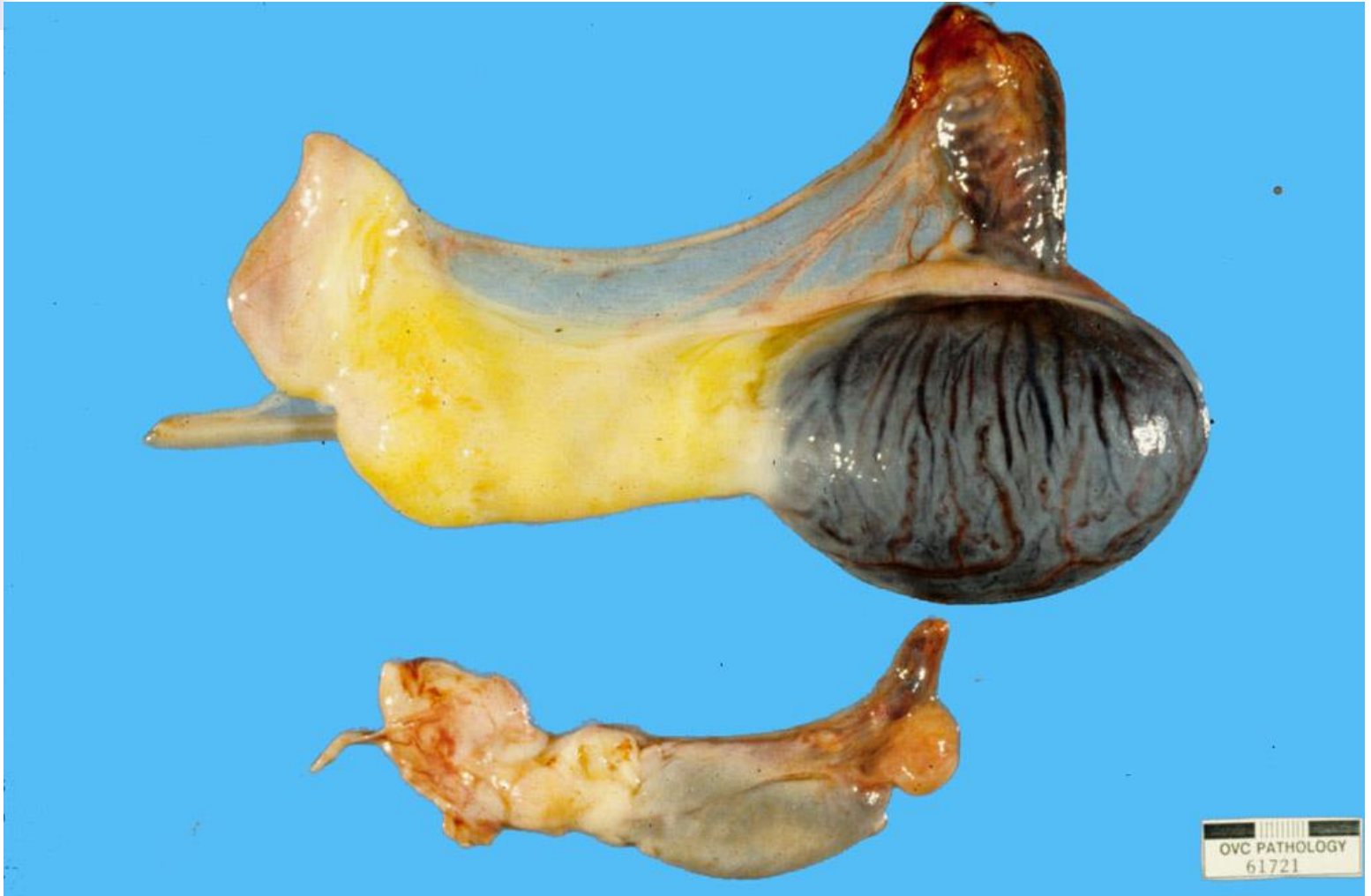

# Male Reproductive Pathology

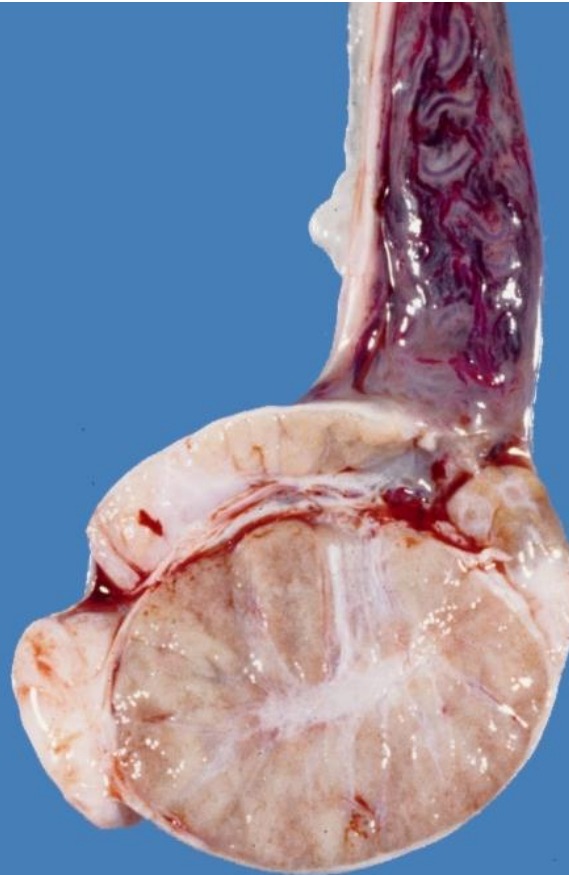




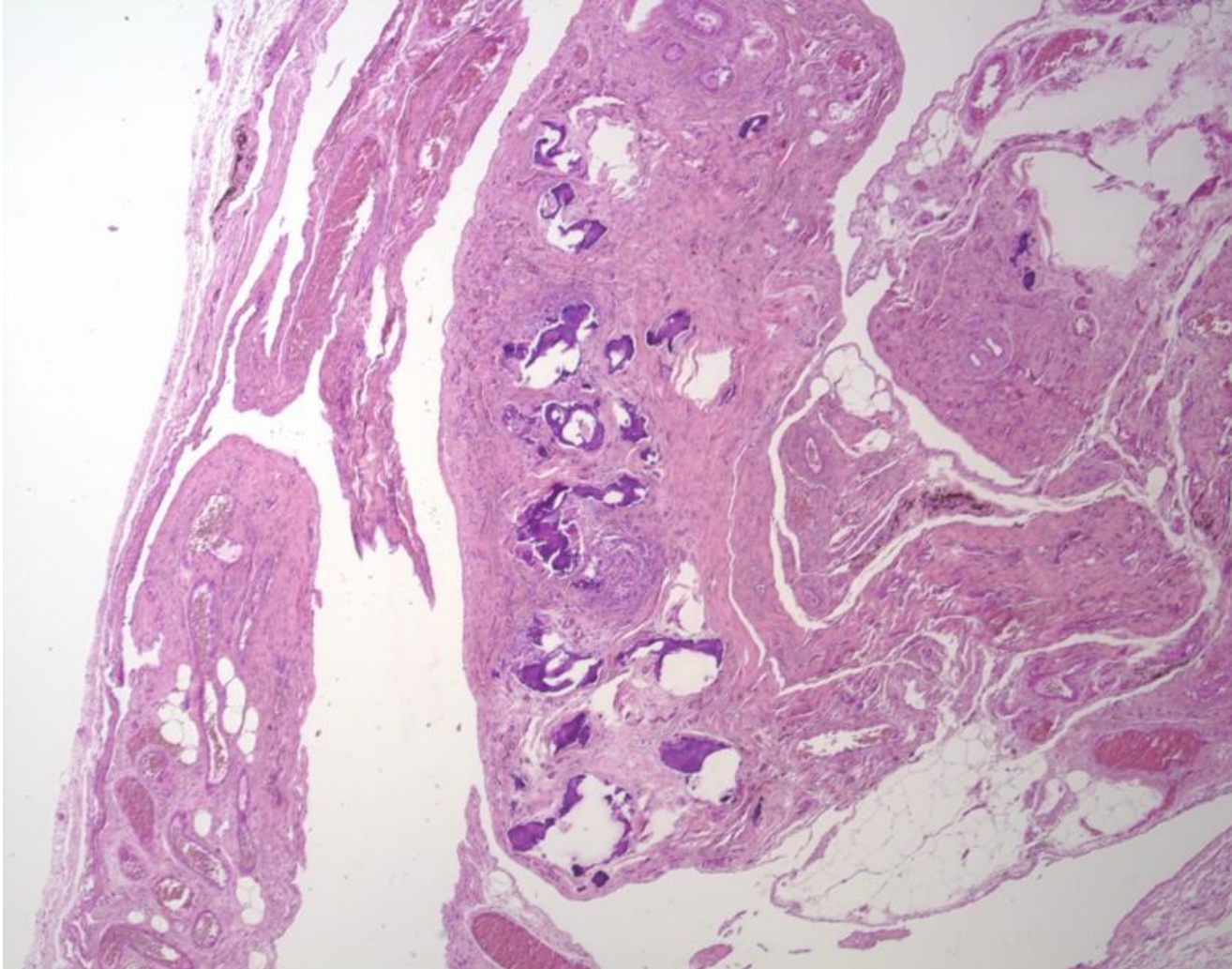
# Gonadal hypertrophy

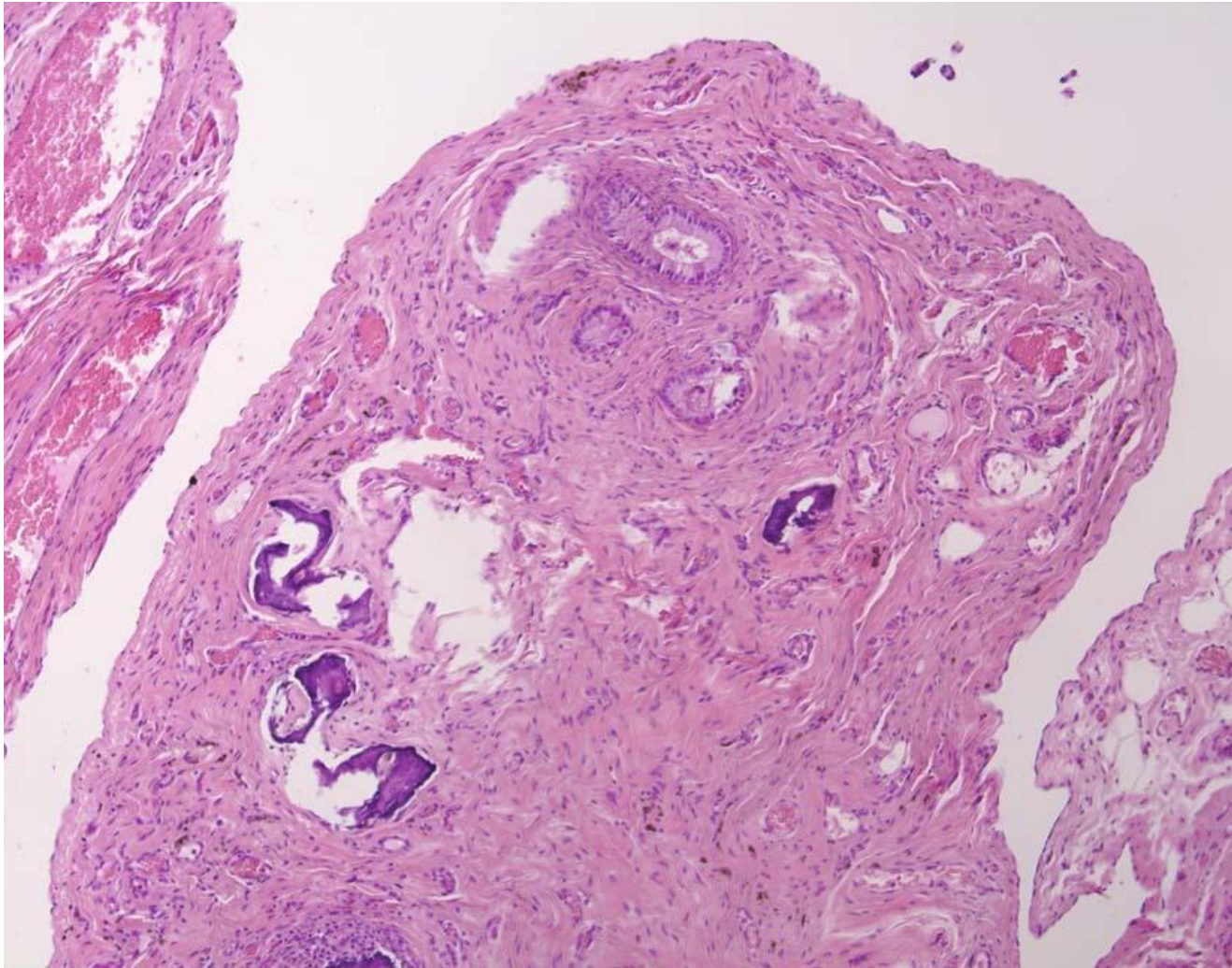


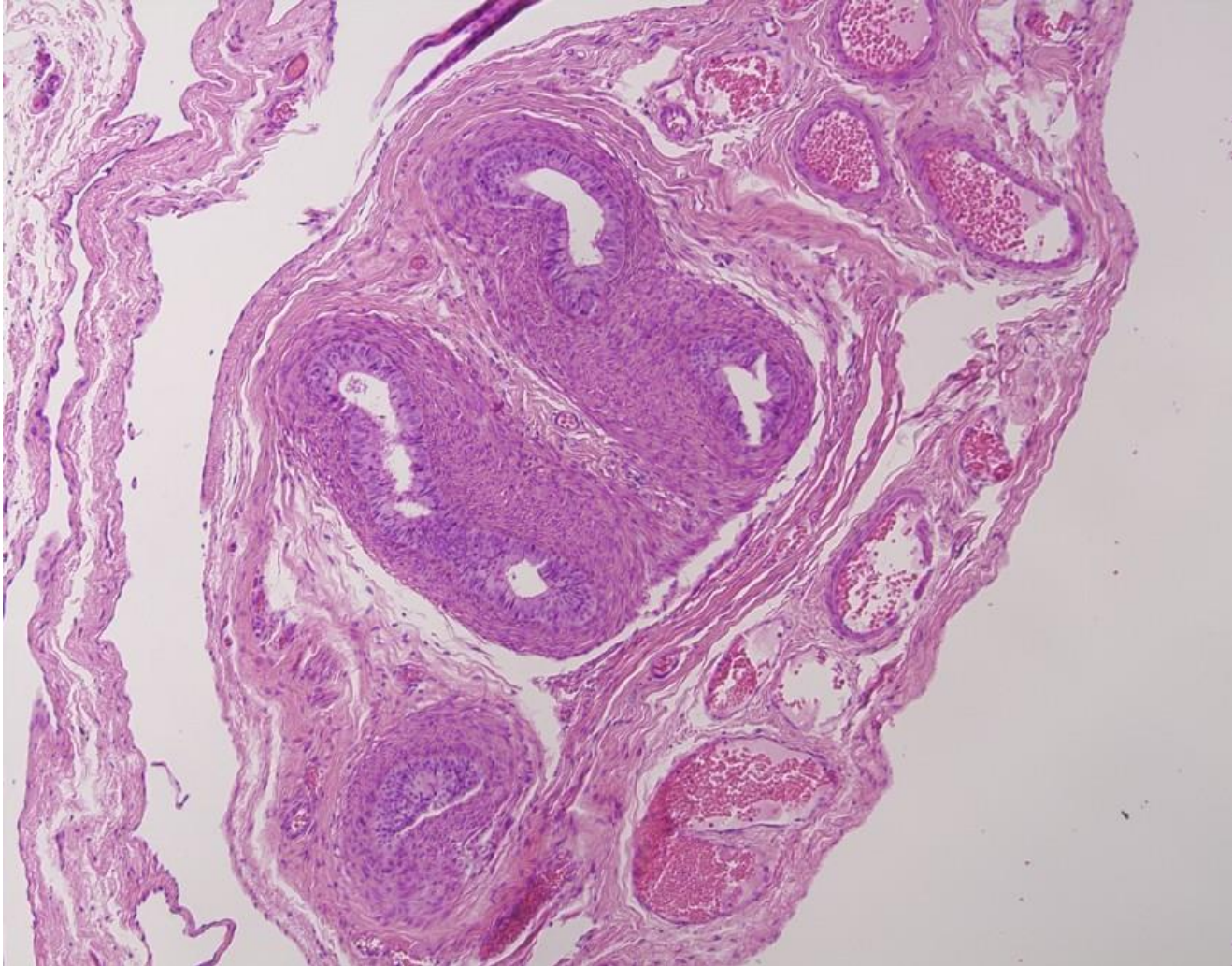

# Canine testis



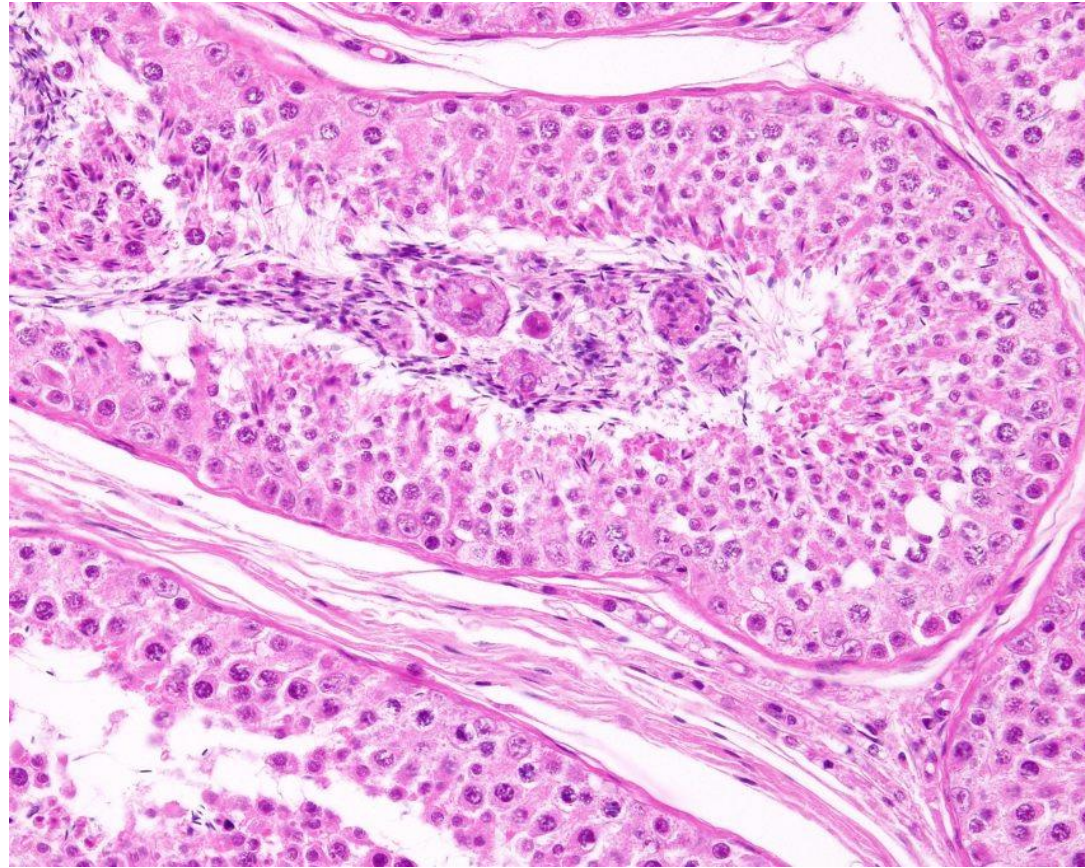
# 'Cryptorchid'. Is this a testis?

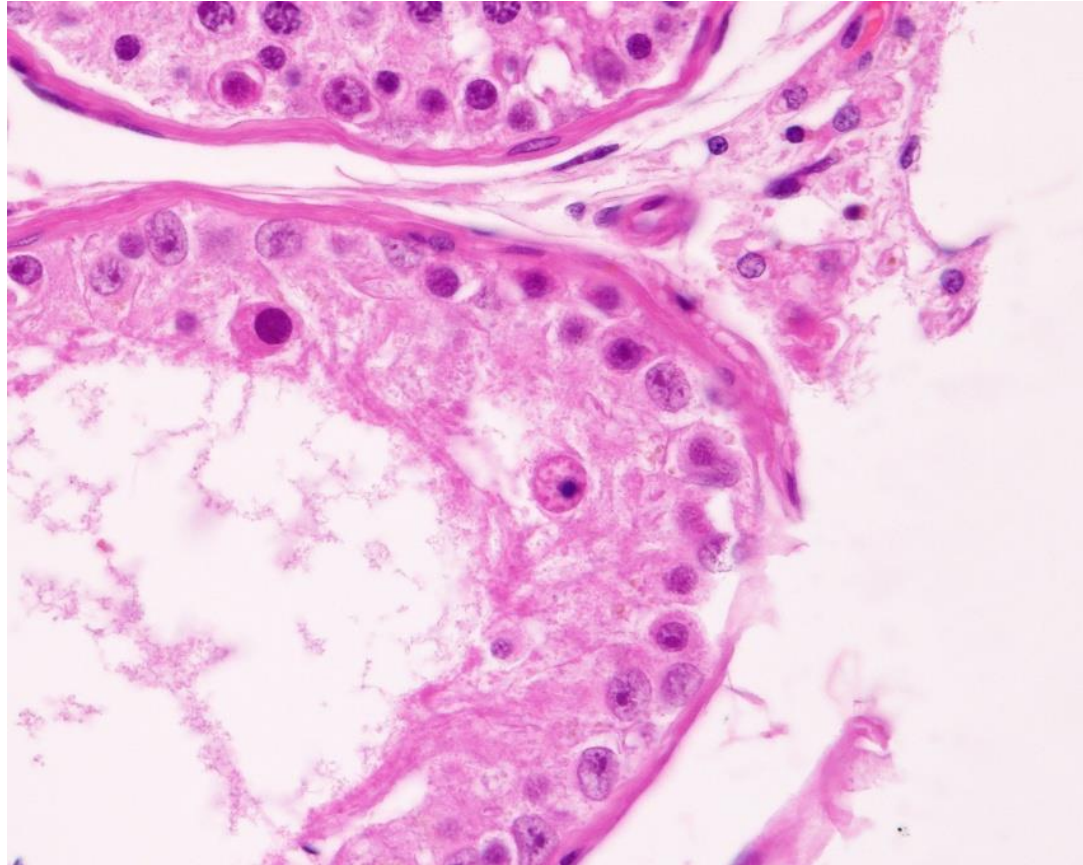


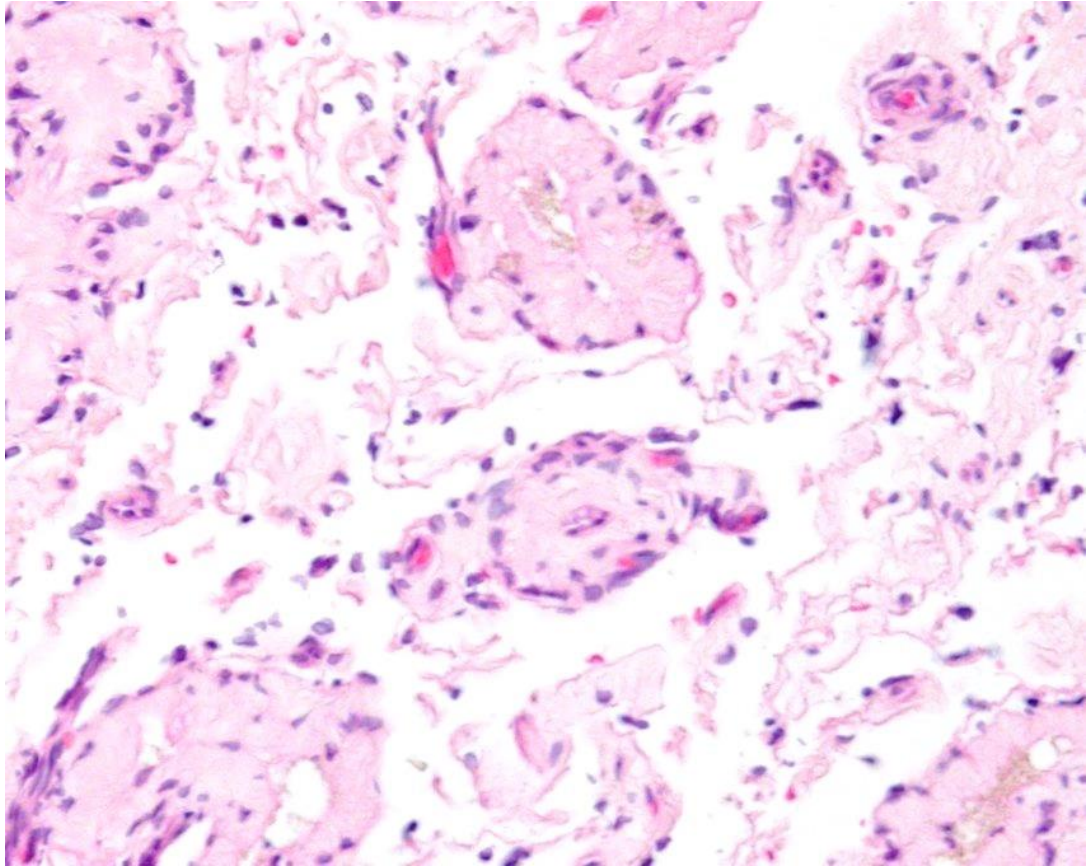




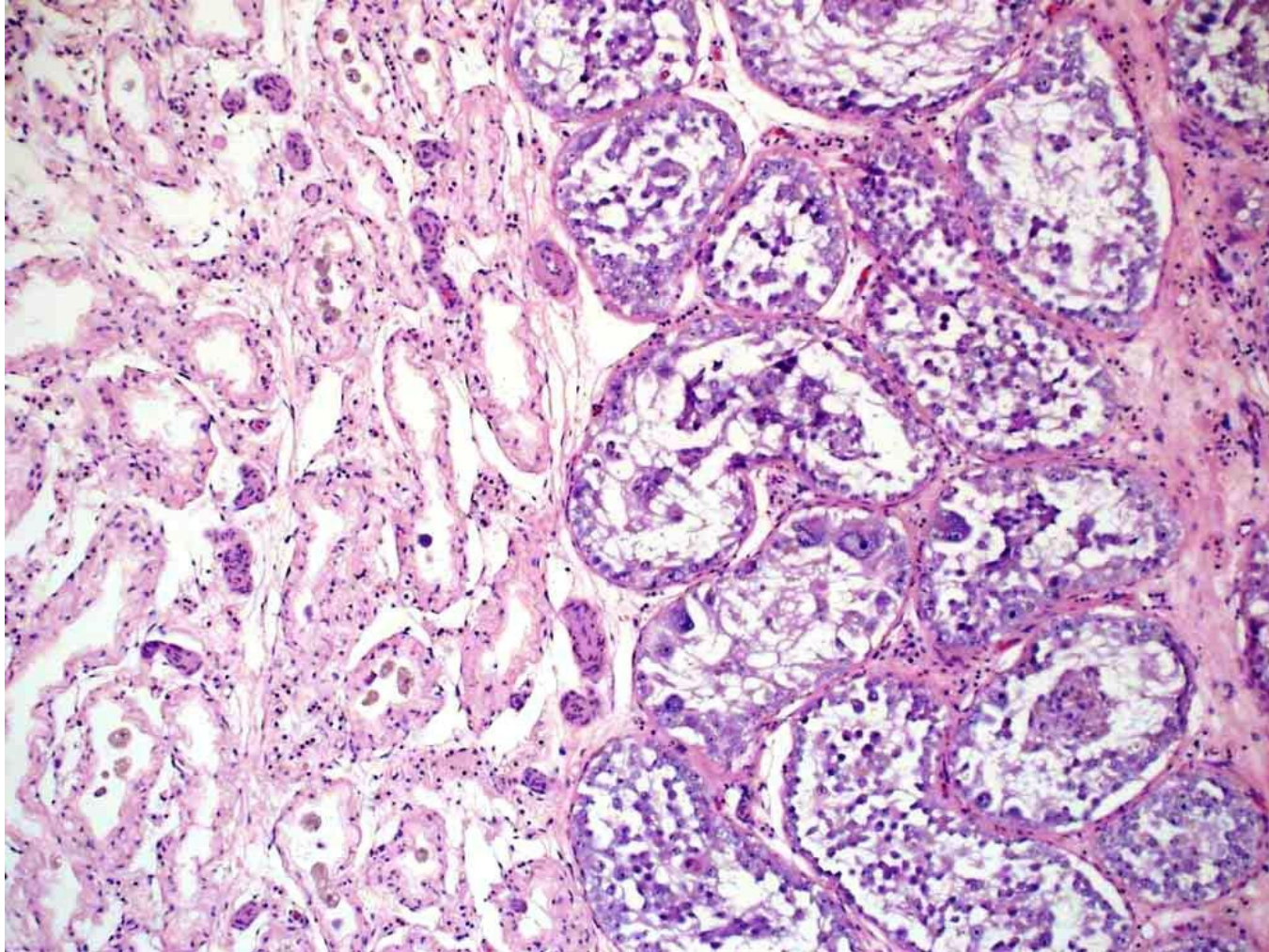

# Testicular degeneration

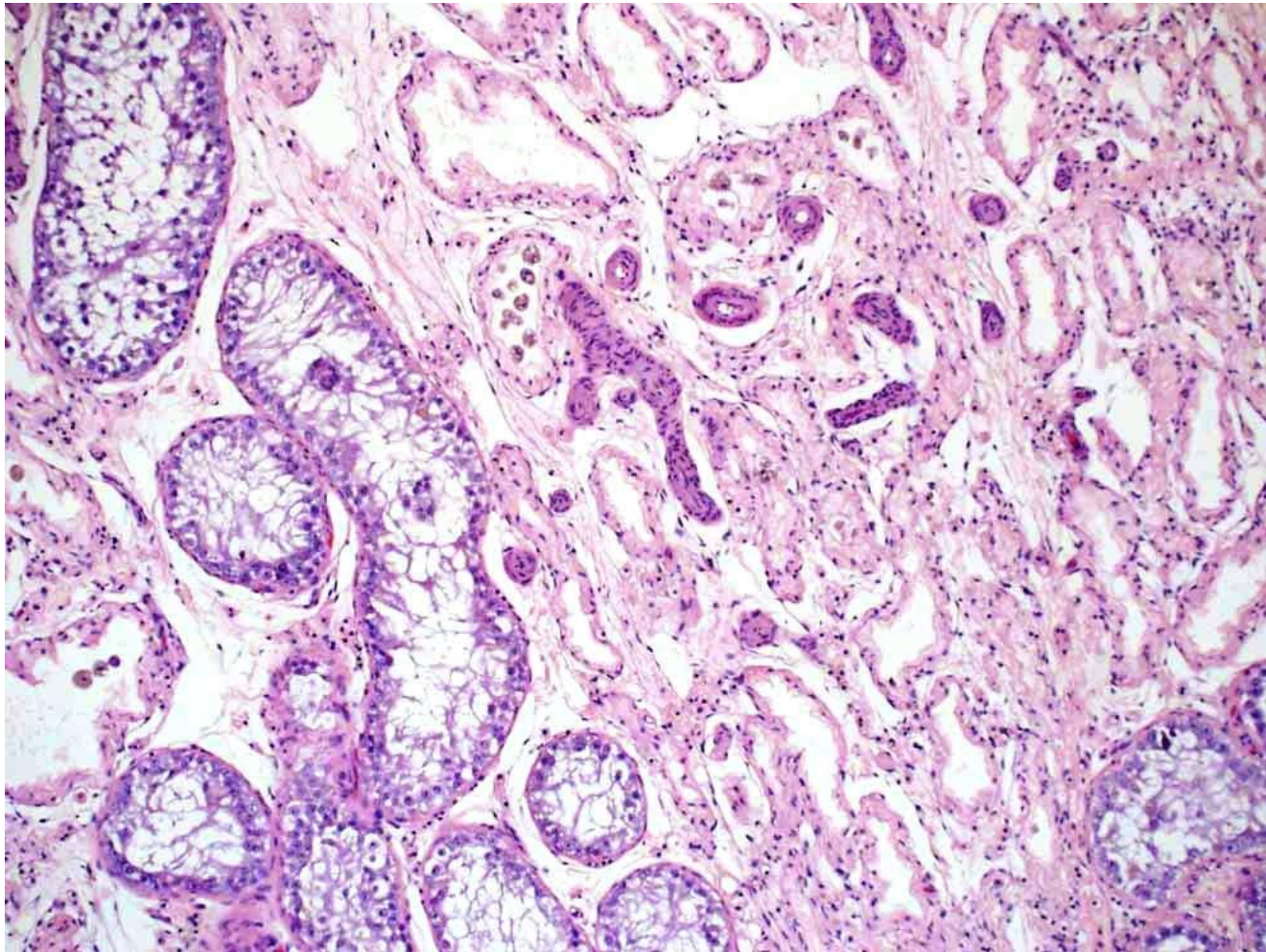















# Testicular degeneration

---

- Blood flow
- Oxidant/antioxidant balance
- Nutrition
- Drugs
- Idiopathic

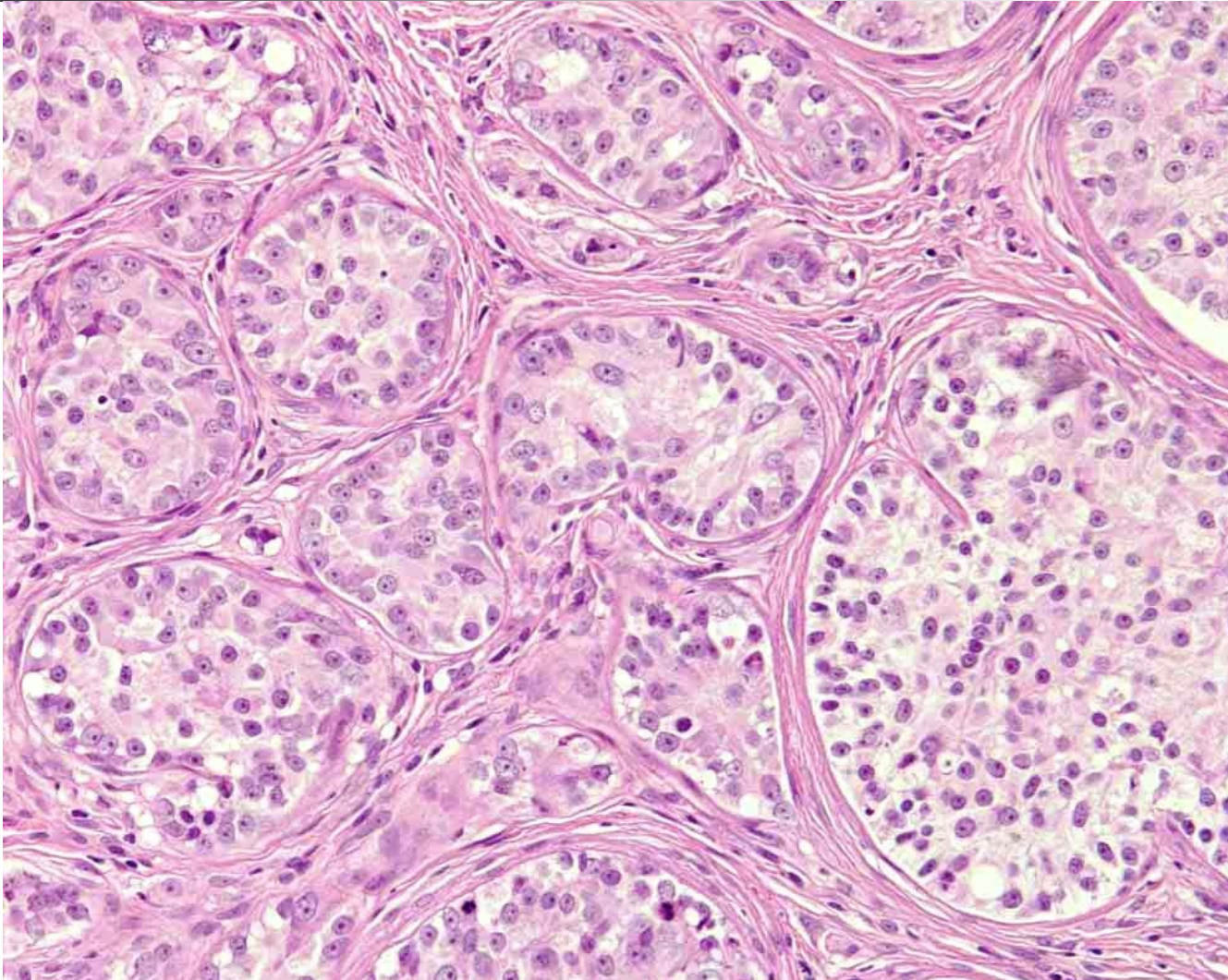


# Diagnostic case

---

- 11 years old dog, neutered as a puppy
- Gynecomastia
  
- Differential diagnoses?

# Prescrotal skin mass





# Extratesticular Sertoli cell tumour

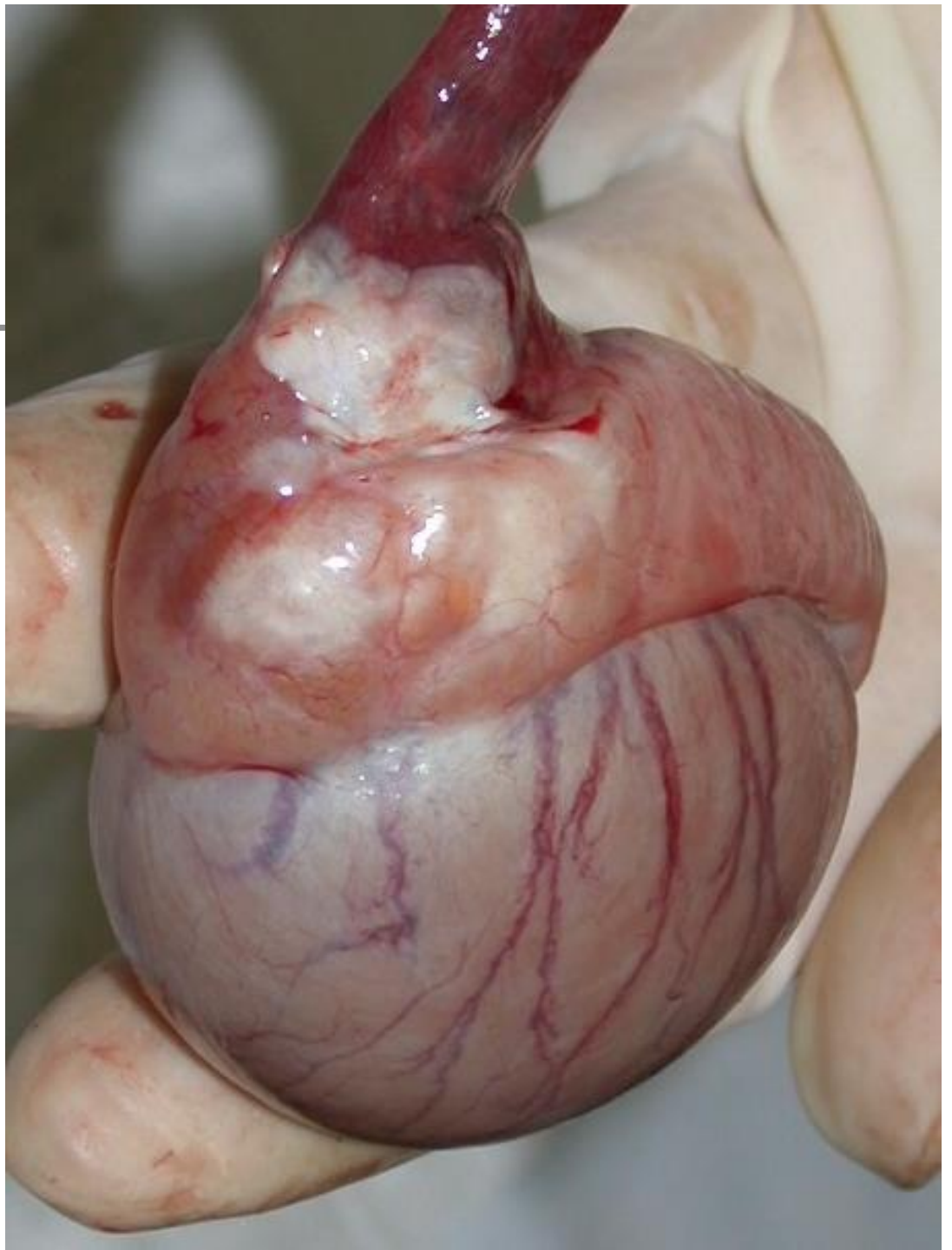
---

- Dog – Sertoli cell tumour
- Cat – interstitial cell tumour
  
- Implantation of testicular tissue at surgery

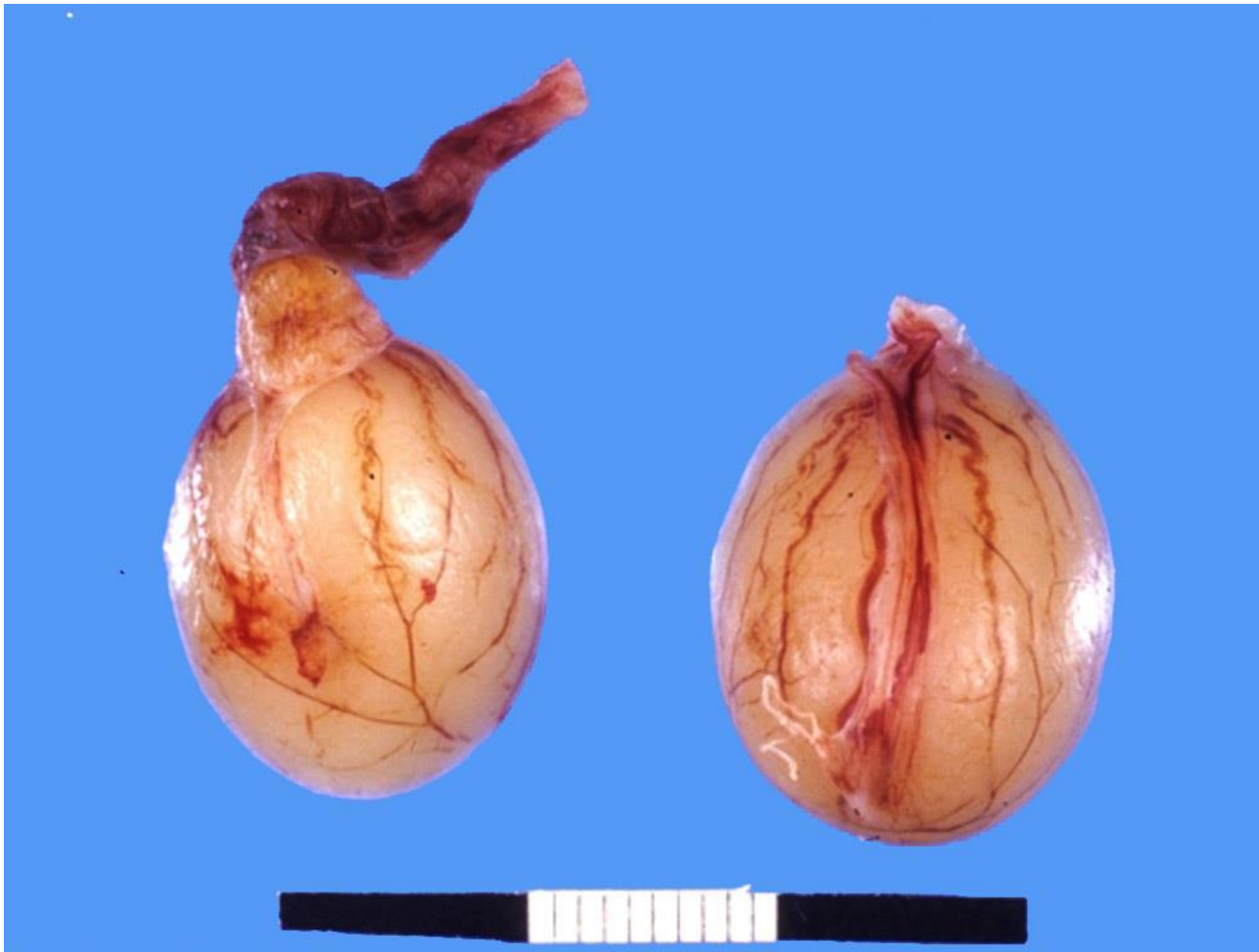The logo consists of a black crosshair centered on a white background. The top-left quadrant is yellow, the bottom-left is red, and the bottom-right is blue.

# SGEH

Photo by Cathy Gartley



# Segmental aplasia

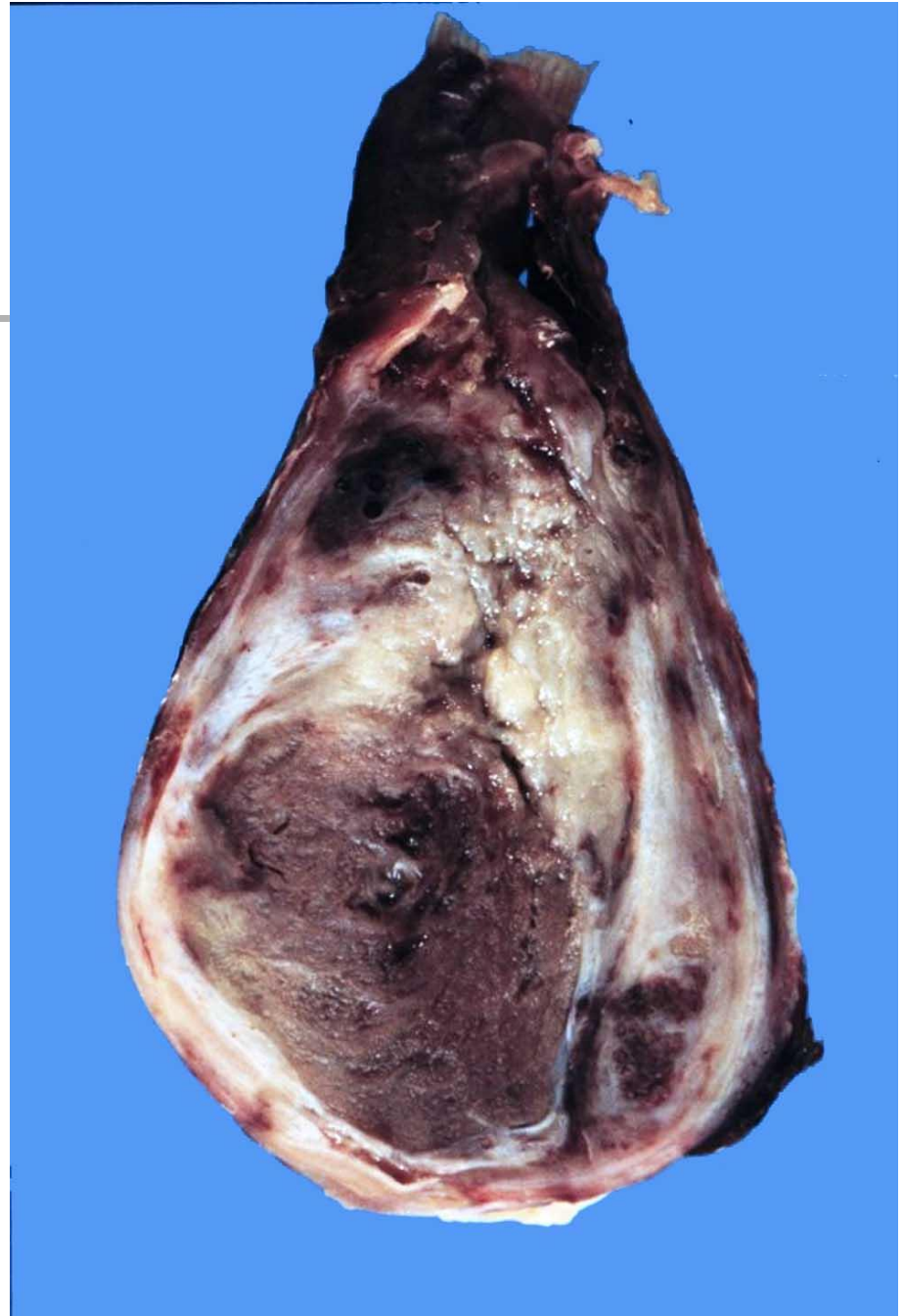




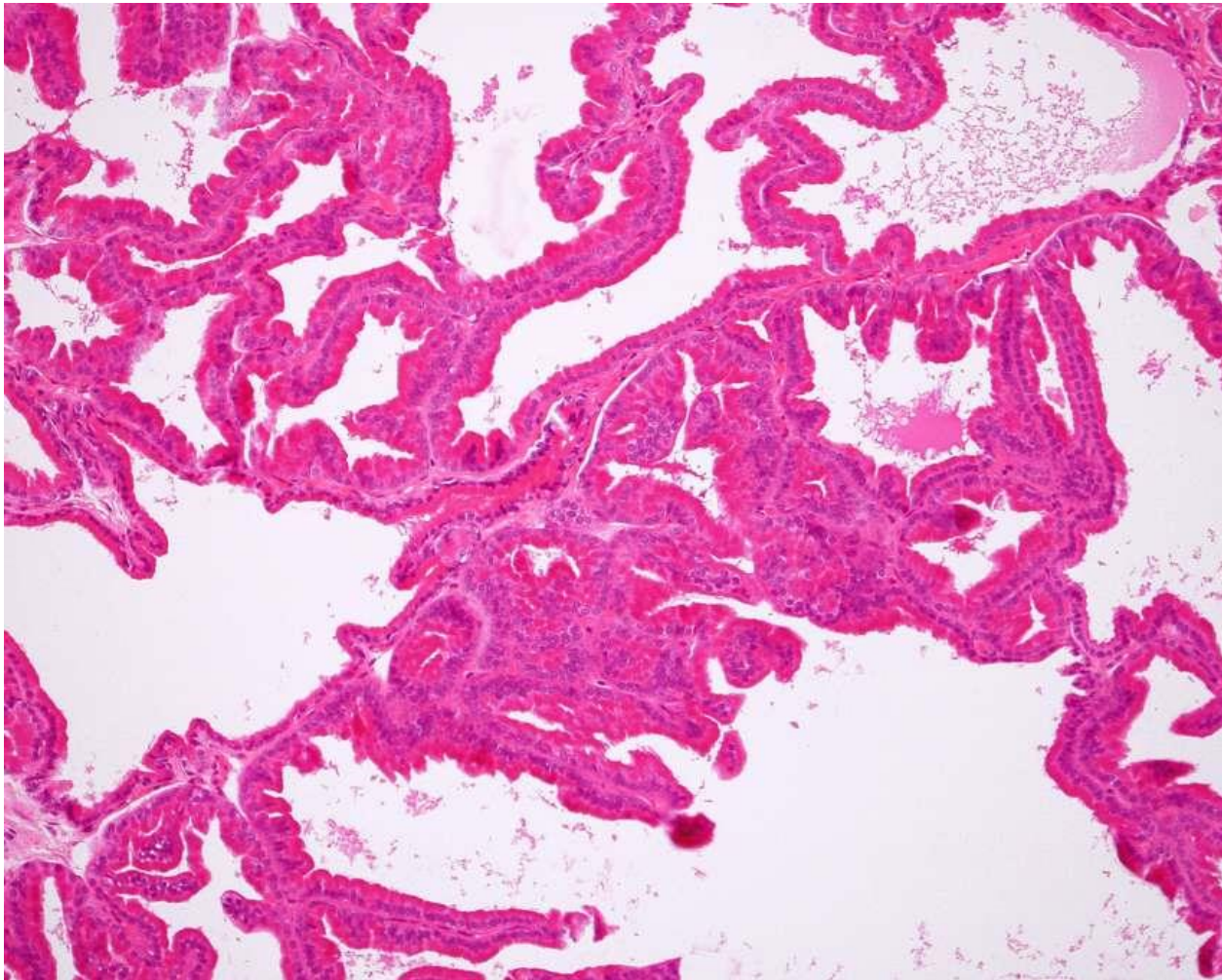


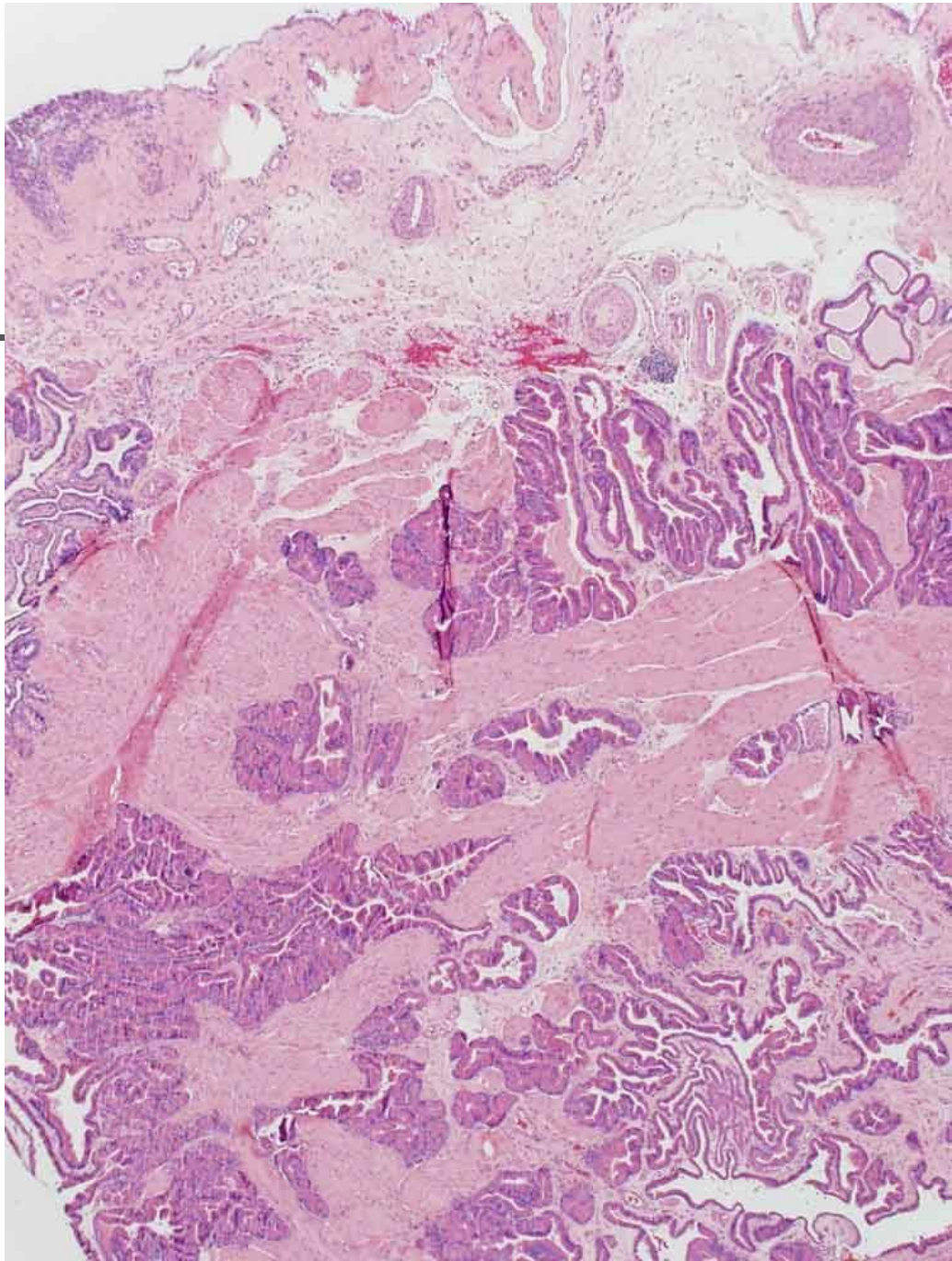

# Epididymitis

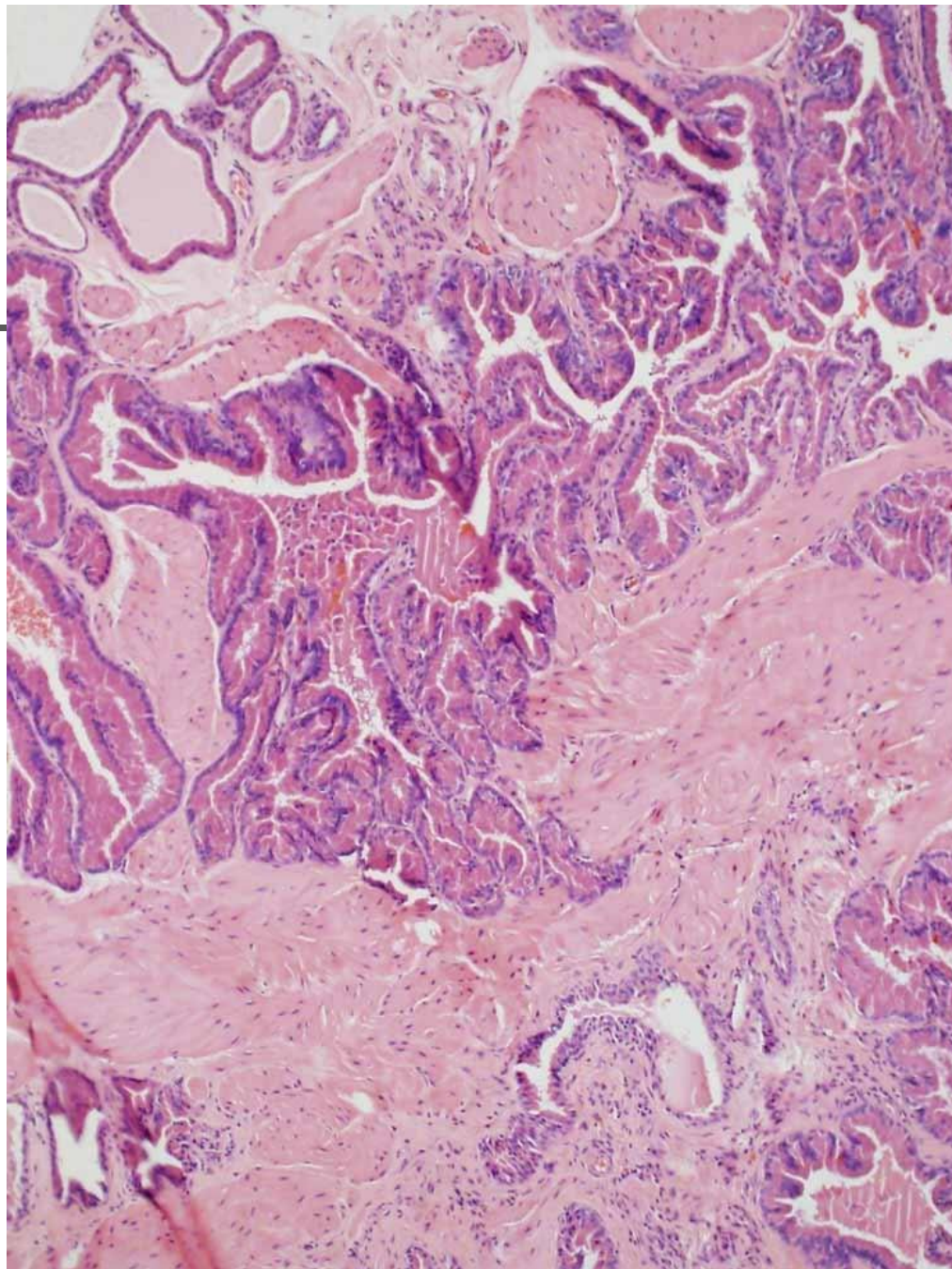

---

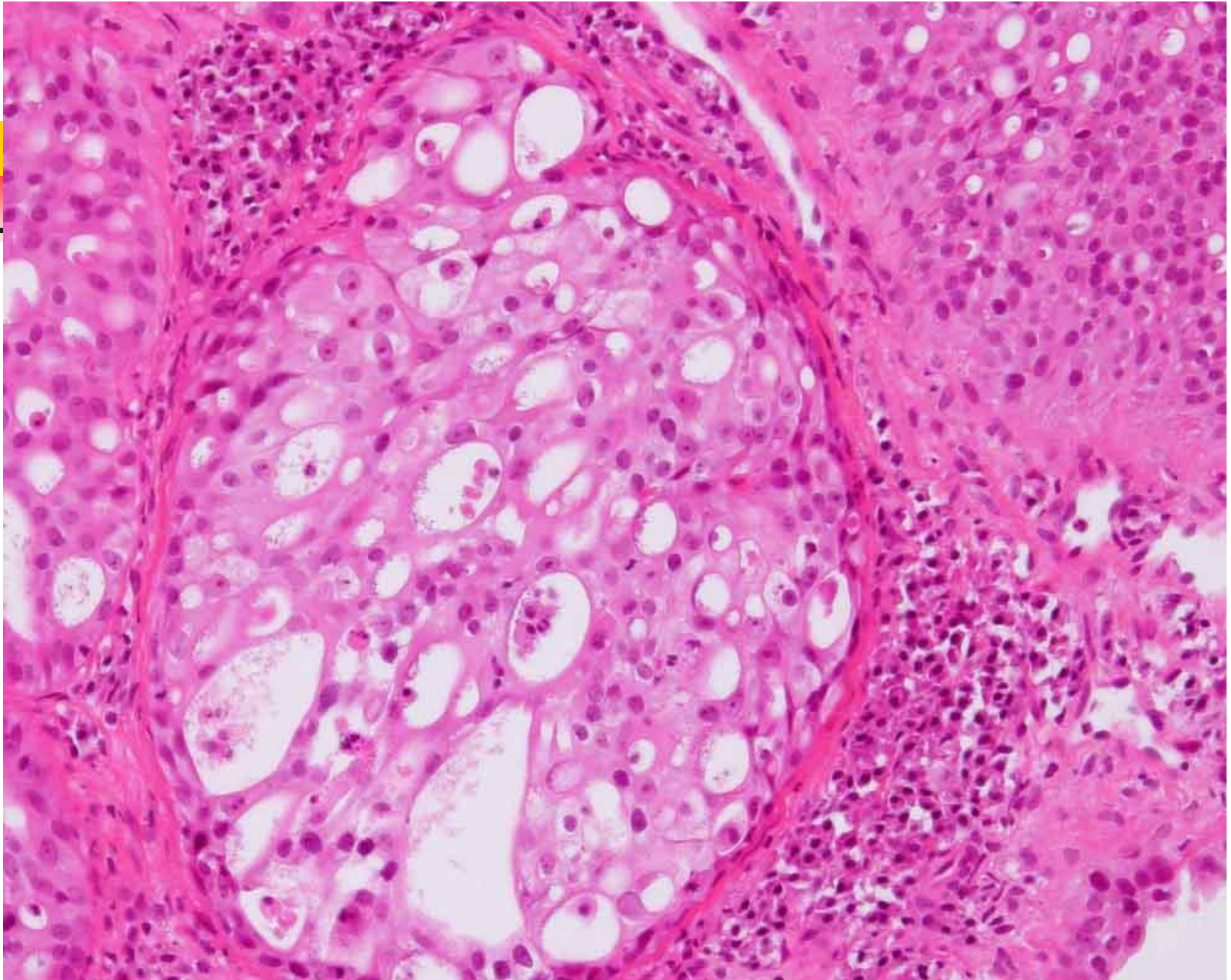


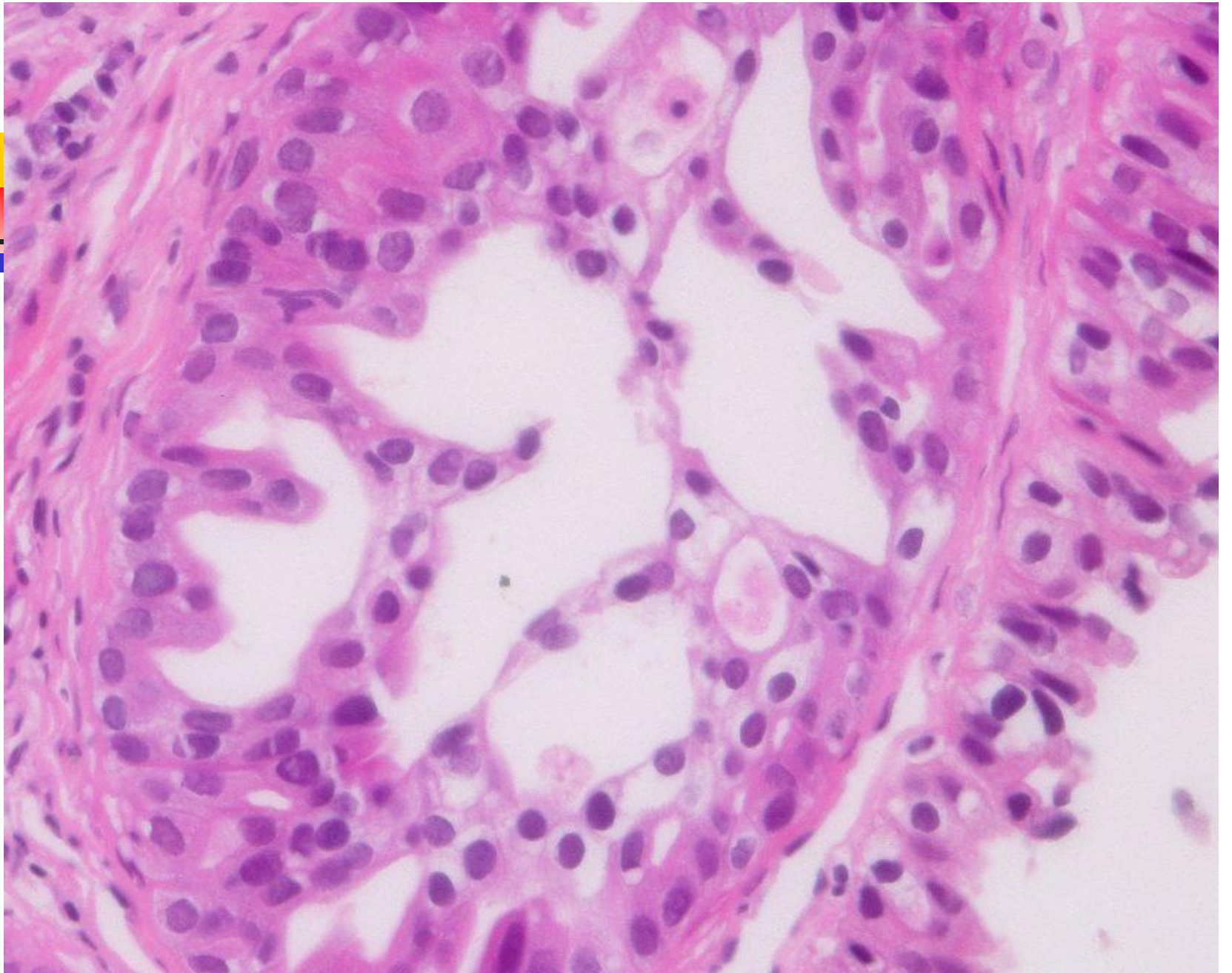
# Prostatic hyperplasia

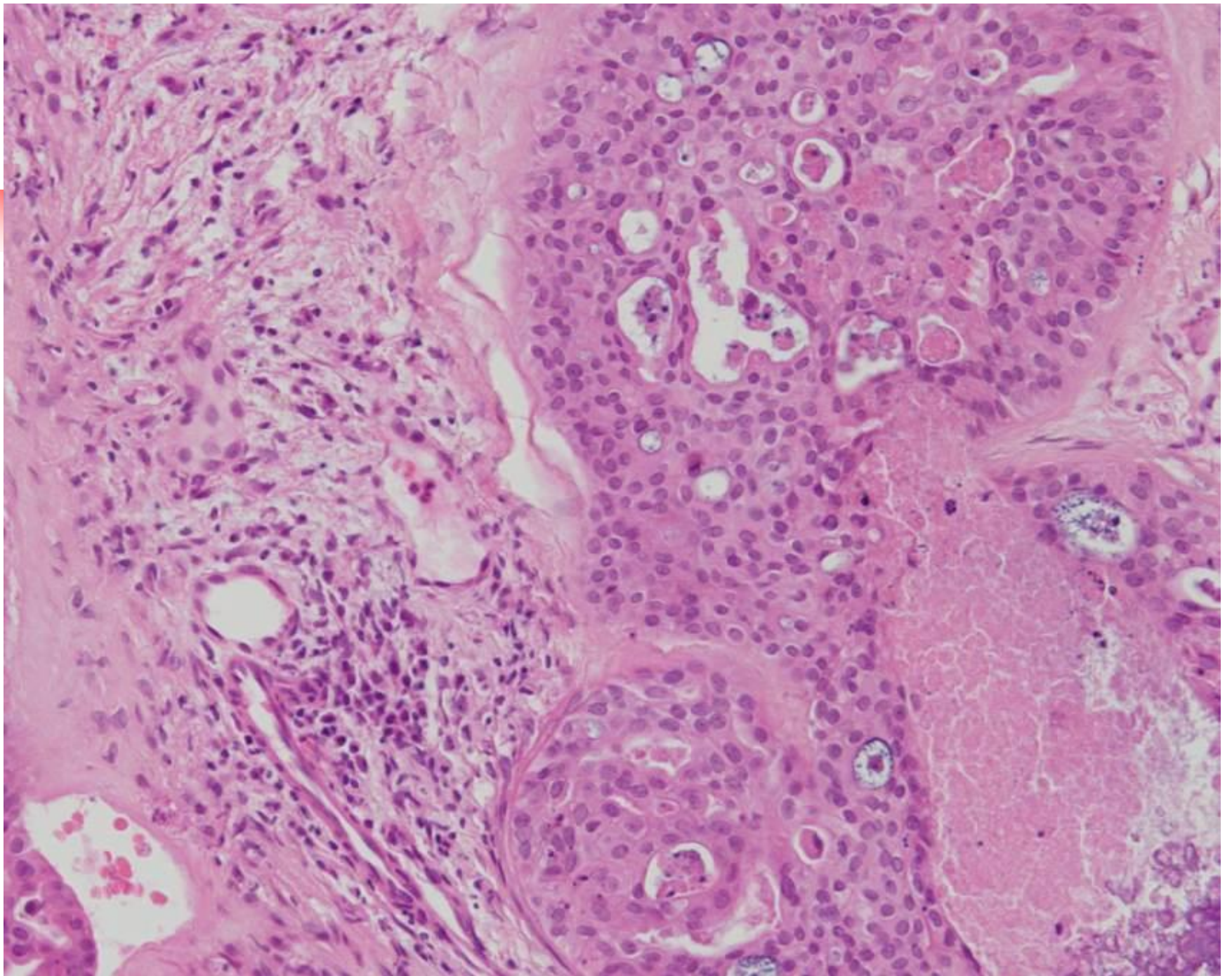














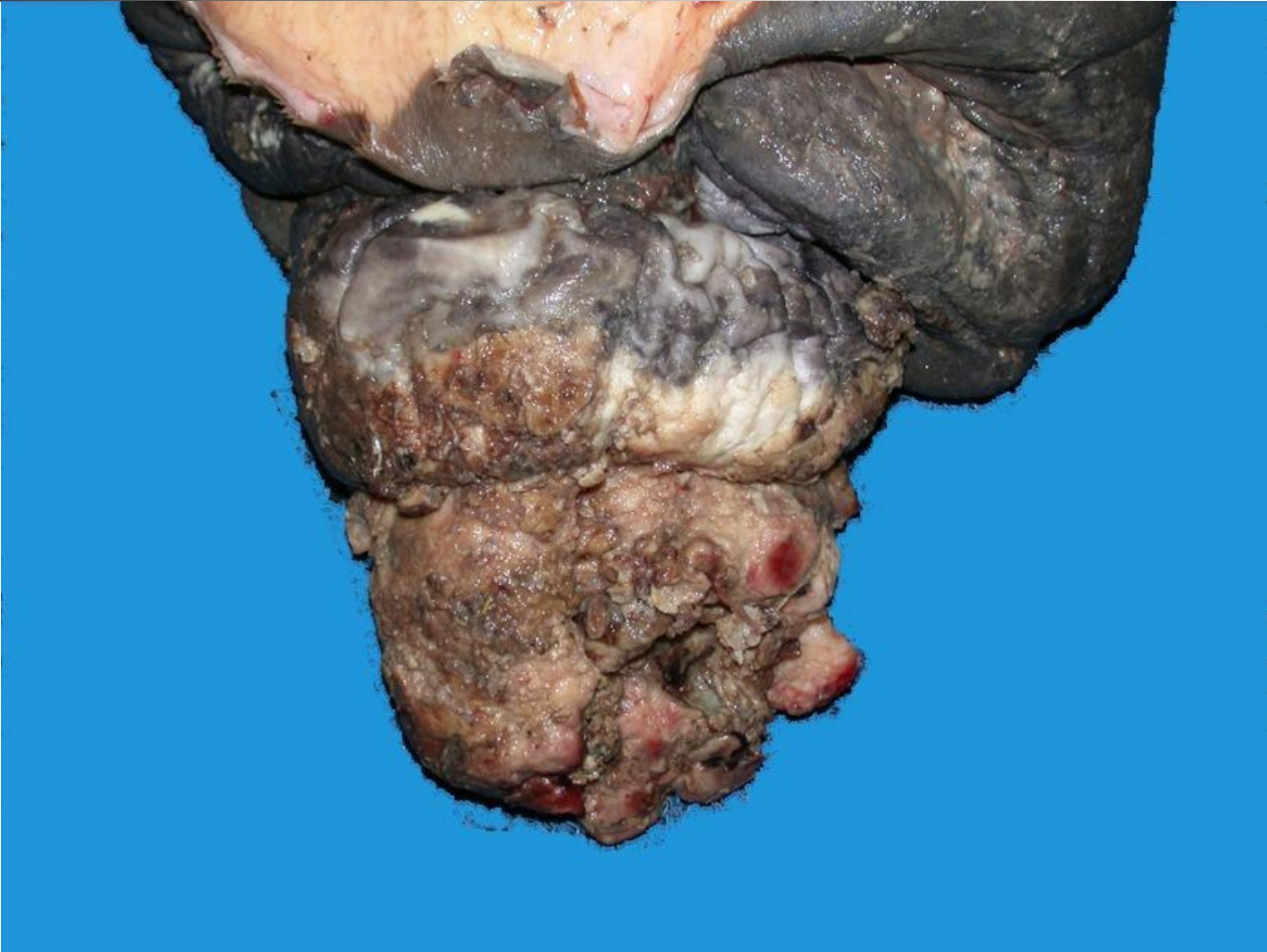
# Prostatic enlargement

---

- Neutered dog
  - Carcinoma of prostate
- Intact dog
  - Hyperplasia
  - Cysts
  - Prostatitis
  - Squamous metaplasia
  - Neoplasia



# Neoplasia - SCC





# Equine penile SCC

---

- EqPV-2 sequences found in SCC
- Similarity to human (HPV) preputial carcinoma



# Acknowledgements

---

- Dr Philip Ladds
- Dr Richard Miller
  
- Dr Don Schlafer
  
- OVC Pathobiology
  
- Animal Health Laboratory, University of Guelph
  
- YagerBest Histovet (Antech Canada)
  - Drs Yager and Best
- Histovet Surgical Pathology
  - Dr Wilcock
- Submitters and website visitors



# Sponsors

---

- Australian Animal Pathology Standards Program
  - ❖ Australian Society for Veterinary Pathology
  - ❖ Subcommittee on Animal Health Laboratory Standards
  - ❖ Animal Health Australia
- Charles Louis Davis Foundation